

Venous congestion in pedicled flaps for reconstruction of complex soft-tissue defects. Our experience

Kaloyan Tonev¹, Zhivko Dimitrov¹, Toni Stoyanov²

¹ UMHAT Medika, Rousse, Bulgaria

² Unit of Endocrine and Bariatric Surgery, Department of General Surgery, University Hospital Center Albacete, Albacete, Spain

Corresponding author: Kaloyan Tonev (ktonevmd@gmail.com)

Summary

We present three cases of reconstruction of complex skin defects using pedicled flaps (gracilis, pectoralis major, and TRAM), all of which postoperatively exhibited venous congestion, characterized by cyanosis, edema, and dark bleeding on pinprick. While cumulative comorbidities increased the overall risk, potential mechanical causes included pedicle torsion or compression, hematoma, and skin–muscle island mismatch. Empirical treatment included therapeutic anticoagulation, decompression (partial suture removal and punctures), and operative revision when indicated. We compared these measures against existing literature. Because venous congestion led to partial flap loss in our series, we propose prevention and management strategies, including meticulous planning, gentle surgical technique, and early intervention, all of which are crucial for successful flap salvage.

Key words: Gracilis, partial necrosis, pectoral flap, pedicled flap, reconstructive surgery, TRAM, venous congestion



Academic editor: Galya Stavreva

Received: 18 December 2025

Accepted: 6 January 2026

Published: 11 February 2026

Citation: Tonev K, Dimitrov Z, Stoyanov T (2026) Venous congestion in pedicled flaps for reconstruction of complex soft-tissue defects. Our experience. Journal of Biomedical and Clinical Research 19: 31–41. <https://doi.org/10.3897/jbcr.e182885>

Copyright: © Kaloyan Tonev et al.
This is an open access article distributed under terms of the Creative Commons Attribution License (Attribution 4.0 International – CC BY 4.0).

Introduction

Pedicled and free flaps are often complex reconstructive procedures and are one of the few options for treating large skin defects (Xiong et al. 2016). Pedicled flaps carry tissues such as skin, subcutaneous tissue, fascia, and muscle, with their own blood supply through an arteriovenous pedicle (O'Neill et al. 2017). They rank high in reconstructive treatment in terms of complexity and donor morbidity, yet they provide abundant tissue volume, functionality, and good aesthetic results (Cannady et al. 2014). The most common anatomical areas in which both pedicled and free flaps are used for reconstruction of skin and soft tissue defects are the head and neck, lower limb, and breast. In recent years, significant improvements in surgical techniques have reduced the incidence of surgeon-related technical errors. However, postoperative complication rates remain high (Wettstein et al. 2008; Lese et al. 2021).

Venous stasis is a leading pattern of partial necrosis and flap loss, requiring early diagnosis and targeted management. In a report on 85 reconstructions with pedicled perforator flaps, D'Arpa et al. reported venous congestion leading to partial flap loss in 6% of cases. With only one case of arterial deficiency,

venous congestion is the leading cause of flap loss, accounting for 6% of complicated cases (D'Arpa et al. 2011). The symptoms of venous insufficiency include cyanosis and congestion of the flap, slow capillary refill, and dark blood discharge from punctum points. Because tissue salvage becomes progressively less likely after only a few hours, frequent checks during the immediate postoperative period are essential (Cannady et al. 2014). When venous stasis is diagnosed, maximal effort is needed to identify a possible cause. Common causes, according to the literature, include infection-related thrombosis, pedicle twisting or squeezing, and poor surgical planning and technique (Lese et al. 2021).

There is no standard treatment for flap venous insufficiency. When mechanical compression of the pedicle is suspected due to a tight subcutaneous tunnel or an impending hematoma, prompt return to the operating room and decompression should be performed (Sanati-Mehrizy et al. 2016). In the case of a twisted pedicle, derotation of the flap and return to its original position might be the solution. Other surgical options include creating an additional venous anastomosis, if available, or cannulating a vein to allow blood outflow (Eker et al. 2003). More conservative measures include the use of low-molecular-weight heparin, medical leeches, and skin pinpricking to reduce the blood load (Mozafari et al. 2011). Mounting experience, however, shows that these measures—even when applied promptly—often do not resolve venous congestion, and these flaps are frequently partially or completely lost (Caplin et al. 2000).

Materials and methods

We performed a retrospective descriptive analysis of a three-case series involving patients who underwent reconstruction with pedicled flaps and subsequently developed venous stasis and vascular compromise in the Department of Plastic, Reconstructive and Aesthetic Surgery in UMHAT Medika, Rousse, between February 2024 and March 2025. The three cases included the application of a gracilis myocutaneous flap for a chronic wound in the left inguinal region, a pectoralis major myocutaneous flap for a massive sternal defect, and a TRAM flap for breast reconstruction.

Venous stasis was identified through clinical observation, as defined by Boissière et al. (2021), by the following signs: cyanosis, swelling, slow capillary refill time, and dark-colored blood oozing upon piercing or from the flap edges. We assessed demographic characteristics, associated comorbidities, intraoperative and postoperative factors (hematoma, infection, tunnel compression, torsion, and skin-muscle mismatch), clinical features, and the measures taken (both conservative and operative). A literature review of common causes and treatments for venous stasis was conducted, using these data for context and comparison. Finally, we analyzed potential prevention strategies and the efficacy of our complication management to propose future protocols for when this situation is encountered. Our case series contributes to the limited body of research on this specific complication.

Results

The summary of results, interventions, and treatments is shown in Table 1.

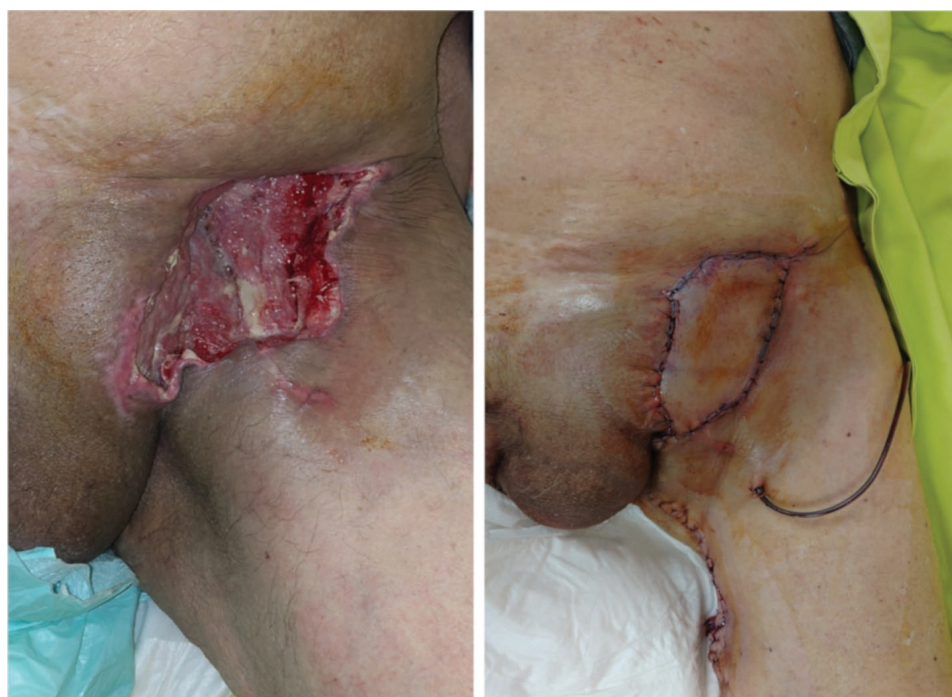The first case was that of an 83-year-old male non-smoker with a chronic wound in the left inguinal region following vascular access for a valvular

Table 1. Summary of clinical cases.

Case	Defect / Flap	Associated comorbidities	Probable causes of stasis	Treatment and interventions	Outcome
1.	inguinal wound, gracilis flap	atrial fibrillation, ischemic heart disease, arterial hypertension, chronic arterial insufficiency of the lower limbs, chronic renal failure	associated comorbidities, tunnel/peri-flap hematoma with pedicle compression, distal skin-muscle mismatch	low molecular weight heparin in therapeutic doses, evacuation of hematoma, partial suture removal	50% skin loss, no muscle loss
2.	sternal defect; pectoral flap	ischemic heart disease, arterial hypertension, chronic heart failure, diabetes mellitus.	associated comorbidities, lateral skin-muscle flap mismatch	low molecular weight heparin in therapeutic doses	30% skin and 30% muscle loss
3.	breast reconstruction; TRAM	None	possible hypoplasia of superior epigastric a./v., narrow subcutaneous tunnel with pedicle compression	low molecular weight heparin in therapeutic doses, perforation for venous drainage, suture release	15% skin and 20% adipose tissue loss

prosthesis and a subsequent postoperative hematoma. His established comorbidities included atrial fibrillation, ischemic heart disease, arterial hypertension, chronic arterial insufficiency of the lower limbs, and chronic renal failure. Due to the recent valve surgery and atrial fibrillation, the patient was receiving a high-dose low-molecular-weight heparin (LMWH). The defect was closed with a regional pedicled gracilis myocutaneous flap (Fig. 1). The pedicle was based on the ascending branch of the medial circumflex femoral artery—a branch of the profunda femoris artery—as described in the literature. A subcutaneous tunnel was created between the medial thigh and the inguinal skin defect, through which the flap was transposed.

On the third postoperative day, venous stasis was detected, which gradually progressed to involve the distal half of the flap. Examination revealed a hematoma in the adjacent subcutaneous tissues and within the subcutaneous tunnel. Furthermore, a skin-muscle mismatch was identified in the distal portion of the flap. As part of the treatment plan, the patient underwent partial suture removal and evacuation of the hematoma and was maintained on a high-dose

**Figure 1.** Clinical case 1: skin defect in the inguinal area, reconstructed with a musculocutaneous gracilis flap.

LMWH regimen. Despite these measures, venous congestion did not resolve, resulting in 50% skin-island loss while the muscle component of the flap remained vital. Following demarcation of the necrosis and serial debridement, secondary intention suturing and a split-thickness skin graft were used to close the remaining defect (Figs 2, 3). Several weeks after the skin graft operation, the patient was admitted for exacerbated chronic renal failure and died a few days later.

The second clinical case involves a 67-year-old non-smoker presenting with a chronic sternal wound following cardiac surgery and subsequent wound supuration. The infection involved the sternum, necessitating its total removal. Significant comorbidities in this case included coronary artery disease, arterial hypertension, chronic heart failure, and diabetes mellitus. Furthermore, the patient was severely debilitated by chronic sternal inflammation. The thoracic defect was reconstructed using a pectoralis major myocutaneous flap based on the pectoral branch of the thoracoacromial artery, combined with local random-pattern flaps and a titanium implant for thoracic stabilization (Fig. 4). Notably, during preoperative planning, the team considered a medially based pectoralis major flap with a skin graft—a common approach for such scenarios. However, this was not possible in our case because both internal thoracic arteries had been destroyed during the sternal debridement and removal.

In our case, venous stasis of the flap was identified within the first postoperative week. LMWH was administered, skin tension was alleviated through partial suture removal, and skin pricking was performed to facilitate blood outflow. Despite these interventions, the congestion gradually progressed to 30% skin and muscle necrosis. Following serial debridement and removal of the titani-

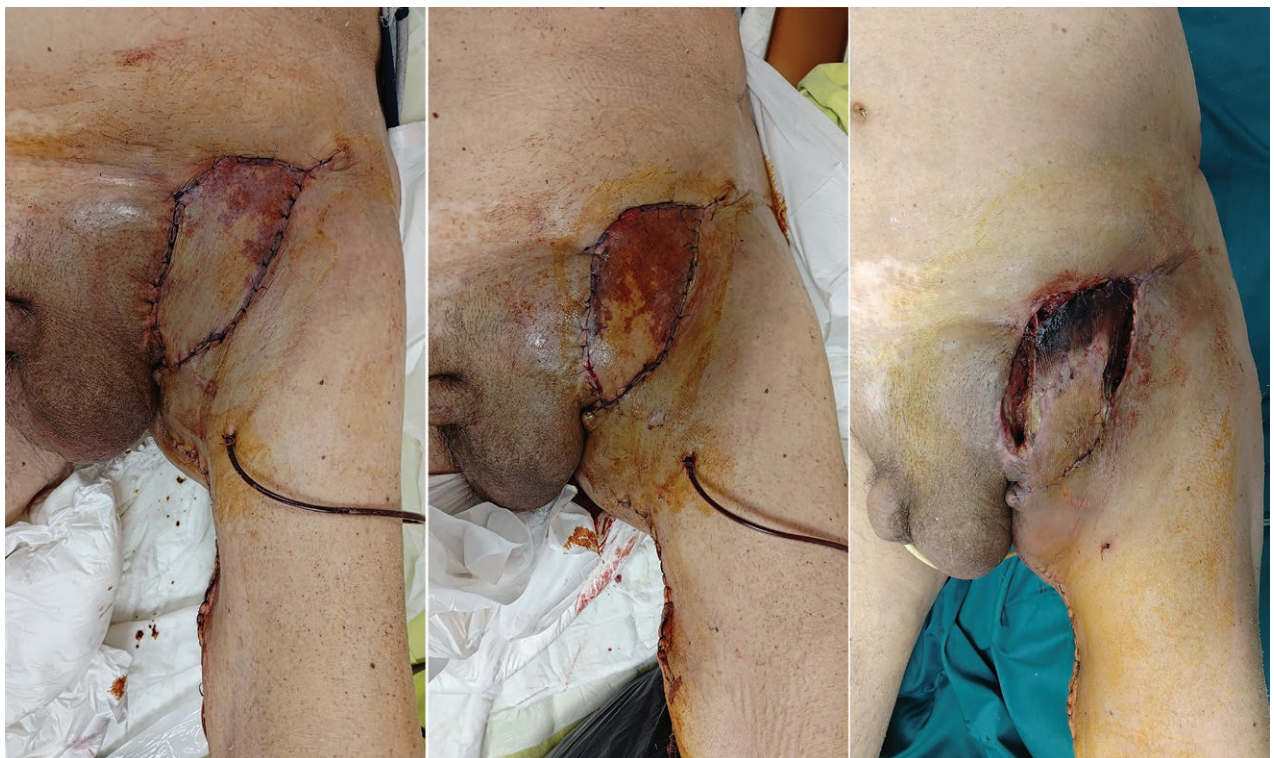

Figure 2. Clinical case 1 – continued.

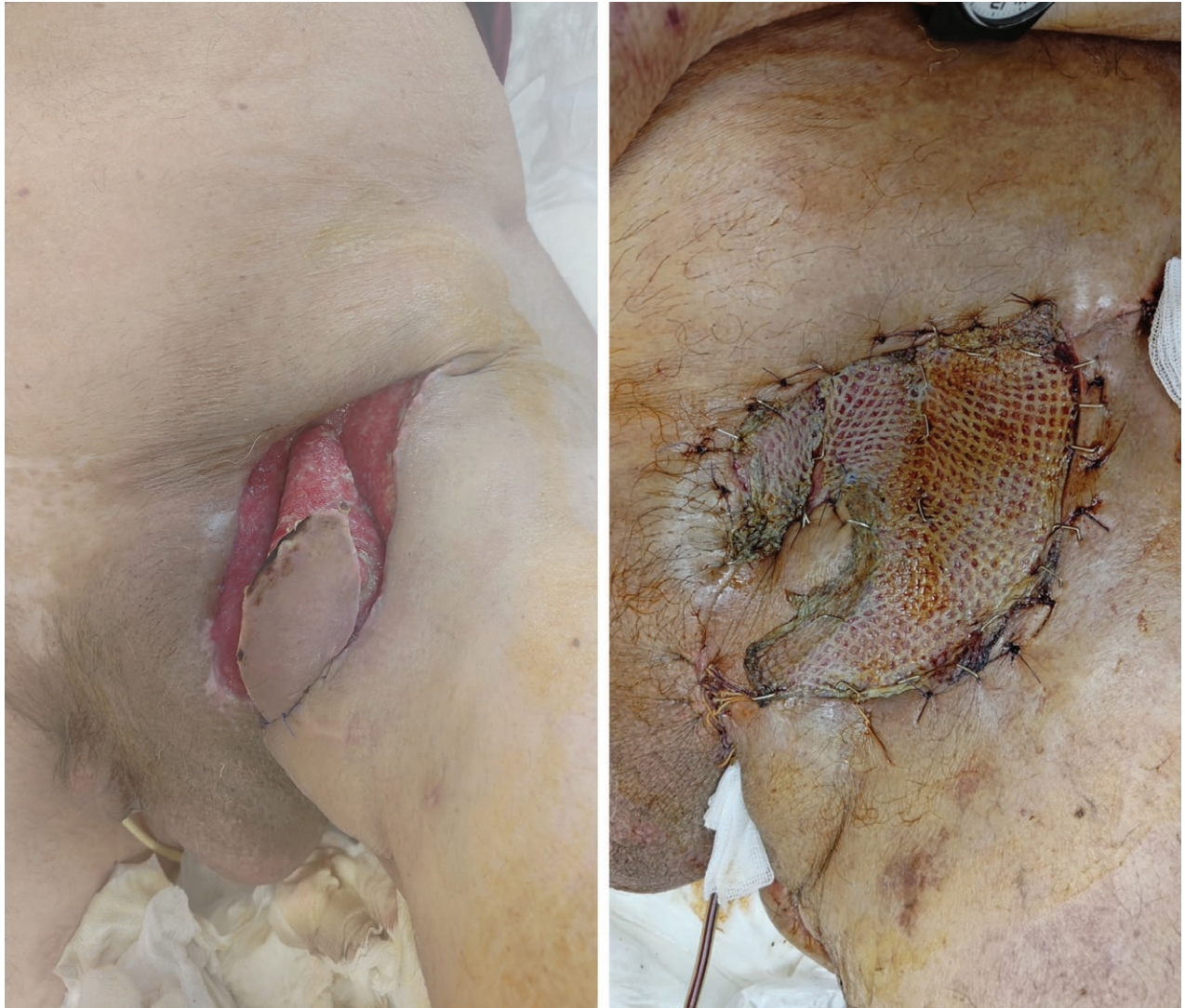


Figure 3. Clinical case 1 – continued.

um implant, the remaining defect was closed with a split-thickness skin graft (Fig. 5). The patient was lost to follow-up after discharge due to remote residence and impaired mobility.

The final case is that of a female patient who underwent a right mastectomy for breast cancer, with no comorbidities or history of smoking. The breast was reconstructed using a pedicled transverse rectus abdominis myocutaneous (TRAM) flap from the anterior abdominal wall. On the third postoperative day, venous stasis was detected. Despite interventions including LMWH and needle scarification, 15% of the skin and 20% of the adipose tissue necrosed, demarcated within several weeks (Fig. 6).

Over the following month, debridement and secondary closure were performed. Because the aesthetic result was unsatisfactory, staged lipofilling of the breast, reconstruction of the nipple-areola complex, and symmetrization of the contralateral breast via reduction mammoplasty were conducted in the following year (Fig. 7). The final result was satisfying for the patient. While the aesthetics could have been better, it was a significant improvement over the initial state.

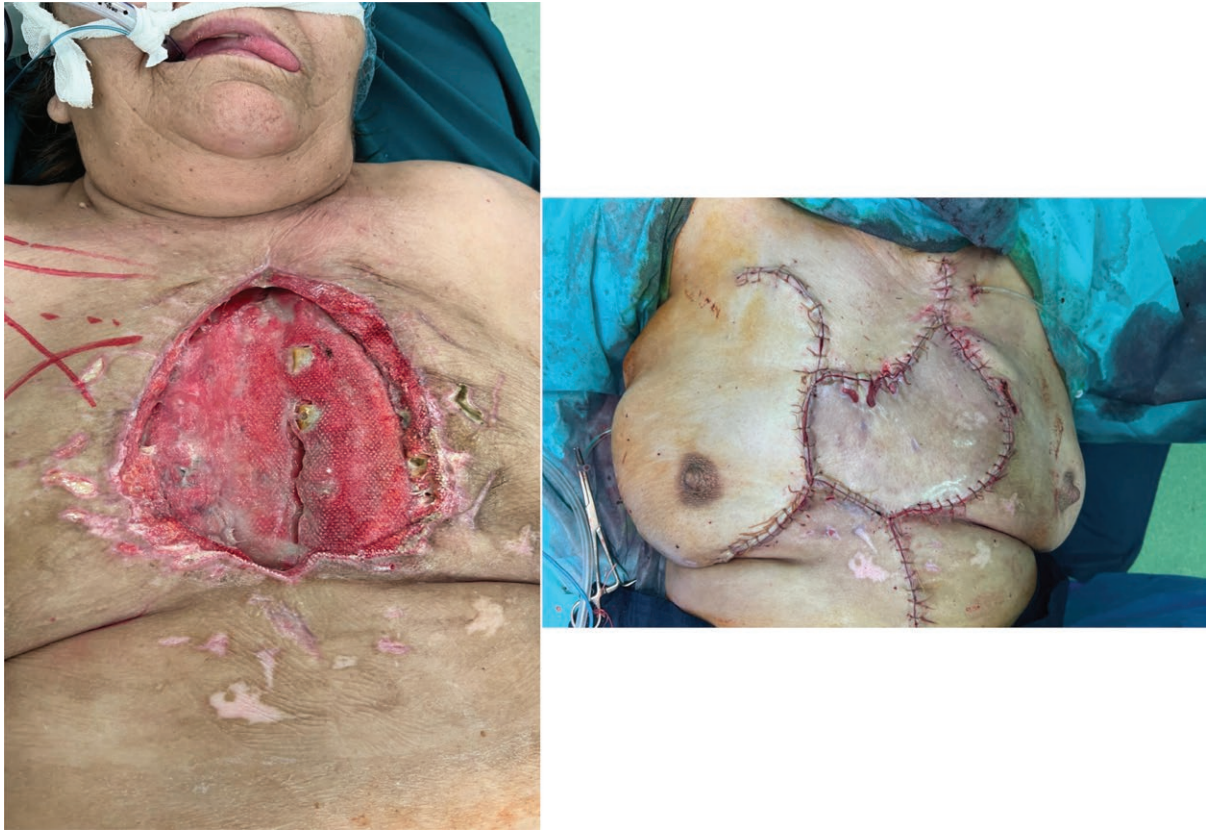

Figure 4. Clinical case 2: defect in the sternal region, reconstructed with a pectoral and local flap.

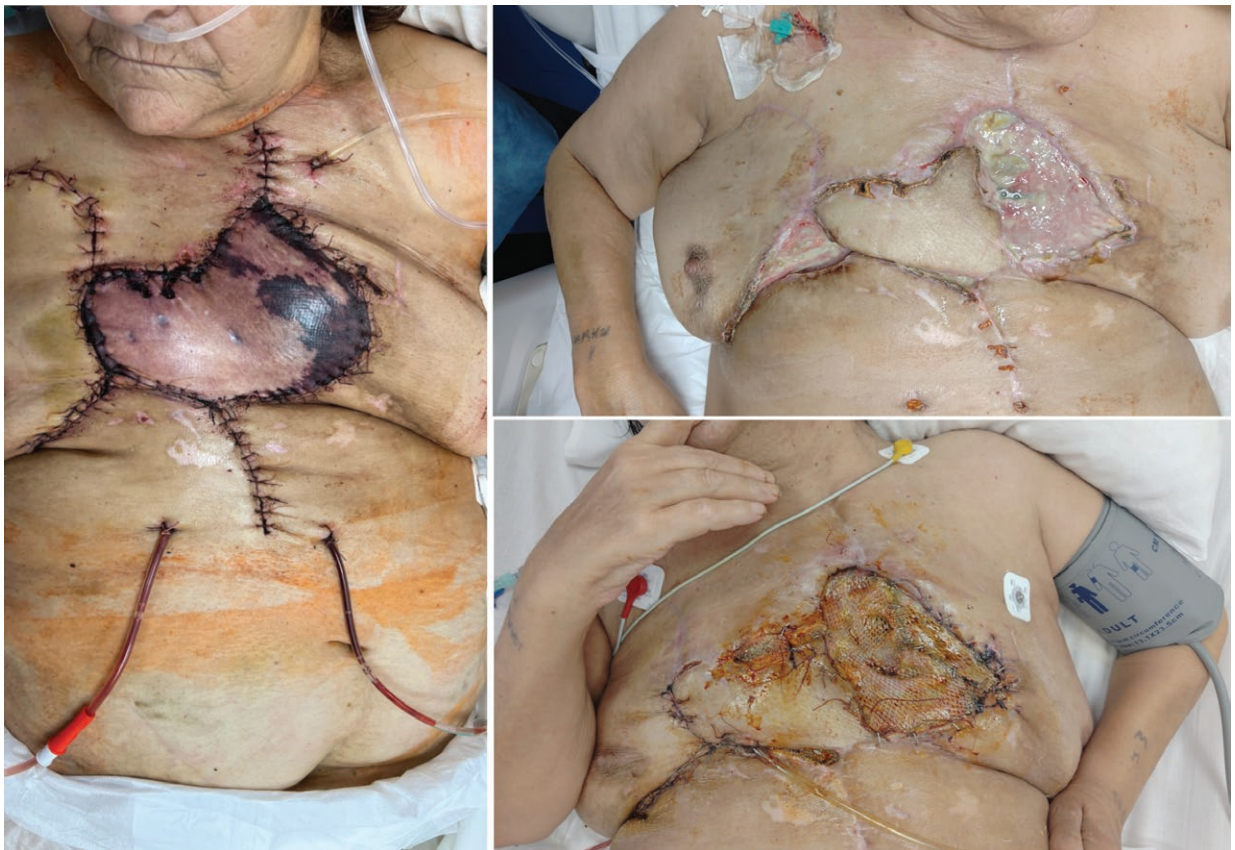

Figure 5. Clinical case 2: continued.

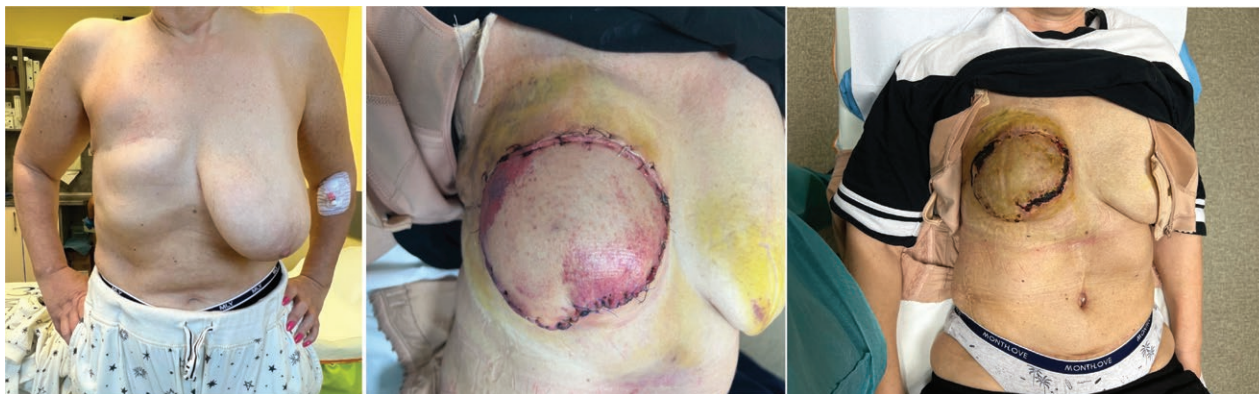

Figure 6. Clinical case 3: venous stasis and necrosis after breast reconstruction with a TRAM flap.

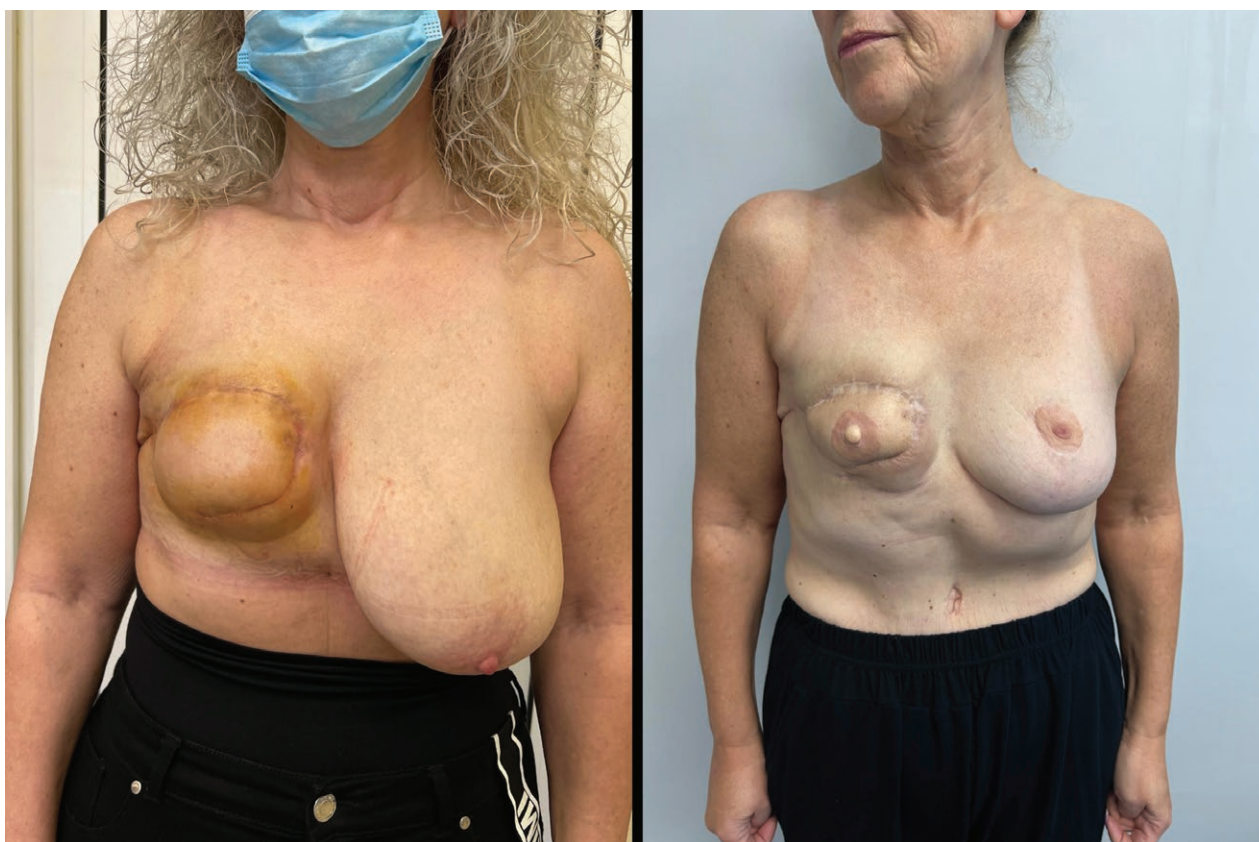


Figure 7. Clinical case 3 – continued.

Discussion

Clinical signs of venous stasis in the presented cases included cyanosis, increasing edema, and dark blood oozing upon puncture, as described in the literature (Boissière et al. 2021). Potential mechanical factors were identified in all cases, including hematoma, tunnel compression, pedicle torsion, and skin-muscle mismatch. Therefore, thorough preoperative planning and meticulous surgical technique are critical for preventing such complications.

Patients with multiple comorbidities generally demonstrate a higher risk of vascular complications (Boissière et al. 2021). In two out of the three cases in our series, patients had significant comorbidities that contributed substan-

tially to postoperative complications. Diabetes mellitus, arterial hypertension, and chronic heart failure are established risk factors for vascular compromise (Lese et al. 2021). However, none of the patients were smokers, highlighting the complexity of factors influencing reconstructive outcomes. Therefore, a rigorous preoperative evaluation of risks and benefits should be performed in every case to identify patients who may be unfit for complex reconstruction.

In the third case, there was a notable lack of significant comorbidities. Apart from potential technical errors, a possible cause of postoperative venous congestion was insufficient blood flow from the superior epigastric vessels. A study by Tuominen et al. demonstrated a significant drop in skin blood flow and oxygen pressure in TRAM flaps following the ligation of the inferior epigastric vessels (Tuominen et al. 1992). In their series of 15 patients, eight experienced varying degrees of skin necrosis due to insufficient perfusion. Codner et al. proposed ligating the superficial and deep inferior epigastric vessels 2 weeks prior to surgery in high-risk patients. They reported a 4.3% incidence of fat necrosis in a series of 23 patients and a significant increase in blood pressure within the muscle perforators compared to the control group. Performing this “delay” procedure in our TRAM reconstruction case might have prevented the subsequent venous insufficiency (Codner et al. 1995). Another valuable preoperative tool is the evaluation of the epigastric vascular system with contrast-enhanced MRI or CT angiography, which can identify vascular malformations that might preclude TRAM flap reconstruction.

Conservative measures, such as therapeutic anticoagulation, decompression through suture removal, and skin punctures, were applied immediately upon the detection of venous compromise in our cases. Some authors have reported utilizing medical leeches (hirudotherapy) for venous unloading in such cases, with flap salvage success rates around 70% (Boissière et al. 2021). However, hirudotherapy is associated with complications such as anemia and secondary infection, and it was unavailable in our facility. The local and systemic application of LMWH is an alternative, and we used it in our cases. It is often considered a safer alternative to leech therapy while aiming for similar decompression. Complications associated with this treatment include hematoma formation and anemia. Pérez et al. proposed a protocol for LMWH application in flaps with venous congestion involving subcutaneous injections in the congested area. They reported that in their series of 15 patients, applying this protocol resulted in seven fully and eight partially salvaged flaps. However, they also reported a median of five units of blood transfusion per patient, indicating significant blood loss (Pérez et al. 2014). In our cases, LMWH administration did not prevent the ensuing skin necrosis. Furthermore, based on our experience, suture removal and skin pricking do not result in significant relief of venous congestion.

In the presence of a mechanical cause, surgical revision with derotation, decompression, hematoma evacuation, and, if feasible, additional venous anastomosis or temporary venous drainage is recommended. In our series, only one patient had a significant subcutaneous hematoma. It was promptly evacuated, which, combined with LMWH, led to 50% skin island salvage. Some authors advocate cannulating a superficial flap vein for blood decompression and report high flap salvage rates with this method (Caplin et al. 2000; Mozafari et al. 2011). However, cannulation is best performed during the initial operation, underscoring the importance of preoperative planning. Another reported treatment for venous congestion is negative-pressure wound therapy (NPWT), and

although large-scale studies are lacking, some small-scale ones report high rates of successful salvage (Vaienti et al. 2013). Conversely, other authors note drawbacks to using NPWT on compromised flaps, including increased mechanical pressure, blood loss, and the inability to monitor the flap visually (Morgan et al. 2006).

Given the small size of our case series, statistically significant conclusions cannot be drawn. The complexity of these cases often confounded the precise etiology of the complications, and therapy was selected empirically. A review of the literature highlights a lack of large-series research on venous congestion, often rendering proposed algorithms anecdotal.

Conclusion

Venous stasis in pedicled flaps remains a challenging postoperative complication that jeopardizes a successful reconstructive outcome. The presented cases were used as a basis for reviewing possible prevention and treatment strategies. Primary prevention methods include meticulous preoperative planning, precise surgical technique, adequate hemostasis, and the maintenance of angiosomal integrity without tension. When stasis occurs, rapid recognition and a systematic, algorithmic management approach, ranging from conservative unloading to surgical revision, are essential to maximize the chances of flap preservation.

Additional information

Conflict of interest

The authors have declared that no competing interests exist.

Ethical statements

The authors declared that no clinical trials were used in the present study.

The institutional ethical committee approved the study and its publication.

The authors declared that no experiments on humans or human tissues were performed for the present study.

The appropriate patient consent statements were taken. Informed consent from the humans, donors or donors' representatives: UMHAT Medika, Rousse, Bulgaria.

The authors declared that no experiments on animals were performed for the present study.

The authors declared that no commercially available immortalised human and animal cell lines were used in the present study.

Use of AI

No use of AI was reported.

Funding

No funding was reported.

Author contributions

Resources: ZD. Writing – original draft: KT. Writing – review and editing: TIS.

Author ORCIDs

Kaloyan Tonev  <https://orcid.org/0000-0001-6684-2073>

Zhivko Dimitrov  <https://orcid.org/0009-0000-6191-9211>

Toni Stoyanov  <https://orcid.org/0000-0002-8772-7848>

Data availability

All of the data that support the findings of this study are available in the main text.

References

- Boissière F, Gandolfi S, Riot S, Kerfant N, Jenzeri A, Hendriks S, Grolleau J-L, Khechimi M, Herlin C, Chaput B (2021) Flap venous congestion and salvage techniques: A systematic literature review. *Plastic and reconstructive surgery– Global Open* 9: e3327. <https://doi.org/10.1097/GOX.0000000000003327>
- Cannady SB, Rosenthal EL, Knott PD, Fritz M, Wax MK (2014) Free tissue transfer for head and neck reconstruction. *JAMA Facial Plastic Surgery* 16: 367–373. <https://doi.org/10.1001/jamafacial.2014.323>
- Caplin DA, Nathan CR, Couper SG (2000) Salvage of TRAM flaps with compromised venous outflow. *Plastic and Reconstructive Surgery* 106: 400–401. <https://doi.org/10.1097/00006534-200008000-00023>
- Codner MA, Bostwick J, Nahai F, Bried JT, Eaves FF (1995) TRAM flap vascular delay for high-risk breast reconstruction. *Plastic and Reconstructive Surgery* 96: 1615–1622. <https://doi.org/10.1097/00006534-199512000-00015>
- D’Arpa S, Cordova A, Pignatti M, Moschella F (2011) Freestyle pedicled perforator flaps: Safety, prevention of complications, and management based on 85 consecutive cases. *Plastic and Reconstructive Surgery* 128: 892–906. <https://doi.org/10.1097/PRS.0b013e3182268c83>
- Eker G, Akan AM, Aydoğdu E, Aköz T (2003) Salvage of neurocutaneous flaps with venous congestion using intravenous cannula. *Plastic and Reconstructive Surgery* 112: 1191–1192. <https://doi.org/10.1097/01.PRS.0000077238.46535.96>
- Lese I, Biedermann R, Constantinescu M, Grobbelaar AO, Olariu R (2021) Predicting risk factors that lead to free flap failure and vascular compromise: A single unit experience with 565 free tissue transfers. *Journal of Plastic, Reconstructive & Aesthetic Surgery* 74: 512–522. <https://doi.org/10.1016/j.bjps.2020.08.126>
- Morgan K, Brantigan CO, Field CJ, Paden M (2006) Reverse sural artery flap for the reconstruction of chronic lower extremity wounds in high-risk patients. *The Journal of Foot and Ankle Surgery* 45: 417–423. <https://doi.org/10.1053/j.jfas.2006.09.016>
- Mozafari N, Ghazisaidi MR, Hosseini SN, Abdolzadeh M (2011) Comparisons of medicinal leech therapy with venous catheterization in the treatment of venous congestion of the sural flap. *Microsurgery* 31: 36–40. <https://doi.org/10.1002/micr.20827>
- O’Neill AC, Haykal S, Bagher S, Zhong T, Hofer SOP (2017) Erratum to “Predictors and consequences of intraoperative microvascular problems in autologous breast reconstruction”. *Journal of Plastic, Reconstructive & Aesthetic Surgery* 70: e295. <https://doi.org/10.1016/j.bjps.2016.12.002>
- Pérez M, Sancho J, Ferrer C, García O, Barret JP (2014) Management of flap venous congestion: The role of heparin local subcutaneous injection. *Journal of Plastic, Reconstructive & Aesthetic Surgery* 67: 48–55. <https://doi.org/10.1016/j.bjps.2013.09.003>

- Sanati-Mehrizy P, Massenbourg BB, Rozehnal JM, Ingargiola MJ, Hernandez Rosa J, Taub PJ (2016) Risk factors leading to free flap failure. *Journal of Craniofacial Surgery* 27: 1956–1964. <https://doi.org/10.1097/SCS.0000000000003026>
- Tuominen HP, Asko-Seljavaara S, Svartling NE, Härmä MA (1992) Cutaneous blood flow in the TRAM flap. *British Journal of Plastic Surgery* 45: 261–269. [https://doi.org/10.1016/0007-1226\(92\)90049-4](https://doi.org/10.1016/0007-1226(92)90049-4)
- Vaianti L, Gazzola R, Benanti E, Leone F, Marchesi A, Parodi PC, Riccio M (2013) Failure by congestion of pedicled and free flaps for reconstruction of lower limbs after trauma: the role of negative-pressure wound therapy. *Journal of orthopaedics and traumatology* 14: 213–217. <https://doi.org/10.1007/s10195-013-0236-0>
- Wettstein R, Schürch R, Banic A, Erni D, Harder Y (2008) Review of 197 consecutive free flap reconstructions in the lower extremity. *Journal of Plastic, Reconstructive & Aesthetic Surgery* 61: 772–776. <https://doi.org/10.1016/j.bjps.2007.11.037>
- Xiong L, Gazyakan E, Kremer T, Hernekamp FJ, Harhaus L, Saint-Cyr M, Kneser U, Hirche C (2016) Free flaps for reconstruction of soft tissue defects in lower extremity: A meta-analysis on microsurgical outcome and safety. *Microsurgery* 36: 511–524. <https://doi.org/10.1002/micr.30020>