

**QUANTIFICATION AND DESCRIPTION OF GUT-ASSOCIATED LYMPHOID TISSUE IN, SHABBOUT, *ARABIBARBUS GRYPUS* (ACTINOPTERYGII: CYPRINIFORMES: CYPRINIDAE), IN WARM AND COLD SEASON**

Amneh MORADKHANI<sup>1</sup>, Rahim ABDI<sup>\*1</sup>, Mohammad A. SALARI-ALI ABADI<sup>1</sup>, Seyed M.B. NABAVI<sup>1</sup>, and Zahra BASIR<sup>2</sup>

<sup>1</sup> *Department of Marine Biology, Faculty of Marine Science, Khorramshahr University of Marine Science and Technology, Khorramshahr, Iran*

<sup>2</sup> *Department of Basic Science, Faculty of Veterinary Medicine, Shahid Chamran University of Ahvaz, Ahvaz, Iran*

Moradkhani A., Abdi R., Salari-Ali Abadi M.A., Nabavi S.M.B., Basir Z. 2020. Quantification and description of gut-associated lymphoid tissue in, shabbout, *Arabibarbus grypus* (Actinopterygii: Cypriniformes: Cyprinidae), in warm and cold season. Acta Ichthyol. Piscat. 50 (4): 423–432.

**Background.** Gut-associated lymphoid tissue (GALT), is a primary lymphoid tissue and a part of the mucosal lymphoid system. Depending on the location, it present as aggregations of lymphoid cells. There are several reports of structural differences in the lymphoid tissue attached to the gastrointestinal tract between different species of fish, as well as different areas of the gastrointestinal tract of a fish in the cold and warm seasons. Identifying and expressing these differences in terms of tissue structure, in addition to diagnosing aquatic diseases, is also of particular importance for vaccination and disease control.

**Material and methods.** For this purpose, after collecting the desired samples routine histological procedure was performed and 4–6 µm sections were obtained and were subsequently stained with hematoxylin-eosin, periodic acid–Schiff, and TUNEL immunohistochemical staining method.

**Results.** The results showed that four main layers, i.e., tunica mucosa, tunica submucosa, tunica muscularis, and tunica serosa, were observed in the wall of the gut of *Arabibarbus grypus* (Heckel, 1843), as had been observed in other teleosts. GALT was seen in two different shapes in two areas. The former consisted of intra-epithelial scattered cells, which were arranged in the pillar structures and extended to the upper regions of the epithelium, but were more concentrated in the mid bases. The latter was found in lamina propria and submucosa regions. In the lamina propria, they had a strip-shaped arrangement and were placed in several rows below the base membrane, but in the submucosa, they were scattered and less densely packed. Micrometric results showed that not only the distribution of the lymphocytic cells in the intestine of both male and female specimens varied in different areas but also in some areas, the difference was statistically significant in both cold and warm seasons ( $P < 0.05$ ). TUNEL immunohistochemical staining revealed that the number of apoptotic cells in both sexes was more in the anterior part of the intestinal bulb and in the posterior part of the proper intestine in the warm season compared to the cold season.

**Conclusion.** Based on a recent study on gut-associated lymphoid tissue in *A. grypus* in two warm and cold seasons revealed that mucosal immunity is more active in the cold season than in the warm season.

**Keywords:** gut-associated lymphoid tissue, GALT, immunohistochemistry, *Arabibarbus grypus*, cold season, warm season

## INTRODUCTION

*Arabibarbus grypus* (Heckel, 1843) of the family Cyprinidae is one of the most valuable fish in the world due to its favorable growth and high value for meat quality. This fish feeds on a variety of plant and non-plant substances (Duman and Özpölat 2015). When it gets bigger, it becomes a carnivore. Under different environmental conditions, *A. grypus* can have different biological characteristics, including growth, fertility,

nutrition, and distribution parameters. The intestine is one of the components of the digestive tract in aquatic animals and is responsible for the absorption of food particles into the blood (Abol-Munafi et al. 2006). In teleosts, it consists of tunica mucosa, a selectively permeable membrane, tunica submucosa, which is properly composed of connective tissue and supports the mucosa, muscularis layer, and serosa (Çınar and Şenol 2006, Canan et al. 2012). Gut-associated lymphoid tissue

\* Correspondence: Dr Rahim Abdi, Khorramshahr, IRAN, P.O. Box: 669, Department of Marine Biology, Faculty of Marine Science, Khorramshahr University of Marine Science and Technology, phone:+9853533321, e-mail: (RA) [abdir@kmsu.ac.ir](mailto:abdir@kmsu.ac.ir), (AM) [amneh.mor@yahoo.com](mailto:amneh.mor@yahoo.com), (MASA) [salari1346@yahoo.com](mailto:salari1346@yahoo.com), (SMBN) [nabavismb@yahoo.com](mailto:nabavismb@yahoo.com), (ZB) [z.basir@scu.ac.ir](mailto:z.basir@scu.ac.ir).

(GALT) is a component of the primary lymphoid tissues and a part of the mucosal lymphatic system (Venkatesh et al. 2014). This tissue is the first defense of the body against the swallowed pathogenic agents. It consists of three proper lymphoid regions, namely Peyer's patches, lamina propria, and epithelial lymphoid tissue (Giffard-Mena et al. 2006, Hernandez et al. 2009). Researchers believe that fish are able to produce specific IgM immunoglobulin and have both special latency and immediate sensitivity. Both lymphocytes B and T are seen in fish (Krogdahl and Bakke-McKellep 2005). The presence of lamina propria and intraepithelial lymphoid tissue has been documented in the gut mucosa of teleosts. There are only a few reports about the existence of complex lymphoid tissue as Peyer's patches (Dai et al. 2007). On the other hand, a number of researchers have shown that the lymphoid tissue of the gut has different nature in different regions and is affected by changes in water temperature (Gisbert et al. 2004). Most of these researchers have reported that some fish have more immune activity in the cold season (Alcorn et al. 2002). The fish immune system has been widely studied in recent years, but less attention has been paid to their local immunity in body parts, such as genital organs, skin, and digestive tract. Oral vaccination in fish is highly beneficial because the intestine initiates and regulates proper immune responses to oral vaccines (Fournier-Betz et al. 2000). Since there is quantitative information on lymphoid tissue structure in different parts of the intestine of *A. grypus*, the presently reported study was conducted to identify this topic using microscopic examination by general histology and TUNEL immunohistochemical staining method.

## MATERIALS AND METHODS

**Sampling collection and processing.** In this study, all experiments on animals were carried out in accordance with a protocol approved by the Khorramshahr University of Marine Science and Technology Animal Ethics Committee (Approval No. 97-400-04). For the warm season, in August 2016, ten mature males of *Arabibarbus grypus* with a total length of  $46.8 \pm 1.46$  cm (mean  $\pm$  standard error of the mean, SE; thereafter) and weight of  $1425 \pm 150.97$  g and ten mature female of *A. grypus* with a total length of  $48.40 \pm 1.57$  cm and weight of  $1570.33 \pm 156.53$  g were collected. Additionally, for the cold season specimens, in January 2017, ten male mature *A. grypus* with a total length of  $44.40 \pm 1.21$  cm (mean length  $\pm$  SEM) and weight of  $1260 \pm 96.70$  g and ten female mature *A. grypus* with a total length of  $45.10 \pm 2.48$  cm and weight

of  $1560 \pm 275.57$  g were caught. In the presently reported study, specimens of *A. grypus*, caught at two different sites (20 fish from each site) from the Shahid Ahmadian fish breeding center, Khuzestan Province, Iran. Regarding sampling stations, it should be noted that the two stations were selected randomly and the distances between them were about 10 m. Each site was 100 m long, 50 m wide, and 1 m deep. Fish were also fed by commercial plate both in the morning and afternoon. All animals were captured with a dip net and were considered healthy, on the basis of their external appearance. The other physicochemical properties of the water at the time of sampling are shown in Table 1.

**General histology.** After anesthetics of fish for histological studies by  $1 \text{ mL} \cdot \text{L}^{-1}$  extract of clove flower, the specimens of the anterior, middle, and posterior part of the intestinal bulb and proper intestine were immediately immersed into Bouin's fixative; then, the routine histological procedure was followed and sections of  $4\text{--}6 \mu\text{m}$  were cut by a Leica RM2255 (Germany) microtome, stained with hematoxylin-eosin (H-E) and periodic acid-Schiff (PAS) (Banan Khojasteh 2012). Randomized histological sections of each part of the intestine were submitted to the counting of intraepithelial lymphoid cells. Five microscopic fields per section and five sections per fish were used for histomorphometrical evaluation. The enumerations of intraepithelial lymphoid cells were carried out by counting the number of intraepithelial lymphoid cells per 100 epithelial cells (Doggett and Harris 1991). Slides were observed and photographed using an Olympus BX50 light microscope (Japan) equipped with a Dino-Lite lens together with the DinoCapture software installed on a computer (Carrasson et al. 2006, Kuru et al. 2010).

**TUNEL immunohistochemical staining method.** Fixed specimens were placed in the Phosphate-buffered saline (PBS) for 24 h and embedded in paraffin (Elmore 2007, Rombout et al. 2011). The  $4 \mu\text{m}$  paraffin sections adhered to the glass slides which were pretreated with 0.01% aqueous solution of poly-L-lysine. The sections were deparaffinized by heating the slides for 30 min at  $60^\circ\text{C}$ , followed by two 5 min incubations in a 100% xylene bath at room temperature in Coplin jars. Afterward, the tissue samples were rehydrated by transferring the slides through a graded ethanol series:  $2 \times 3$  min 96% ethanol,  $1 \times 3$  min 90% ethanol,  $1 \times 3$  min 80% ethanol,  $1 \times 3$  min 70% ethanol,  $1 \times 3$  min double-distilled water (DDW). Then, the excess water was carefully blotted, and  $20 \mu\text{g} \cdot \text{mL}^{-1}$  proteinase K solution was placed to cover sections and incubated 15 min at room temperature (Rombout et

**Table 1**

Mean physicochemical parameters based on measurements at different stations, using Horiba U-10 Water Quality Checker

| Parameters   | Warm season | Cold season |
|--|-------------|-------------|
| Salinity [‰]   | 1.20        | 1.00        |
| Temperature [°C]                                     | 28.50       | 11.50       |
| Dissolved oxygen [ $\text{mL} \cdot \text{L}^{-1}$ ] | 7.11        | 9.22        |
| pH   | 6.00        | 7.00        |

al. 2014). Following the proteinase K treatment, the slides were washed  $3 \times 5$  min with DDW. By covering sections with 2% hydrogen peroxide for 5 min at room temperature, the endogenous peroxidases were inactivated. Then, the slides were washed  $3 \times 5$  min with DDW, the excess water was carefully thrown out, and sections were covered with terminal deoxynucleotidyl transferase (TdT) equilibration buffer for 10 min at room temperature. TdT equilibration buffer was removed and sections were covered with TdT reaction buffer. Following this, the slides were incubated in a humidified chamber (Model 123H) for 30 min at 37°C. In order to conserve reagents, a reduced volume of TdT buffer was carefully covered with a glass coverslip during the incubation. The reaction was stopped by incubating slides  $2 \times 10$  min in  $2 \times$  saline sodium citrate (SSC). The slides were rinsed in PBS; then, the nonspecific binding was blocked by covering tissue sections with 2% bovine serum albumin (BSA) solution for 30–60 min at room temperature. Next, the slides were washed  $2 \times 5$  min in PBS and incubated in Vectastain ABC-peroxidase solution for 1 h at 37°C. Later, the slides were washed  $2 \times 5$  min in PBS again and then stained with diaminobenzidine (DAB) staining solution at room temperature (Logue and Martin 2008). Color development was monitored until the desired level of staining was achieved (typically 30 min). The reaction was stopped by incubating slides in DDW. Tissue sections were lightly counterstained with hematoxylin (Groos et al. 2003) and covered with coverslips using Aqua-Poly/Mount mounting medium. Finally, the sections were observed under light microscopy.

**Statistical analyses.** After data normality was tested with Kolmogorov–Smirnov analysis, two-way ANOVA was used to compare the number of lymphocyte cells in both sexes in warm and cold seasons. Finally, the Chi-square test was applied and differences of  $P < 0.05$  were considered statistically significant (Huising et al. 2003, Marchetti et al. 2006). All analysis was also performed using the Graph Pad Prism V.8.0.3 (263) and results presented as the mean  $\pm$  standard error of the mean (Apraku et al. 2019).

## RESULTS

**Macroscopic results.** Macroscopic results showed the intestine wall of *Arabibarbus grypus* was fairly long and thick and was composed of two major parts, including intestinal bulb and proper intestine. The length of the two parts of the intestine and other parameters, such as body weight and standard length is shown for both males and females in cold and warm seasons in Table 2.

**Microscopic results.** Based on the results, the microscopic structure of the intestinal wall of *A. grypus* followed the same pattern that had been observed in other teleosts: tunica mucosa, tunica submucosa, tunica muscularis, and tunica serosa. Mucosa was comprised of two sub-layers: lining epithelium, which is consisted of simple tall columnar cells with a basal nucleus, apical brush border, interspersed mucus-secreting goblet cells, intraepithelial lymphocytes (IELs); and lamina propria, which is an irregular connective tissue with heavy lymphocytic infiltration. Epithelial mucous cells, distinguished by a swollen supranuclear region, were stained purple with the PAS technique. The goblet cells increased in number toward the posterior part of the gut. The massive capillary network was detected in the lamina propria immediately beneath the epithelial layer. The muscularis mucosa was observed to be located between the lamina propria and submucosa; thus, the separation of these two layers was possible. The thickness of the muscularis mucosa increased from the anterior region of the intestinal bulb to the posterior of the gut. Tunica muscularis consisted of two layers of smooth muscle, i.e., inner circular and outer longitudinal. Many nerve plexuses were located between the two muscle layers. Tunica serosa, the loose connective tissue coated by simple squamous epithelial cells, surrounded the outer surface of the gut. It should be noted that the height of the fold in the anterior region of the gut was very high, but toward the end, its height started to reduce, but its thickness increased (Figs. 1A, 1B).

**Gut-Associated Lymphoid Tissue (GALT).** The microscopic results of different parts of the intestinal bulb and proper intestine showed that GALT was present in two different shapes and in two areas. The first area was the lymphoid cells and intra-epithelial cells and the GALT were scattered between these cells. In this part, the lymphocyte cells were arranged in pillar structures and extended to the upper regions of the epithelial cells, but more concentration was observable in the mid bases. The lymphoid cells observed in this portion were more of the lymphocyte type. Other forms of these cells were found in the lamina propria and submucosa regions. In the lamina propria, the lymphoid cells had a strip-shaped arrangement and were placed in several rows below the base membrane, but in the submucosa, the cells were scattered and were less densely packed. It should be noted that the observed lymphoid cells in these areas were more lymphocyte and lymphoblast, and the proportion of plasma cells and macrophages was relatively low. Comparing

Table 2  
Selected morphometric parameters of *Arabibarbus grypus*

| Parameter [cm]                  | Warm season        |                    | Cold season        |                    |
|---------------------------------|--------------------|--------------------|--------------------|--------------------|
|                                 | Male               | Female             | Male               | Female             |
| Length of intestinal bulb (cm)  | 15.10 $\pm$ 0.34   | 14.85 $\pm$ 0.45   | 13.95 $\pm$ 0.68   | 14.35 $\pm$ 0.31   |
| Length of proper intestine (cm) | 131.21 $\pm$ 15.67 | 130.11 $\pm$ 14.27 | 125.57 $\pm$ 16.35 | 127.61 $\pm$ 17.28 |

Values are mean  $\pm$  standard error of the mean.

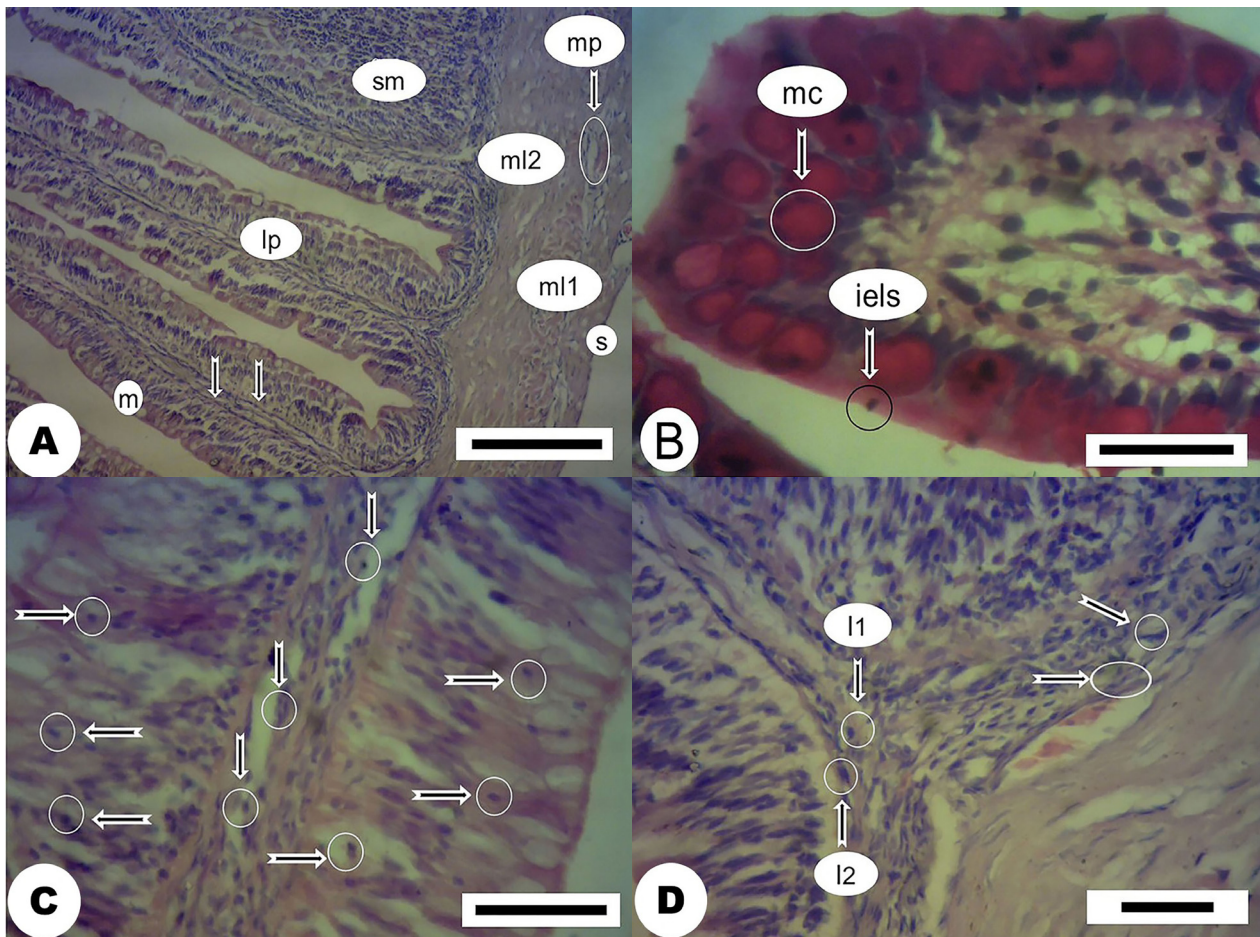


the GALT in the intestinal bulb and the proper intestine during the two warm and cold seasons, it was found that both the density and arrangement of the lymphoid tissue in the gut were more in the cold season than in the warm season, and this is presented in the section dealing with the micrometric results. The lymphoid cells were observed to be more aggregate in the anterior part of the intestinal bulb than in the middle and posterior part of it while the vice versa was true in the proper intestine, i.e., the lymphoid cells were observed to be more aggregate in the posterior part of the proper intestine than in other parts of it. A comparison between the two warm and cold seasons with regard to the intestinal bulb and proper intestine showed that the lymphatic compaction, especially in the base of the epithelial tissue in similar parts, was much higher in the cold season compared to the warm season. It should be noted that no sign of lymphoid follicles and Peyer's

patches was observed in the histological studies of the intestinal bulb and proper intestine (Figs. 1C, 1D).

**Immunohistochemistry.** This technique was used to determine the lymphoid cells which were attached to the gut and planted to apoptosis. Based on this technique, the number of apoptosis cells in the warm season was more than that observed in the cold season. There was a statistically significant difference between the posterior and anterior sections of the intestinal bulb and proper intestine, especially in the mucous layer in both sexes, which was revealed in the micrometric results (Figs. 2A–2D).

**Micrometric results.** The micrometric results showed that not only the distribution of lymphocytic cells in the gut of both male and female specimens was varied in different areas but also in some areas, the difference was statistically significant in both cold and warm seasons ( $P < 0.05$ ).



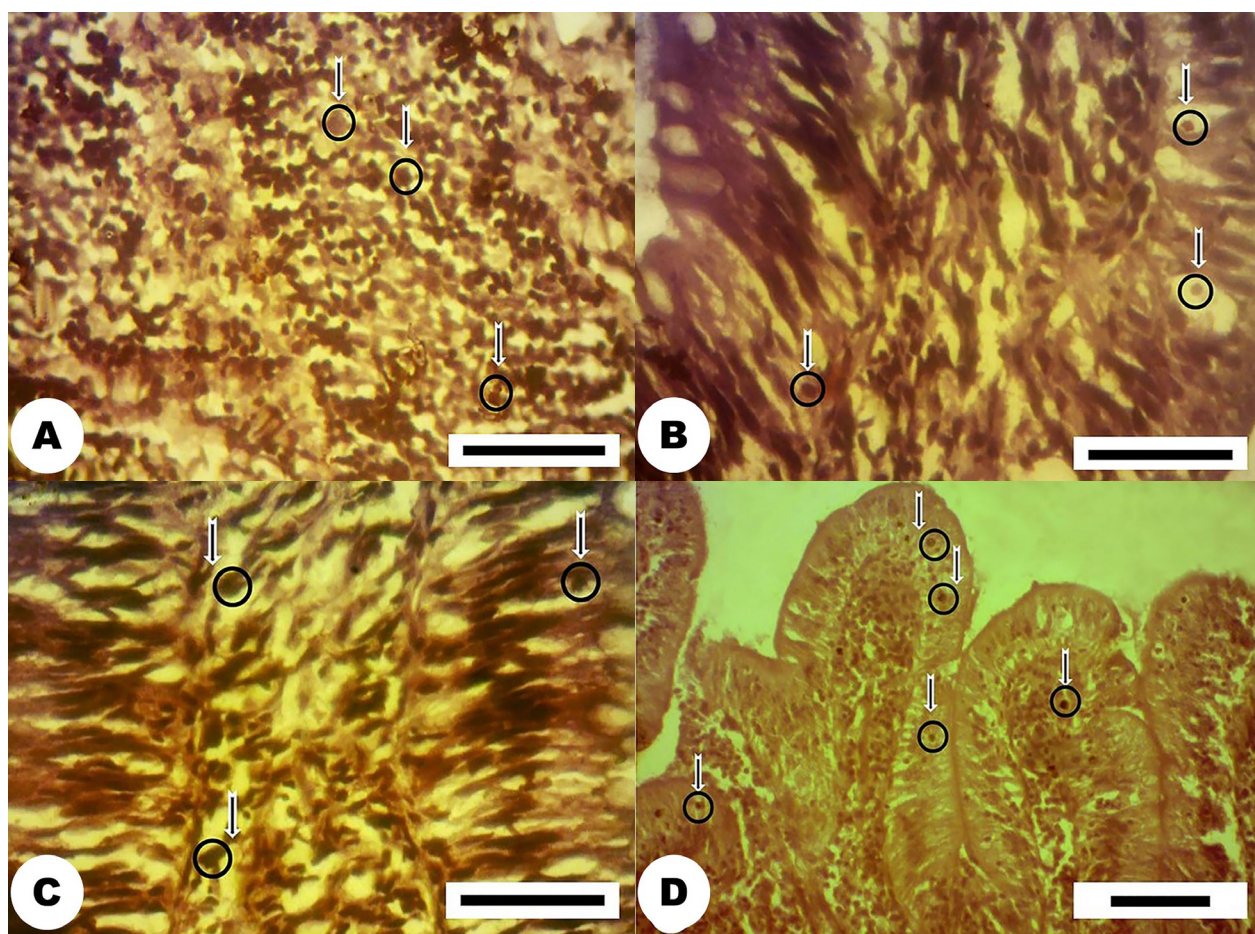
**Fig. 1.** Light microscopic structure of gut in *Arabibarbus grypus* (Hematoxylin and eosin stain). (A) Microscopic view of the histological structure of anterior part of the intestinal bulb in the warm season; m = columnar epithelium, lp = lamina propria, sm = submucosa, mp = myenteric plexus, ml2 = inner circular muscularis layer, ml1 = outer longitudinal muscularis layer, s = serosa; vertical arrows point at muscularis mucosa; (B) Microscopic view of the histological structure of the anterior part of the proper intestine in the cold season, mc = mucosal cells have been shown to PAS positively respond, iels = intraepithelial lymphocytes; (C) Microscopic view of the histological structure of posterior part of mucosa and submucosa of the intestinal bulb in the cold season; in this micrograph, the lymphoid tissue is scattered and less densely packed in submucosa (vertical arrows) and scattered, strip shaped arrangement in mucosa (horizontal arrows); (D) Microscopic view of the histological structure of posterior part of submucosa of the proper intestine in the cold season; in this micrograph, the lymphocyte (l1), lymphoblast (l2), macrophage (oblique arrow), and plasma cell (horizontal arrow) are shown



**Lymphocyte assay in the mucosa and submucosa layers (H-E).** The mean number of lymphocyte cells in the mucosa and submucosa layers in over 100  $\mu\text{m}$  of different areas of the gut of the *A. grypus* was obtained using the hematoxylin-eosin staining method. The highest number of lymphocytic cells in the mucosa layer ( $475.32 \pm 27.18$ ) was found in the posterior of the proper intestine of the male specimen in the cold season, and the lowest number ( $241.38 \pm 13.22$ ) was found in the posterior of the intestinal bulb of the female specimen in the warm season. However, the highest number of lymphocytic cells in the submucosa layer ( $425.13 \pm 11.28$ ) was observed in the posterior part of the proper intestine in the female specimen in the cold season, and the lowest number ( $190.34 \pm 11.21$ ) was observed in the posterior of the intestinal bulb in the female specimen in the warm season. In mucosa, the mean comparison between the groups showed that the number of lymphocytes had decreased significantly in the anterior part of the intestinal bulb in the female specimens compared to that of male specimens in both seasons ( $P < 0.05$ ). Also, the number of lymphocytes in the posterior part of the proper intestine in the female

specimen showed a significant increase compared to that of the male specimen in the cold season ( $P < 0.05$ ). Based on the results obtained through this method, there was no significant difference between males and females in two different seasons in terms of the number of lymphocytes in other parts of the gut (Figs. 3A, 3B, 4A, 4B).

**Apoptotic lymphocytes assay in mucosa and submucosa (TUNEL).** The mean number of apoptotic lymphocyte cells in the mucosa and submucosa layers from over 100  $\mu\text{m}$  of different areas of the intestinal tract of the *A. grypus* is presented below. Based on the results obtained through this method, in mucosa, the highest number of apoptosis lymphocyte cells, i.e.,  $18.31 \pm 1.61$ , was seen in the posterior part of the proper intestine of the male fish in the warm season, and the lowest, i.e.,  $8.21 \pm 1.11$ , was seen in the anterior part of the proper intestine of the female fish in the cold season. In submucosa, the highest number of apoptotic lymphocyte cells was observed in the warm season and in the anterior part of the intestinal bulb of female fish, and the lowest number was observed in the cold season and in the anterior of the intestinal bulb of the female fish. The results of the



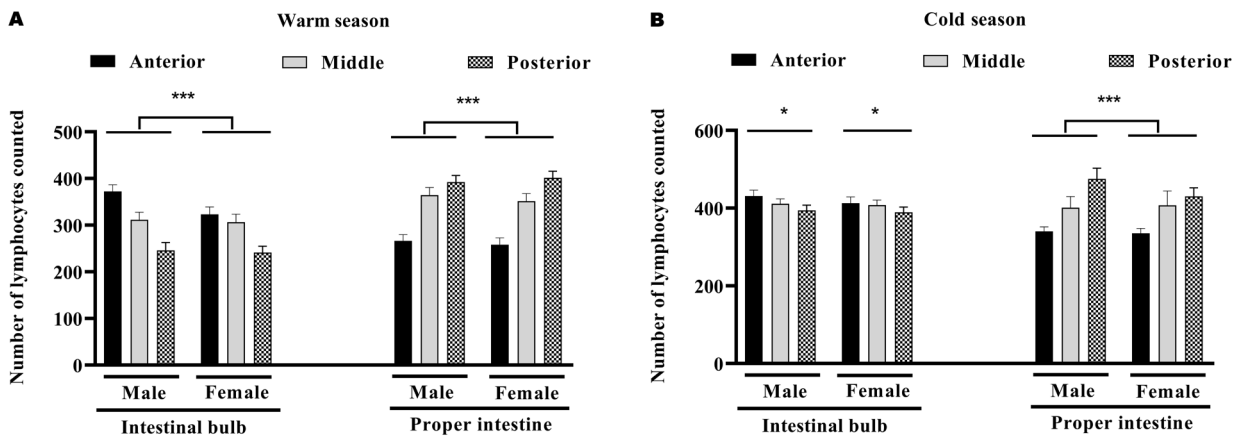
**Fig. 2.** Light microscopic structure of gut in *Arabibarbus grypus* (TUNEL); the apoptotic cells are shown with yellow-brown spots (circle); (A) Microscopic view of the histological structure of mucosa of anterior part of the intestinal bulb in the warm season; (B) Microscopic view of the histological structure of submucosa of the anterior part of the proper intestine in the cold season; (C) Microscopic view of the histological structure of posterior part of mucosa and submucosa of the intestinal bulb in the cold season; (D) Microscopic view of the histological structure of posterior part of mucosa and submucosa of the proper intestine in the warm season

mean comparison between the groups showed that there was no significant difference between males and females in cold and warm seasons in terms of the number of apoptotic lymphocytes in the intestinal bulb and proper intestine (Figs. 5A, 5B, 6A, 6B).

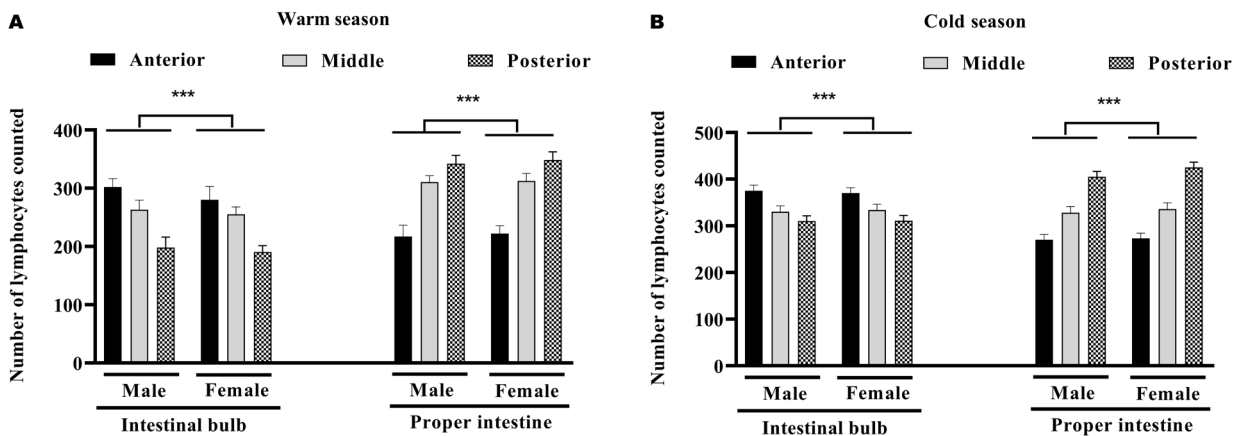
## DISCUSSION

Although there are obvious differences in the microscopic structure of the intestinal tract among different fish species, the wall of the tract of *Arabibarbus grypus*, as also occurs in other fish, is composed of the four layers described for vertebrates. In this species, as well as in other freshwater and marine teleosts, the intestine wall shows a more regular structure, which is similar to the intestine of the common carp, *Cyprinus carpio* Linnaeus, 1758, rainbow trout, *Oncorhynchus mykiss* (Walbaum, 1792), Caspian trout, *Salmo caspius* Kessler, 1877, and guppy *Poecilia reticulata* Peters, 1859 (see Gisbert et al. 2002, Petrincic et al. 2005, Díaz et al. 2008, Holmgren and Olsson 2009, Fuglem et al. 2010). The intestinal

epithelium was coated with simple columnar epithelial and goblet cells. The number of goblet cells increased toward the posterior part of the intestine. The goblet cells, arranged in a continuous sheet, provide consistent lubrication of food particles during swallowing, protect the epithelial surface against mechanical damages and bacteria invasion, being also related to ionic absorption (Hernandez et al. 2009). Fish are continuously exposed to a microbial-rich environment in freshwater or seawater. The main mucosa-associated lymphoid tissues of teleosts are the gut-associated lymphoid tissue which is clearly different morphologically and functionally (Grau et al. 1992). In this study, GALT was represented throughout the mucosa and a lesser degree, it was extended in the submucosa. In a number of teleost fishes a diffused distribution of lymphocytes, plasma cells, and macrophages can be observed. Similar observations were reported in an Indian major carp, *Gibelion catla* (Hamilton, 1822) and Atlantic halibut, *Hippoglossus hippoglossus* (Linnaeus, 1758) (see Grove et al. 2006). Researchers believe that



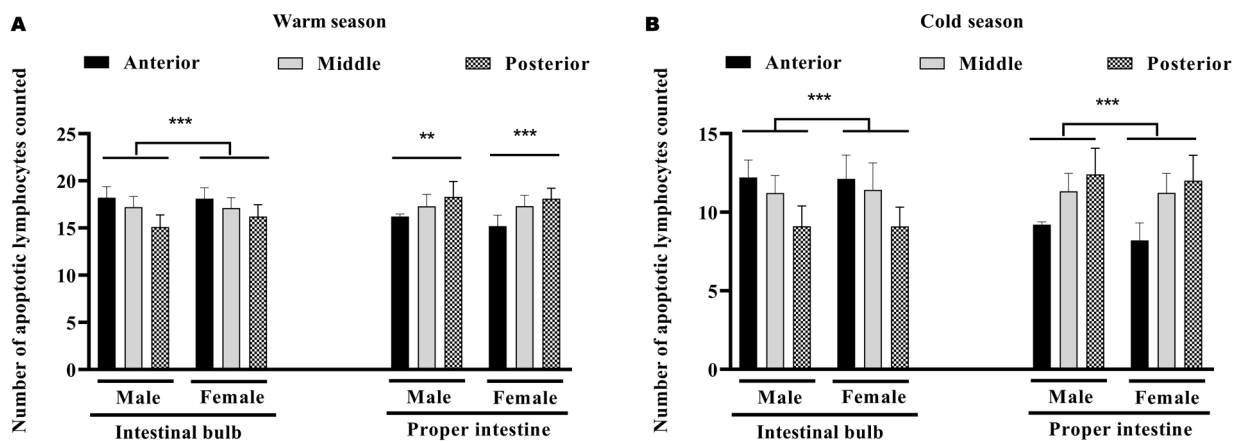
**Fig. 3.** Number of lymphocytes (mean  $\pm$  standard error of the mean) in the mucosa over 100  $\mu$ m of different areas of the intestine of the *Arabibarbus grypus* in warm (A) and cold (B) season; analyzed by hematoxylin and eosin staining method; different number of asterisks in each column indicate a significant difference ( $P < 0.05$ )



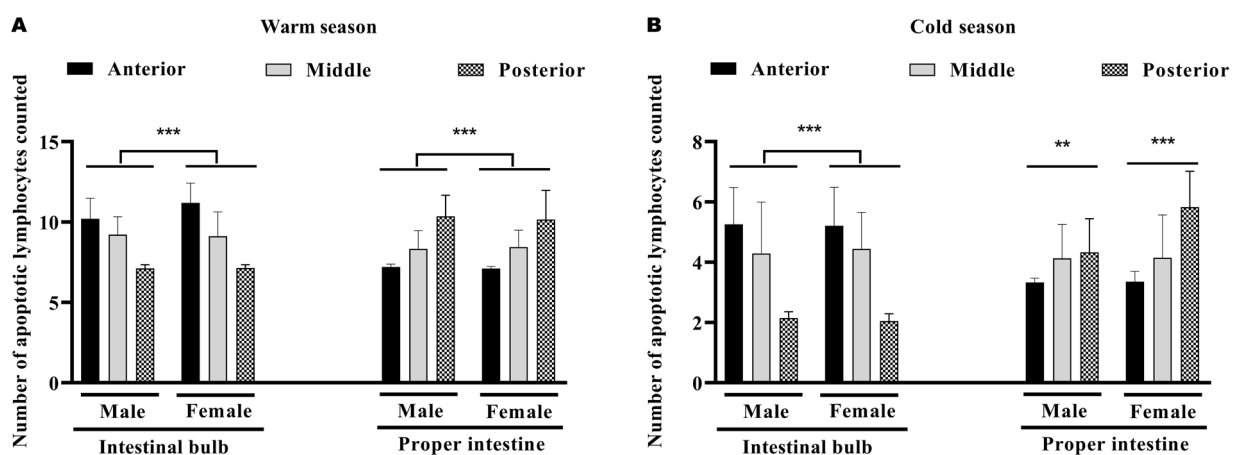
**Fig. 4.** Number of lymphocytes (mean  $\pm$  standard error of the mean) in the submucosa over 100  $\mu$ m of different areas of the intestine of the *Arabibarbus grypus* in warm (A) and cold (B) season; analyzed by hematoxylin and eosin staining method; different number of asterisks in each column indicate a significant difference ( $P < 0.05$ )

fish lack the organized GALT organ like other vertebrates such as Peyer's patches or mesenteric lymph nodes. But in fishes, lymphoid cells are present in a scattered cluster along the alimentary canal (Rombout et al. 2014, Salinas 2015). The highest incidence of lymphocytic cells in both sexes in warm and cold seasons was observed in the anterior part of the intestinal bulb and posterior part of the proper intestine. According to the results of this study, a large accumulation of lymphocytic cells was located in the lamina propria and consisted of aggregations of lymphocytes together with macrophages, and plasma cells. Such large accumulation patches were located in the lamina propria and consisted of aggregations of lymphocytes together with granulocytes, macrophages and plasma cells also have been reported in Mozambique tilapia, *Oreochromis mossambicus* (Peters, 1852) (see Doggett and Harris 1991) and goldfish, *Carassius auratus* (Linnaeus, 1758) (see Salinas 2015). Nevertheless, most

researchers have reported the presence of lymphocyte cells in the intestinal tissue. These cells are more than T-type and are usually derived from two different sources, namely thymus and GALT (Pedini et al. 2002, Mabbott et al. 2013). Also similar to the results of our microscopic observations on the gut of *A. grypus* the presence of lymphocyte cells in epithelium on turbot, *Scophthalmus maximus* (Linnaeus, 1758), was reported in the basal area of the epithelial cells (Sampaio et al. 2018). In both warm and cold seasons, there was a significant difference in the number of intraepithelial lymphocytes along the length of the intestine and it showed significantly increased towards the posterior intestine. The same result was also reported in common carp, *C. carpio* (see Saha et al. 2002) and in sea bass, *Dicentrarchus labrax* (Linnaeus, 1758) (see Piccheietti et al. 1997). Nevertheless, Rombout et al. (2011) did not observe a significant difference in the density of intraepithelial lymphocytes along the



**Fig. 5.** Number of apoptotic lymphocytes (mean  $\pm$  standard error of the mean) in the mucosa over 100  $\mu\text{m}$  of different areas of the intestine of the *Arabibarbus grypus* in warm (A) and cold (B) season; analyzed by TUNEL immunohistochemistry staining method; different number of asterisks in each column indicate a significant difference ( $P < 0.05$ )



**Fig. 6.** Number of apoptotic lymphocytes (mean  $\pm$  standard error of the mean) in the submucosa over 100  $\mu\text{m}$  of different areas of the intestine of the *Arabibarbus grypus* in warm (A) and cold (B) season; analyzed by TUNEL immunohistochemistry staining method; different number of asterisks in each column indicate a significant difference ( $P < 0.05$ )



length of the intestine. However, some researchers, in a similar study on rosy barb, *Pethia conchonius* (Hamilton, 1822) (family Cyprinidae), reported that there was a significant difference in the distribution of GALT in the various intestinal areas of the specimen, in a way that the number of leukocytes was clearly more in the anterior and posterior parts than in the middle areas (Niklasson et al. 2011, Salinas et al. 2011). Some researchers believe that the differences between species can be a reason for the non-equal distribution of leukocyte cells in their guts (Saha et al. 2002, Lycke 2012). In a recent study TUNEL immunohistochemical staining method was used to show apoptotic cells (Abdi, unpublished data). Accordingly, apoptosis was higher in all parts of the intestine in the warm season than in the cold season. Because TUNEL staining was initially described as a method for staining cells that have undergone programmed cell death or apoptosis, and exhibit the biochemical hallmark of apoptosis internucleosomal DNA fragmentation (Saha et al. 2002, Mayerl et al. 2006). Based on the results of this study on *A. grypus*, it was found that the mucosal immune system is more active in the cold season. Finally, the more motility of the mucosal immunity during the cold season, mucosal vaccination at the same time, will be discussed.

#### ACKNOWLEDGMENTS

The study presented in this paper was conducted in the framework of the project was supported financially by a scientific research Grant (No. 97-400-04) of the Vice Chancellor for Research of the Khorramshahr University of Marine Science and Technology, Iran. The authors thank to the management staff of the project for their support. The authors express their deepest gratitude to Dr. Marian Y. Hu, Institute of Physiology, University of Kiel, who read the paper carefully and made very detailed scientific comments.

#### REFERENCES

- Abol-Munafi A.B., Liem P.T., Van M.V., Ambak M.A.** 2006. Histological ontogeny of the digestive system of marble goby (*Oxyeleotris marmoratus*) larvae. *Journal of Sustainability Science and Management* **1** (2): 79–86.
- Alcorn S.W., Murray A.L., Pascho R.J.** 2002. Effects of rearing temperature on immune functions in sockeye salmon (*Oncorhynchus nerka*). *Fish and Shellfish Immunology* **12** (4): 303–334. DOI: [10.1006/fsim.2001.0373](https://doi.org/10.1006/fsim.2001.0373)
- Apraku A., Huang X., Yusuf A., Cornel A., Ayisi C.L., Asiedu B.** 2019. Impact of dietary oil replacement on muscle and liver enzymes activity, histomorphology and growth-related genes on Nile tilapia. *Comparative Biochemistry and Physiology Part C: Toxicology and Pharmacology* **223**: 15–25. DOI: [10.1016/j.cbpc.2019.05.002](https://doi.org/10.1016/j.cbpc.2019.05.002)
- Banan Khojasteh S.M.** 2012. The morphology of the post-gastric alimentary canal in teleost fishes: A brief review. *International Journal of Aquatic Science* **3** (2): 71–88.
- Canan B., do Nascimento W.S., da Silva N.B., Chellappa S.** 2012. Morphohistology of the digestive tract of the damselfish (*Stegastes fuscus*) (Osteichthyes: Pomacentridae). *The Scientific World Journal* **2012**: e787316. DOI: [10.1100/2012/787316](https://doi.org/10.1100/2012/787316)
- Carrasson M., Grau A., Dopazo L.R., Crespo S.** 2006. A histological, histochemical and ultrastructural study of the digestive tract of *Dentex dentex* (Pisces, Sparidae). *Histology and Histopathology, Cellular and Molecular Biology* **21** (6): 579–593. DOI: [10.14670/HH-21.579](https://doi.org/10.14670/HH-21.579)
- Çınar K., Şenol N.** 2006. Histological and histochemical characterization of the mucosa of the digestive tract in flower fish (*Pseudophoxinus antalyae*). *Anatomia, Histologia, Embryologia* **35** (3): 147–151. DOI: [10.1111/j.1439-0264.2005.00629.x](https://doi.org/10.1111/j.1439-0264.2005.00629.x)
- Dai X., Shu M., Fang W.** 2007. Histological and ultrastructural study of the digestive tract of rice field eel, *Monopterus albus*. *Journal of Applied Ichthyology* **23** (2): 177–183. DOI: [10.1111/j.1439-0426.2006.00830.x](https://doi.org/10.1111/j.1439-0426.2006.00830.x)
- Díaz A.O., García A.M., Goldemberg A.L.** 2008. Glycoconjugates in the mucosa of the digestive tract of *Cynoscion guatucupa*: A histochemical study. *Acta Histochemica* **110** (1): 76–85. DOI: [10.1016/j.acthis.2007.08.002](https://doi.org/10.1016/j.acthis.2007.08.002)
- Doggett T.A., Harris J.E.** 1991. Morphology the gut associated lymphoid tissue of *Oreochromis mossambicus* and its role in antigen absorption. *Fish and Shellfish Immunology* **1** (3): 213–227. DOI: [10.1016/S1050-4648\(10\)80006-3](https://doi.org/10.1016/S1050-4648(10)80006-3)
- Duman M., Özpolat E.** 2015. Effects of water extract of propolis on fresh shibuta (*Barbus grypus*) fillets during chilled storage. *Food Chemistry* **189**: 80–85. DOI: [10.1016/j.foodchem.2014.08.091](https://doi.org/10.1016/j.foodchem.2014.08.091)
- Elmore S.** 2007. Apoptosis: A review of programmed cell death. *Toxicologic Pathology* **35** (4): 495–516. DOI: [10.1080/01926230701320337](https://doi.org/10.1080/01926230701320337)
- Fournier-Betz V., Quentel C., Lamour F., Leven A.** 2000. Immunocytochemical detection of Ig-positive cells in blood, lymphoid organs and the gut of the turbot (*Scophthalmus maximus*). *Fish and Shellfish Immunology* **10** (2): 187–202. DOI: [10.1006/fsim.1999.0235](https://doi.org/10.1006/fsim.1999.0235)
- Fuglem B., Jirillo E., Bjerkås I., Kiyono H., Nochi T., Yuki Y., Raida M., Fischer U., Koppang E.O.** 2010. Antigen-sampling cells in the salmonid intestinal epithelium. *Developmental and Comparative Immunology* **34** (7): 768–774. DOI: [10.1016/j.dci.2010.02.007](https://doi.org/10.1016/j.dci.2010.02.007)
- Giffard-Mena I., Charmantier G., Grousset E., Aujoulat F., Castille R.** 2006. Digestive tract ontogeny of *Dicentrarchus labrax*: Implication in osmoregulation. *Development Growth and Differentiation* **48** (3): 139–151. DOI: [10.1111/j.1440-169X.2006.00852.x](https://doi.org/10.1111/j.1440-169X.2006.00852.x)
- Gisbert E., Merino G., Muguet J.B., Bush D., Piedrahita R.H., Conklin D.E.** 2002. Morphological development and allometric growth patterns in hatchery-reared California halibut larvae. *Journal of*



- Fish Biology **61** (5): 1217–1229. DOI: [10.1111/j.1095-8649.2002.tb02466.x](https://doi.org/10.1111/j.1095-8649.2002.tb02466.x)
- Gisbert E., Piedrahit R.H., Conklin D.E.** 2004. Ontogenetic development of the digestive system in California halibut (*Paralichthys californicus*) with notes on feeding practices. *Aquaculture* **232** (1–4): 455–470. DOI: [10.1016/S0044-8486\(03\)00457-5](https://doi.org/10.1016/S0044-8486(03)00457-5)
- Grau A., Crespo S., Sarasquete M.C., González de Canales M.L.** 1992. The digestive tract of the amberjack *Seriola dumerili*, Risso: A light and scanning electron microscope study. *Journal of Fish Biology* **41** (2): 287–303. DOI: [10.1111/j.1095-8649.1992.tb02658.x](https://doi.org/10.1111/j.1095-8649.1992.tb02658.x)
- Groos S., Reale E., Luciano L.** 2003. General suitability of techniques for in situ detection of apoptosis in small intestinal epithelium. *Anatomical Record Part A* **272** (2): 503–513. DOI: [10.1002/ar.a.10063](https://doi.org/10.1002/ar.a.10063)
- Grove S., Johansen R., Reitan L.J., Press C.M.** 2006. Immune- and enzyme histochemical characterisation of leucocyte populations within lymphoid and mucosal tissues of Atlantic halibut (*Hipoglossus hipoglossus*). *Fish and Shellfish Immunology* **20** (5): 693–708. DOI: [10.1016/j.fsi.2005.08.009](https://doi.org/10.1016/j.fsi.2005.08.009)
- Hernández D.R., Pérez Gianeselli M., Domitrovic H.A.** 2009. Morphology, histology and histochemistry of the digestive system of the South American catfish (*Rhamdia quelen*). *International Journal of Morphology* **27** (1): 5–111. DOI: [10.4067/S0717-95022009000100019](https://doi.org/10.4067/S0717-95022009000100019)
- Holmgren S., Olsson C.** 2009. [Chapter 10] The neuronal and endocrine regulation of gut function. Pp. 467–512. DOI: [10.1016/S1546-5098\(09\)28010-1](https://doi.org/10.1016/S1546-5098(09)28010-1) In: Farrell A.P., Brauner C.J., Hoar W.S., Randall D.J. (eds.) *Fish neuroendocrinology*. Vol. 28. *Fish physiology*. Academic Press.
- Huising M.O., Guichelaar T., Hoek C., Verburg-van Kemenade B.M.L., Flik G., Savelkoul H.F.J., Rombout J.H.W.M.** 2003. Increased efficacy of immersion vaccination in fish with hyperosmotic pretreatment. *Vaccine* **21** (27–30): 4178–4193. DOI: [10.1016/S0264-410X\(03\)00497-3](https://doi.org/10.1016/S0264-410X(03)00497-3)
- Krogdahl A., Bakke-McKellep A.M.** 2005. Fasting and refeeding cause rapid changes in intestinal tissue mass and digestive enzyme capacities of Atlantic salmon (*Salmo salar* L.). *Comparative Biochemistry and Physiology Part A: Molecular and Integrative Physiology* **141** (4): 450–460. DOI: [10.1016/j.cbpb.2005.06.002](https://doi.org/10.1016/j.cbpb.2005.06.002)
- Kuru N., Çınar K., Şenol N., Demirbağ E., Diler D.** 2010. Endocrine cells in the gastrointestinal tract of *Garra rufa*. *Kafkas Üniversitesi Veteriner Fakültesi Dergisi* **16** (Suppl. b): S245–S241. DOI: [10.9775/kvfd.2009.1561](https://doi.org/10.9775/kvfd.2009.1561)
- Logue S.E., Martin S.J.** 2008. Caspase activation cascades in apoptosis. *Biochemical Society Transactions*: **36** (1):1–9. DOI: [10.1042/BST0360001](https://doi.org/10.1042/BST0360001)
- Lycke N.** 2012. Recent progress in mucosal vaccine development: Potential and limitations. *Nature Reviews Immunology* **12** (8): 592–605. DOI: [10.1038/nri3251](https://doi.org/10.1038/nri3251)
- Mabbott N.A., Donaldson D.S., Ohno H., Williams I.R., Mahajan A.** 2013. Microfold (M) cells: Important immunosurveillance posts in the intestinal epithelium. *Mucosal Immunology* **6** (4): 666–677. DOI: [10.1038/mi.2013.30](https://doi.org/10.1038/mi.2013.30)
- Marchetti L., Capacchietti M., Sabbieti M.G., Accili D., Materazzi G., Menghi G.** 2006. Histology and carbohydrate histochemistry of the alimentary canal in the rainbow trout *Oncorhynchus mykiss*. *Journal of Fish Biology* **68** (6): 1808–1821. DOI: [10.1111/j.0022-1112.2006.01063.x](https://doi.org/10.1111/j.0022-1112.2006.01063.x)
- Mayerl C., Hammerer-Lercher A., Puschendorf B., Prelog M.** 2006. Simultaneous detection of a cell surface antigen and apoptosis by microwave-sensitized TUNEL assay on paraffin sections. *Journal of Immunological Methods* **316** (1–2): 163–166. DOI: [10.1016/j.jim.2006.08.013](https://doi.org/10.1016/j.jim.2006.08.013)
- Niklasson L., Sundh H., Fridell F., Taranger G.L., Sundell K.** 2011. Disturbance of the intestinal mucosal immune system of farmed Atlantic salmon (*Salmo salar*), in response to long-term hypoxic conditions. *Fish and Shellfish Immunology* **31** (6): 1072–1080. DOI: [10.1016/j.fsi.2011.09.011](https://doi.org/10.1016/j.fsi.2011.09.011)
- Pedini V., Scocco P., Garguilo A.M., Ceccarelli P., Lørvik S.** 2002. Glycoconjugates characterization in the intestine of *Umbrina cirrosa* by means of lectin histochemistry. *Journal of Fish Biology* **61** (6): 1363–1372. DOI: [10.1111/j.1095-8649.2002.tb02482.x](https://doi.org/10.1111/j.1095-8649.2002.tb02482.x)
- Petrinec Z., Nejedli S., Kužir S., Opačak A.** 2005. Mucosubstances of the digestive tract mucosa in northern pike (*Esox lucius* L.) and European catfish (*Silurus glanis* L.). *Veterinarski Arhiv* **75** (4): 317–372.
- Piccheietti S., Terribili F.R., Mastrolia L., Scapigliati G., Abelli L.** 1997. Expression of lymphocyte antigenic determinants in developing gut-associated lymphoid tissue of the sea bass *Dicentrarchus labrax* (L.). *Anatomy and Embryology* **96** (6): 457–463. DOI: [10.1007/s004290050113](https://doi.org/10.1007/s004290050113)
- Rombout J.H.W.M., Yang G., Kiron V.** 2014. Adaptive immune responses at mucosal surfaces of teleost fish. *Fish and Shellfish Immunology* **40** (2): 634–643. DOI: [10.1016/j.fsi.2014.08.020](https://doi.org/10.1016/j.fsi.2014.08.020)
- Rombout J.H.W.M., Abelli L., Picchietti S., Scapigliati G., Kiron V.** 2011. Teleost intestinal immunology. *Fish and Shellfish Immunology* **31** (5): 616–626. DOI: [10.1016/j.fsi.2010.09.001](https://doi.org/10.1016/j.fsi.2010.09.001)
- Saha N.R., Usami T., Suzuki Y.** 2002. Seasonal changes in the immune activities of common carp (*Cyprinus carpio*). *Fish Physiology Biochemistry* **26**: 379–87. DOI: [10.1023/B:FISH.0000009275.25834.67](https://doi.org/10.1023/B:FISH.0000009275.25834.67)
- Salinas I.** 2015. The mucosal immune system of teleost fish. *Biology* **4** (3): 525–539. DOI: [10.3390/biology4030525](https://doi.org/10.3390/biology4030525)
- Salinas I., Zhang Y.-A., Sunyer J.O.** 2011. Mucosal immunoglobulins and B cells of teleost fish. *Developmental and Comparative Immunology* **35** (12): 46–65. DOI: [10.1016/j.dci.2011.11.009](https://doi.org/10.1016/j.dci.2011.11.009)

- Sampaio E., Lopes A.R., Francisco S., Paula R.J., Pimentel M., Maulvault A.L., Repolho T., Grilo T.F., Pousão-Ferreira P., Marques A., Rosa R.** 2018. Ocean acidification dampens physiological stress response to warming and contamination in a commercially-important fish (*Argyrosomus regius*). *Science of the Total Environment* **618**: 388–398. DOI: [10.1016/j.scitotenv.2017.11.059](https://doi.org/10.1016/j.scitotenv.2017.11.059)
- Venkatesh P., Jeyapriya S.P., Suresh N., Vivekananthan T.** 2014. Report on gut associated lymphoid tissue (GALT) in freshwater fish *Channa punctatus* (Bloch). *International Journal of Pure and Applied Zoology* **2** (2): 95–99.

Received: 27 March 2020

Accepted: 5 November 2020

Published electronically: 7 December 2020