

Teresa POJMAŃSKA¹, Teresa WŁASOW², Piotr GOMULKA²,

Parasitology

**SPHAEROSPORA RENICOLA AND S. MOLNARI IN POLAND
AND SPRING SPHAEROSPOROSIS OF CARP**

**SPHAEROSPORA RENICOLA I S. MOLNARI ORAZ WIOSENNA
SFEROSPOROZA KARPI**

¹ Stefański Institute of Parasitology, Polish Academy of Sciences, Warsaw, Poland

² Department of Basic Fisheries Sciences, University of Agriculture and Technology,
Olsztyn, Poland

Two myxosporean species: *Sphaerospora renicola* Dyková et Lom, 1982 and *S. molnari* Lom, Dyková, Pavlaskova et Grupcheva, 1983 were recorded for the first time in Poland. They were found in young carp after first overwintering in cold- and warm-water ponds. Localisation of different developmental stages in carp tissues is described. Differences in frequency of particular developmental stages were noticed between the cold and warm ponds. In fish taken from cold ponds spores occurred rarely. In fish from the warm pond spores were abundant, but extrasporogonic stages were practically undetectable. Symptoms of spring sphaerosporosis are described. They were mainly connected with the presence and release of spores, and were much more serious in carp from the warm pond.

INTRODUCTION

Only two species of *Sphaerospora* have been so far recorded in the parasite fauna of fish in Poland. The native *S. masovica* Cohn 1902 was found in bream from the Vistula river (Kozicka 1951, Grabda 1971) and in bream and roach from the Włocławek dam reservoir on the Vistula river (Waluga and Własow 1988). The introduced *S. carassii* Kudo 1919 occurred in common, big head, grass and silver carp from pond culture (Waluga and Budzyńska 1980, 1981; Waluga 1983; Pojmańska and Chabros 1993). The pathogenic effects of the native species have not been observed, whereas *S. carassii* caused serious disease, especially in young carp in summer (Waluga and Budzyńska 1980, 1981).

The present study deals with the occurrence of two other *Sphaerospora* species, recorded for the first time in Poland, and with health problems of young carp affected in pond cultures.

MATERIALS AND METHODS

Three groups of common carp *Cyprinus carpio* L. were examined in spring after their first overwintering. Two groups were taken from traditional soil ponds, supplied with cold water from coregonid lake Szelaż: one in April 1994 (cold group C1, 29 specimens) and the other in April 1995 (cold group C2, 10 specimens). The third group comprised three specimens of carp, chosen from the sample of 15 fish, all with the symptoms of sphaerosporosis, taken in March 1995 from the pond supplied with cooling water from the Ostrołęka power station (warm group W). All the above mentioned objects are situated in north-east part of Poland.

Total lengths of examined fish were: 11–18 cm, mean 13.1 cm for the C1 group; 10.3–20.5 cm, mean 17.6 cm for the C2 group; 16.2 cm, 17.4 cm and 19.3 cm, mean 17.6 cm for the W group. Body weights were respectively: 17–18 g, mean 37 g; 17–88 g, mean 37 g; 100 g, 127 g, 143 g, mean 123 g.

Parasitological examinations were performed on both wet and fixed preparations from gills, skin, liver, kidney, intestine, gall bladder, swim bladder, brain and eye. Tissue samples for histological studies were fixed in Bouin's solution. Sections (5 µm) of paraffin-wax embedded tissues were stained with haematoxylin and eosin. Smears of blood and imprints of kidney were made with buffered Giemsa. Blood was taken from caudal vessels, using heparin as anticoagulant. The number of extrasporogonic stages of *Sphaerospora* in blood was calculated per 10 000 erythrocytes.

RESULTS

Occurrence of *Sphaerospora* spp.

Two species of *Sphaerospora* were identified on the basis of spore structures: *S. renicola* Dyková et Lom, 1982 and *S. molnari* Dyková, Pavlaskova et Grupcheva, 1983. *S. renicola* was noted only in C1 group, while *S. molnari* occurred in both groups examined in 1995: C2 and W. In both C groups spores occurred rarely (*S. renicola* in 3.3% of C1 group, *S. molnari* in 10% of C2 group). In the W group all the examined fish harboured a great number of spores of *S. molnari*.

Apart from spores, extrasporogonic forms of *Sphaerospora* were detected in blood of about 60% of fish from C1 and C2 groups; in W group they were visible only sporadically. The extrasporogonic forms were represented by primary (PC), secondary (SC) and tertiary

(TC) cells. In fish from cold ponds, the mean number of different extrasporogonic forms was as follows: 3.5 PC, 6.5 SC and 0.5 TC (max: 19 PC, 23 SC, 3 TC) per 10 000 erythrocytes in C1; 6.7 PC, 2.3 SC and 2.0 TC (max: 23 PC, 6SC, 4 TC) in C2.

Amoeboid plasmodia with refractile granules were present in both C groups (60% in C1, and 50% in C2) and in W (100%); they exhibited movement, especially in gills, rarely in swim bladder or kidney, intestine and skin.

Spores or sporoblasts of *S. renicola* were found only in kidney of C1 carp, mainly in the tubular lumen (Fig. 1) although sometimes they were also observed inside the epithelial cells (Fig. 2). Spores of *S. molnari* were present in kidneys of C2 carp, while in W carp they occupied also the other tissues, namely gills and skin. They were especially numerous in gills where they were visible in several layers of epithelium (Figs 3, 4). In some sections they were outside the gill tissue, in the mucus (Fig. 5).

Extrasporogonic forms were observed in blood smears (Figs. 12, 13, 15, 16) and the imprints of C1 and C2 carp kidney (Figs. 11, 14). In the W group they were detected sporadically only in renal smears.

Amoeboid plasmodia with granular cytoplasm occurred in all fish groups mainly in gills, showing a strong preference for the central part of gill lamellae, where they were sometimes concentrated in a great number (Fig. 6, 7). In kidneys they occupied, above all, tubular lumen (Fig. 10) and interstitium, some intracellular forms being also observed. Rarely were they found in swim bladder, intestine, and skin.

Sphaerosporosis

The presence of any developmental stage of *Sphaerospora* was generally accompanied by some pathological changes in the affected tissues.

In gills, spores of *S. molnari* caused mainly necrotic changes of their marginal fragments. Dislocation of epithelium and focal proliferative changes were also observed. The presence of trophic amoeboid plasmodia in central part of gill lamellae was accompanied by proliferation of epithelium and fusion of secondary lamellae (Fig. 10). Some capillaries were dilated or congested.

In kidneys, focal necrotic changes were visible in the proximity of spores, especially in the places of their release from tissue (Fig. 9). The presence of amoeboid plasmodia (Fig. 10) was accompanied by different dystrophic changes as well as congestion of glomeruli, extravasation of erythrocytes and eosinophilic infiltrations.

The pathogenic effect of extrasporogonic forms in blood was manifested by haemolysis of red cells, sphaerocytosis and amitotic division of erythrocytes (Fig. 12), erythroblastosis (Fig. 13), changes in nuclei (karyolysis, karyorexis, pycnosis) (Figs. 13, 15, 16)

and vacuolisation of cytoplasm (Fig. 13). In some fish the reactive neutrofilia in peripheral blood and increase in the number of eosinophils in renal smears occurred (Fig. 11).

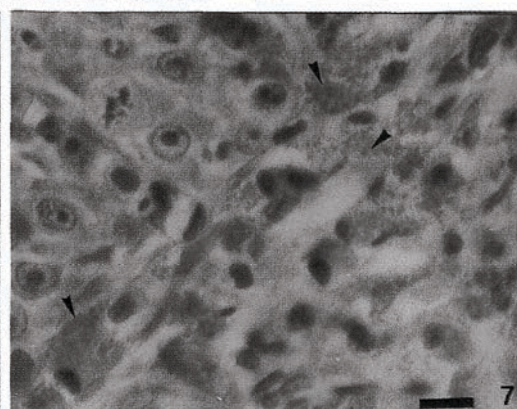
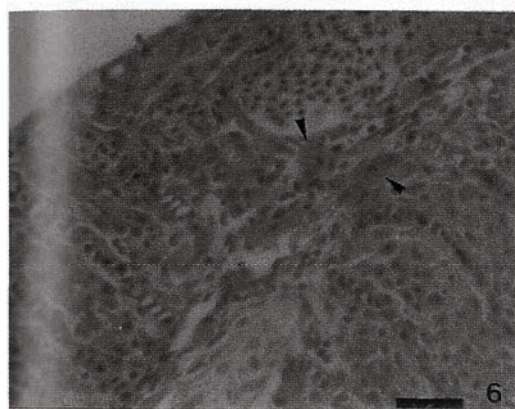
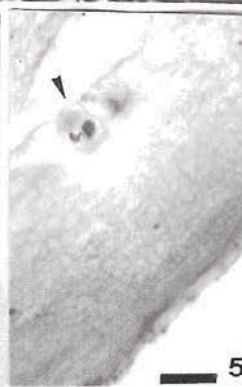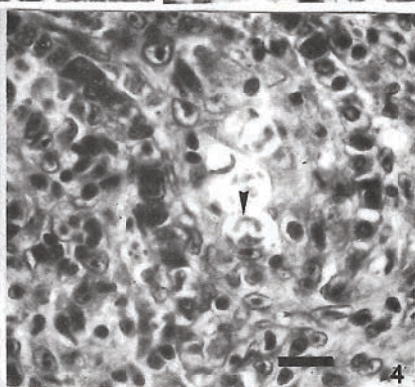
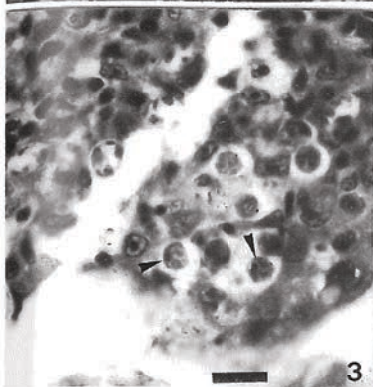
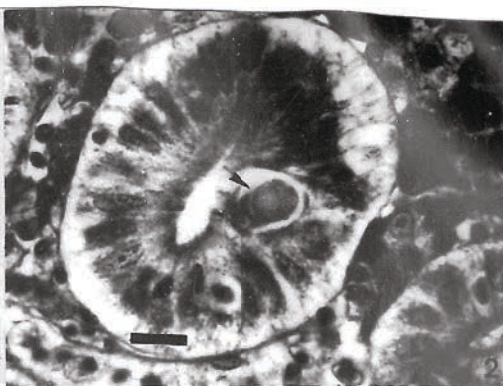
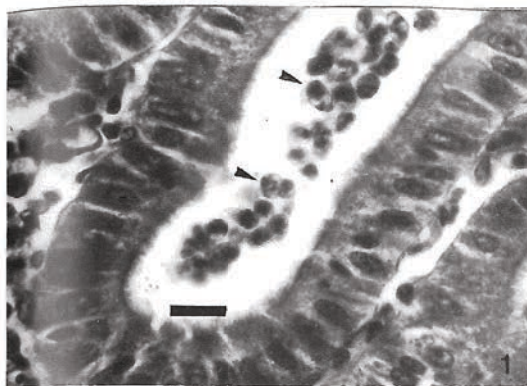
The observation of live fish showed that in every pond under study single carp exhibited loss of balance. In *post mortem* examinations of these individuals the symptoms of chronic swim bladder inflammation was evident.

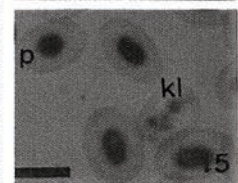
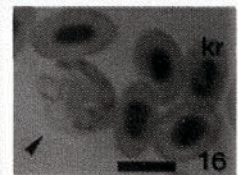
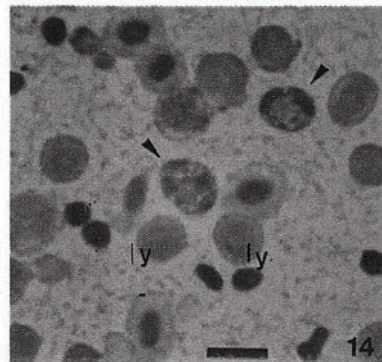
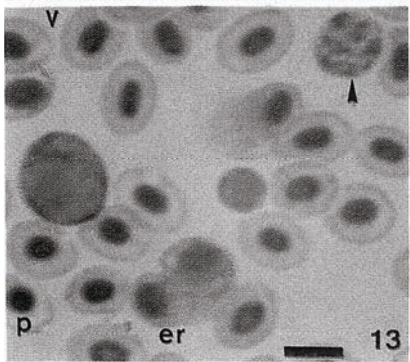
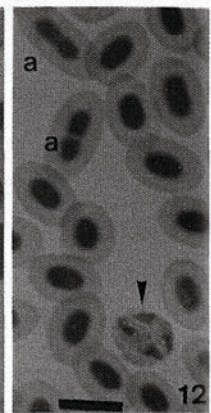
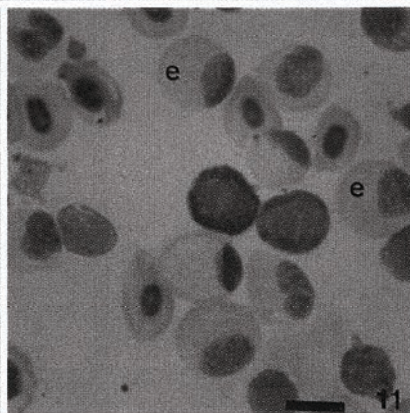
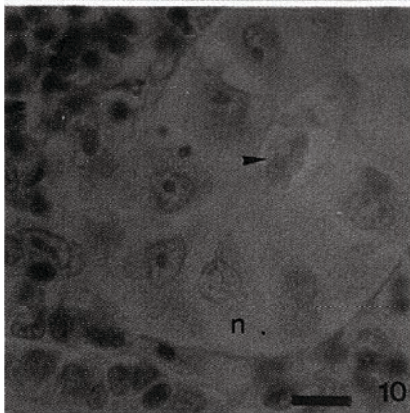
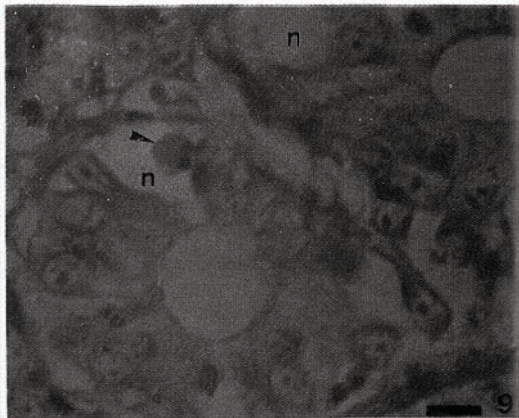
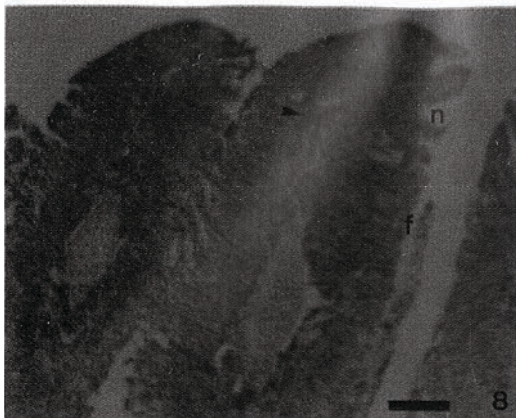
DISCUSSION

Sphaerospora renicola and *S. molnari*, recorded for the first time in Poland are very popular parasites of carp in south part of the Czech Republic, and typical pathogenic myxosporeans in intensive aquaculture (Antychowicz 1984, 1985; Dyková and Lom 1988; Lom et al. 1989, Lom and Dyková 1992; El-Matbouli et al. 1992, Yeney and Yeney 1995). In our material in the first year of the study only *S. renicola* was identified (in C1 group), while in the second year only *S. molnari* was recognized in both the cold (C2) and warm (W) ponds. The reason of this change in the agent of sphaerosporosis in cold ponds under study is not clear. In contrast, the observed differences in the frequency of particular developmental stages of *Sphaerospora* in cold and warm ponds can be attributed to the influence of temperature, which probably regulated the rate of the development of these myxosporeans.

Localisation of individual developmental forms of *Sphaerospora* was generally the same, as described in the literature (Antychowicz 1984, 1985; Dyková and Lom, 1988; Lom et al. 1989, Lom and Dyková 1992; El-Matbouli et al. 1992, Grossheider and Körting 1993). Our studies confirmed the previous observation that the spores of *S. molnari*, similar as those of *S. carassi*, occurred mainly in gills, causing often heavy gill sphaerosporosis (Waluga and Budzyńska 1981, Waluga 1983), but they can also be formed in the other fish tissues. In contrast *S. renicola*, similar as *S. angulata* parasitizing also carp (Molnar 1980) and several species known from the kidneys of the other fish (for example *S. coregoni*: El-Matbouli et al. 1995, or *S. truttae*: Fischer-Scherl et al. 1986, McGeorge et al. 1996; see also: Lom and Dyková 1992) belongs to the group of species, the spores of which occur exclusively in kidneys, and are the agents of PKD. As extrasporogonic forms are concerned, we found them in blood and kidney, but not in swim bladder, which was mentioned by Lom and Dyková (1992) as a site, where the second extrasporogonic cycle of

Figs. 1–7. Localization of different developmental forms of *Sphaerospora* spp. (arrows) in carp. 1, 2: spores and sporoblasts of *S. renicola* in kidney (kidney sections). 1—in the tubular lumen; 2—inside the epithelial cell. 3–5: spores and sporoblasts of *S. molnari* in gills (longitudinal sections). 3, 4—in the epithelium; 5—outside gill tissue, in mucus. 6, 7: amoeboid plasmodia in gills (longitudinal sections). Scale bars: Figs. 1–5 = 15 µm; Fig 6 = 30 µm; Fig. 7 = 15 µm.





Sphaerospora occurs. The presence of these forms in kidney of fish of both C groups may indicate, that the "abortive intracellular cycle" occurring, according to Lom and Dyková (1992) in winter in the life cycle of *Sphaerospora renicola*, is also an attribute of the life cycle of *S. molnari*.

Sphaerosporosis is considered as "summer disease" (Molnar 1979; Waluga and Budzyńska 1981; Waluga 1983; Antychowicz 1985). In our material the symptoms of sphaerosporosis were noticed in carp already in spring. Nevertheless this material supports the view of the importance of temperature for the development of the disease. It concerns especially the production of spores, and their pathological effect on surrounding tissues. Voronin and Chernycheva (1993) observed unfavourable influence of high temperature on the severity of swim bladder inflammation caused by trophic forms of *S. renicola* in carp fry. In our material, examined in spring, these symptoms were manifested only sporadically.

The presence of extrasporogonic forms in peripheral blood was in our material accompanied by numerous pathological changes in both erythrocytes and leucocytes. According to Własow (1989) the great number of these forms (C-protozoans) in fish blood can act like immunodepressive agent and cause lymphopaenia in fish. Molnar (1993) emphasised that such "late parasite stages" can persist in blood for months and can be responsible for the recurrence of strong disease. Therefore it seems reasonable to examine blood smears during routine carp health control after overwintering for the detection of early spring sphaerosporosis.

Figs. 8–16. Pathological changes in the tissues of carps affected by *Sphaerospora* spp (arrows). 8—longitudinal section of gill, showing numerous amoeboid plasmodia: note necrotic changes of marginal fragments and fusion of secondary lamellae. 9, 10—sections of kidney, showing the spore of *S. molnari* (10) and amoeboid plasmodia (11) in the tubular lumen, accompanied by necrotic changes. 11—renal smear, showing strong eosinophilia. 12, 13, 15, 16—peripheral blood smears, showing extrasporogonic forms and some changes in erythrocytes. 14—kidney imprint, showing extrasporogonic form and lymphoid cells. a—amitotic division of nucleus, e—eosinophil, er—erythroblastosis, f—fusion of the second lamellae of gill, kl—karyolysis, kr—karyorexis, ly—lymphoid cell, n—necrotic changes, p—pycnosis of nucleus, v—vacuolisation of cytoplasm. Scale bars: Fig. 8 = 100 µm; Figs. 9–16 = 10 µm.

ACKNOWLEDGEMENTS

The research supported by the grant No 6P 204 020 05 of the Polish Scientific Researches Committee.

The authors wish to thank Miss Elżbieta Ziomek for her excellent technical assistance.

REFERENCES

- Antychowicz J.**, 1984: Sferosporoza nerek karpi. [Kidney sphaerosporosis of carp]. *Med. Wet.*, **40**, 12: 725–727. (In Polish).
- Antychowicz J.**, 1985: Sferosporoza skrzeli i skóry karpi. [Sphaerosporosis of carp gills and skin]. *Med. Wet.*, **41**, 4: 216–220. (In Polish).
- Dyková I., J. Lom**, 1988: Review of pathogenic myxosporeans in the intensive culture of carp (*Cyprinus carpio*) in Europe. *Folia Zool.*, **35**: 289–307.
- El-Matbouli M., T. Fisher-Scherl, R.W. Hoffmann**, 1992: Present knowledge on the life cycle, taxonomy, pathology, and therapy of some *Myxosporea* spp. important for freshwater fish. *Ann. Rev. Fish Diseases*, **2**: 367–402.
- El-Matbouli M., R.W. Hoffmann, R. Kern**, 1995: *Sphaerospora coregoni* n. sp. (Myxosporea: Sphaerosporidae) observed in the kidney of whitefish (*Coregonus lavaretus*). *Bull. Eur. Ass. on Fish Pathol.*, **15**: 132–133.
- Fischer-Sherl T., M. El-Matbouli, R.W. Hoffmann**, 1986: A new *Sphaerospora* sp. in brown trout (*Salmo trutta* m. *fario*) in Germany. *Bull. Eur. Ass. Fish Pathol.*, **6**: 16–19.
- McGeorge J., Ch. Sommerville, R. Wotten**, 1996: Transmission experiments to determine the relationship between *Sphaerospora* sp. from Atlantic salmon, *Salmo salar*, and *Sphaerospora truttae*: a revised species description for *S. truttae*. *Folia Parasitol.*, **43**: 107–116.
- Grabda J.**, 1971: Katalog Fauny Pasożytniczej Polski. II. Pasożyty Kragłoustych i Ryb. [Catalogue of the parasitic fauna of Poland. II. Parasites of cyclostomates and fish]. PWN, Warszawa-Wrocław. (In Polish).
- Grossheider G., W. Körtling**, 1993: Experimental transmission of *Sphaerospora renicola* to common carp *Cyprinus carpio* fry. *Diseases of Aquatic Organisms*, **16**: 91–95.
- Kozicka J.**, 1951. Pasożyty i stan zdrowotny leszcza - *Abramis brama* L. w Wiśle koło Warszawy. [Parasites and health of bream in Vistula river near Warsaw]. *Rocz. Nauk Rol.*, **58**: 341–372. (In Polish).
- Lom J., I. Dyková**, 1992: Protozoan Parasites of Fishes. Developments in Aquaculture and Fisheries Science, **26**, Elsevier, Amsterdam-London-New York-Tokyo.
- Lom J., I. Dyková, Z. Svobodová, J. Zajíček**, 1989: Protozoární paraziti užitkových ryb. [Parasitic protozoans of commercial fish]. Český rybářský svaz ve Státním zemědělském nakladatelství, Praha. (In Czech).
- Molnar K.**, 1979: Gill sphaerosporosis in the common carp and grasscarp. *Acta Vet. Hungar.*, **27**: 99–113.
- Molnar K.**, 1980: Renal sphaerosporosis in the common carp *Cyprinus carpio* L. *J. Fish Diseases*, **3**: 11–19.
- Molnar K.**, 1993: Recent achievement in the chemotherapy of myxosporean infection of fish. *Acta Vet. Hungar.*, **41**: 51–58.
- Pojmańska T., M. Chabros**, 1993: Parasites of common carp and three introduced cyprinid fish in pond culture. *Acta Parasitol.*, **38**: 101–108.

- Voronin V.N., N.B. Chernycheva, 1993: An intracellular gill parasite as the possible causative agent of mortality during swim-bladder inflammation in common carp, *Cyprinus carpio* L. J. Fish Diseases, 16: 609–611.
- Waluga D., 1983: Wstępne badania nad sferosporozą karpi. [Preliminary studies of carp sphaerosporosis]. Med. Wet., 39: 399–403. (In Polish).
- Waluga D., H. Budzyńska, 1980: Inwazja sporowca *Sphaerospora carassii* przyczyną masowych śnięć karpi. [Infection of *Sphaerospora carassi*, the causative agent of mass carp death]. Gosp. Ryb., 8: 5–7. (in Polish).
- Waluga D., H. Budzyńska, 1981: Uwagi o sferosporozie u karpi i jej zwalczaniu. [Sphaerosporosis of carp, and its control]. Gosp. Ryb., 6: 8–10. (In Polish).
- Waluga D., T. Własow, 1988: Występowanie pasożytów leszcza (*Abramis brama* L.), płoci (*Rutilus rutilus* L.) i sandacza (*Stizostedion lucioperca* L.) we Włocławskim Zbiorniku Zaporowym na rzece Wiśle. [The occurrence of parasites in bream (*Abramis brama* L.), roach (*Rutilus rutilus* L.) and perch-pike (*Stizostedion lucioperca* L.) in Włocławek dam reservoir on the Vistula river]. Wiad. Parazytol., 34: 65–75. (In Polish).
- Własow T., 1989: Haematology of carp infected by C-blood Protozoa. Proceedings 2-nd National Ichthyohaematological Conference, Litomyšl, 28–29 Nov., 1989. Česká Rada ČSVVYS, Praha: 113–118.
- Yeney Zs., G. Yeney, 1995: Recent achievement in studies on diseases of common carp (*Cyprinus carpio* L.). Aquaculture, 129: 297–420.

Teresa POJMAŃSKA, Teresa WŁASOW, Piotr GOMUŁKA

SPHAEROSPORA RENICOLA I S. MOLNARI ORAZ WIOSENNA SFEROSPOROZA KARPI

STRESZCZENIE

W młodych karpach, badanych po pierwszym zimowaniu, zidentyfikowano na podstawie budowy spor dwa gatunki Myxosporae: *Sphaerospora renicola* Dyková et Lom, 1982 oraz *S. molnari* Lom, Dyková, Pavlaskova et Grupcheva, 1983. Oba gatunki zostały po raz pierwszy zarejestrowane w Polsce. Opisano lokalizację różnych form rozwojowych *Sphaerospora* w rybach, a także różnice w częstości ich występowania, związane z temperaturą wody w zimochowach. Różnice te były szczególnie wyraźne w odniesieniu do spor. Opisano symptomy wiosennej (nietypowej) sferosporozy i zasugerowano celowość przeprowadzania badań w kierunku sferosporozy w trakcie rutynowej wiosennej kontroli stanu zdrowotnego ryb po zimowaniu.

Received: 11 August 1997

Author's address:

Teresa Pojmańska PhD, DSc, ProfTit
W. Stefański Institute of Parasitology,
Polish Academy of Sciences
Twarda 51/55, 00-818 Warszawa, Poland