

Regina ZBANYSZEK

Histochemistry

**A HISTOCHEMICAL STUDY OF ACID MUCOPOLYSACCHARIDES
IN THE GILLS OF THE EEL *ANGUILLA ANGUILLA* (L.)**

**BADANIA HISTOCHEMICZNE MUKOPOLISACHARYDÓW KWAŚNYCH
W SKRZELACH WĘGORZA *ANGUILLA ANGUILLA* (L.)**

**Institute of Ichthyology
Department of Fish Physiology**

In this histochemical study the occurrence and distribution of acid mucopolysaccharides in the gills of the eel *Anguilla anguilla* (L.) have been determined and their differentiation into acid mucopolysaccharides containing carboxyl groups and those containing sulphate groups has been carried out.

Acid mucopolysaccharides (AMPS), which include, among other compounds, hyaluronic and chondroitin-sulphuric acids, play an important part in many physiological and pathological processes. Quantitatively, they constitute the main component of cartilage and, performing the task of a binding agent, exert an influence on the processes of tissue regeneration, the regulation of electrolytes and water in extracellular fluids, the resistance of tissues in infection, etc. The participation of acid mucopolysaccharides in numerous processes is connected with their polyanionic nature, which is in turn related to the presence of carboxyl and sulphate groups (Brimacombe, 1964).

Neutral and acid mucopolysaccharides were found in the mucus cells of the branchial epithelium in *Mugil cephalus* (L.) and *Anoptichthys jordani* (Zaccone, 1972) and in *Tilapia schirana chilwae* (Cackson, 1970).

Scanty literature on this subject shows that the main component of mucus secreted by mucus cells in the gill epithelium are mucopolysaccharides (Porcelli and Novell, 1970; Capuro, 1967).

Studying mucus cells in the eel gills, Colombo (1960) obtained a PAS positive reaction in them and a PAS negative reaction in acidophil cells.

In view of the important part played by AMPS in physiological processes the present study has been designed to determine their distribution in the eel gills by histochemical methods, differentiating them into AMPS containing carboxyl groups and those with sulphate groups.

MATERIAL AND METHOD

The study was carried out on eels, 55–70 cm in length, 450–700 g in weight and 6–10 years of age, caught in the Szczecin Firth. Dissected gills were immediately placed in fixatives, namely, in buffered 10% formalin, Zenker's fluid and Carnoy's fluid. Fixed material, in the form of paraffin blocks, was sectioned at 5–10 μm .

The PAS method acc. to McManus with Schiff's reagent and also with Alcian blue was used to detect mucopolysaccharides. In the PAS method oxidation was carried out with periodic acid dissolved in icy acetate acid. Assays for glycogen were made by the PAS method following diastase digestion and by staining with Best's carmine. Techniques with Alcian blue and Astra blue and for metachromatic reaction with toluidine blue were employed to detect acid mucopolysaccharides. In staining for acid mucopolysaccharides, Astra blue was used in a solution at pH 0.25 and 5.5 and toluidine blue at pH 3.5, 4.5 and 6.5. In differentiating AMPS, one of the methods for staining them was used after methylation as a control procedure.

RESULTS AND THEIR DISCUSSION

In the present study a strong PAS positive reaction was observed in the epithelial layer of the free margins of gill filaments and in mucus cells situated in the top portion of the gill filament and also at the base of lamellae. The cartilaginous tissue, especially its ground substance also exhibited an intense PAS positive reaction. The remaining basement membrane was weakly PAS positive. The presence of a PAS positive reaction in the epithelial layer and in the cartilaginous tissue would indicate the occurrence of neutral mucopolysaccharides or glycogen in these places. The method with Best's carmine used for glycogen gave a negative result. The removal of glycogen by treatment with diastase did not decrease the intensity of staining. The PAS positive reaction persisting after digestion with diastase may represent a neutral mucopolysaccharide or a carbohydrate-protein complex (Cockson, 1970).

The method with Alcian blue + PAS intensely stains both the mucus cells and cartilage blue, while in the basement membrane it gives only a slight reaction. The blue coloration would point to the occurrence of the acid mucopolysaccharides. The other elements of the gills stained pale pink, which may indicate neutral mucopolysaccharides.

A list of staining reactions for acid mucopolysaccharides is given in Table 1.

Table 1

List of staining reactions for acid mucopolysaccharides in the gills
of the eel *Anguilla anguilla* (L.)

Method	Mucus cells	Cartilaginous tissue	Basement membrane
Alcian blue + PAS	++++	+++	++
Alcian blue	++++	+++	++
Astra blue (pH 0.25)	----+	++++	++
Astra blue (pH 5.5)	++++	+++	+ -
Toluidine blue (pH 4.5)	++++	+++	+ -

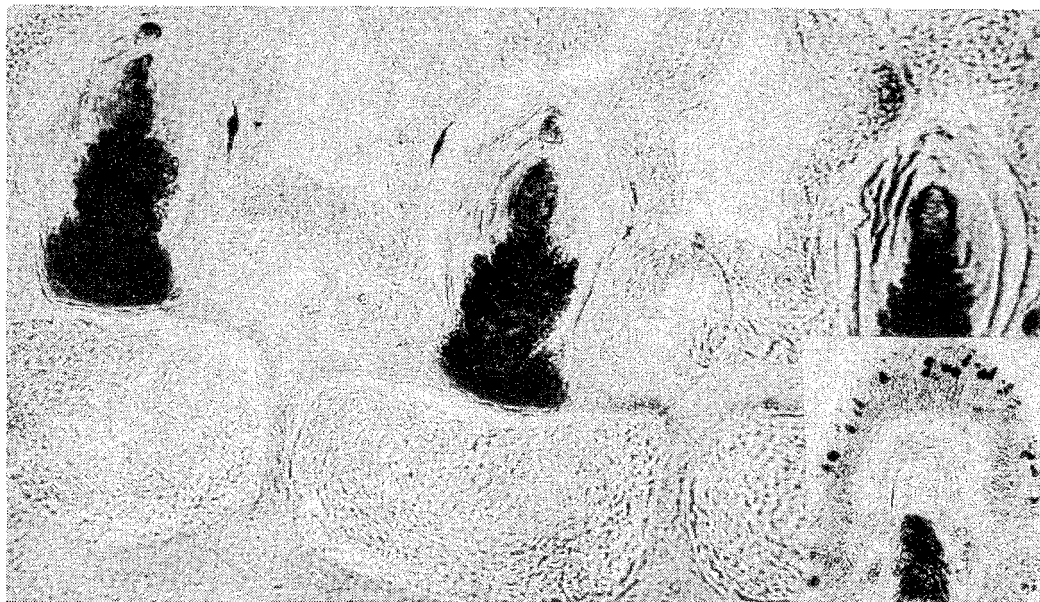++++ very strong reaction

+++ strong reaction

++ weak reaction

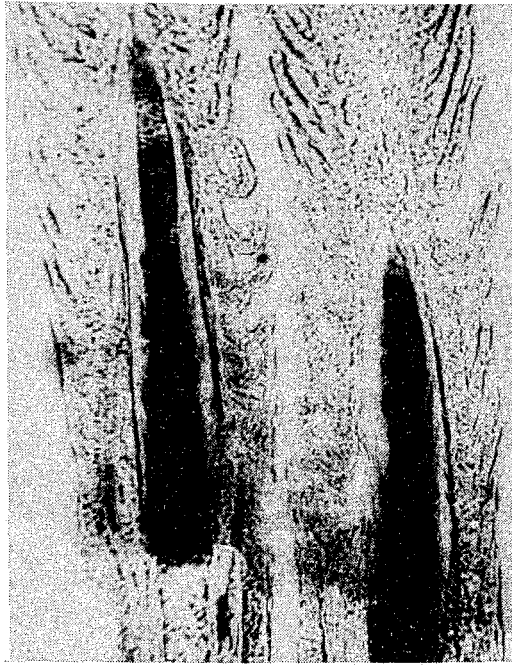
+ - very weak reaction

----+ slight reaction



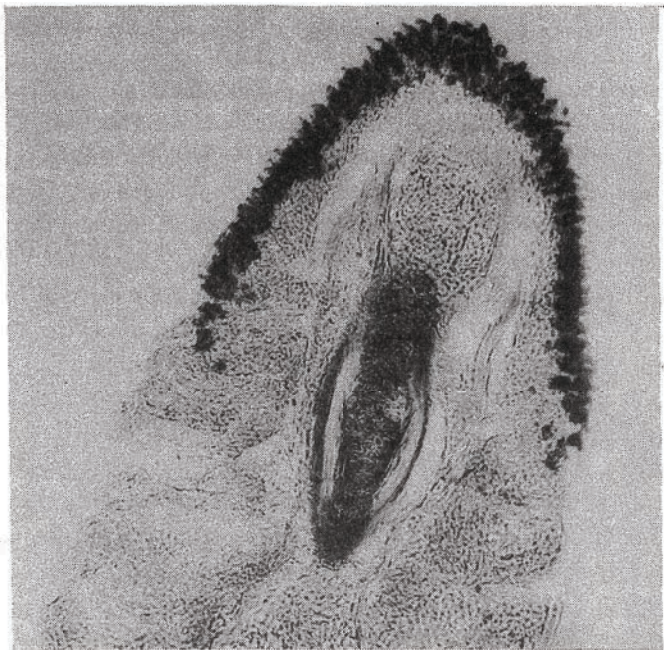
Phot. 1. A cross-section at the base of gill filaments, from the afferent vessel side. Positive reaction for acid mucopolysaccharides (AMPS) in the cartilage. Astra blue at pH 0.25. x 600.

The small micrograph inserted in the bottom right-band corner shows a cross-section through a gill filament. Positive reaction for AMPS in cartilage and infrequent mucus cells. Astra blue at pH 0.25



Phot. 2. A longitudinal section of eel gill filaments. Positive reaction for AMPS in cartilage. Astra blue at pH 0.25. x 120

The use of the method with Astra blue at pH 0.25 for acid mucopolysaccharides (AMPS) gave a strong reaction only in the cartilage (Phot. 1 and 2). In very few cases infrequent mucus cells in the epithelium stained very pale blue. Astra blue belongs to phthalocyanin stains and, according to the concentration of hydrogen ions, it allows the distinction between hyaluronic acid without sulphate groups and chondroitin-sulphuric acid containing components of oxygen-sulphure combination (Kelly, 1956). Hyaluronic acid does not dissociate at a low pH and since dissociation is a prerequisite of staining with the Astra dye, it may be inferred whether or not hyaluronic acid is present. The constant of dissociation of chondroitin-sulphuric acid is higher than that of hyaluronic acid and consequently the former at a very low pH (0.25) still gives a staining reaction with Astra blue, whereas the latter shows no staining reaction at so low pH. Staining with Astra blue at pH 0.25, applied in the present study, demonstrated a very weak positive reaction very rarely and even then in a very small number of mucus cells. On the other hand, it gave a very strong positive reaction in the cartilage. This would indicate the absence of chondroitin-sulphuric acid from the mucus cells or the occurrence of its only very small amounts in them. The positive reaction with Astra blue at pH 0.25 in the cartilage of the gill filaments and its almost complete lack in the mucus cells suggest however that the mucus cells contain a slight amount of chondroitin-sulphuric acid. This would be supported by the fact that the staining with Astra blue at pH 5.5 gave a positive



Phot. 3. A cross-section of an eel gill filament. Positive reaction for AMPS in cartilage and strongly positive in numerous mucus cells. Astra blue at pH 5.5. x 450



Phot. 4. A cross-section through an eel gill filament. Positive reaction for AMPS in the mucus cells of the branchial epithelium. Toluidine blue. x 1200

reaction in the cartilage and a strongly positive reaction in the mucus cells (Phot. 3). Similar results were obtained with Alcian blue at pH 2.5.

B-metachromasia was obtained in the mucus cells of the gill epithelium and in the cartilage stained with toluidine blue at pH 3.5, 4.5 and 6.5 (Phot. 4). The intensity of staining increased with pH, being the lowest at pH 3.5. In the mucus cells b-metachromasia sometimes passed into metachromasia. According to Lison (1935), most substances that stain metachromatically, e.g. chondroitin-sulphuric acid, contain groups SO_3 and if these groups have been removed, metachromasia disappears. He thinks that groups SO_3 induce metachromasia when they are bound to macromolecules. Low-molecular sulphonic compounds show no metachromasia and so a fall in molecular weight to less than 5.000 diminishes the possibility of the detection of metachromasia.

It should therefore be supposed that both acid mucopolysaccharides containing carboxyl groups and those containing sulphate groups may occur in mucus cells, the amount of the latter being relatively small. The phenomenon of metachromasia observed in the mucus cells of the gill epithelium is probably connected with the activity of ions.

Acid mucopolysaccharides presumably play an important part in the process of transport of ions, being selectively permeable for them.

CONCLUSIONS

1. In the eel gills acid mucopolysaccharides (AMPS) occur in the mucus cells of the epithelial layer, in the cartilage of gill filaments and, in a small amount, in the basement membrane.
2. The mucous cells contain AMPS with carboxyl groups and, to a smaller extent, those with sulphate groups, which, on the other hand, prevail in the cartilage.
3. Neutral mucopolysaccharides have been found to be present in the gill epithelium.
4. No glycogen was detected in the mucus cells of the gill epithelium.

ACKNOWLEDGMENTS

I wish to express my deep gratitude to Prof. R. Węgrzynowicz for valuable instructions given me during this study.

REFERENCES

- Brimacombe J.S., Webber J.M., 1964: Mucopolysaccharides chemical structure distribution and isolation (B.B.A. Library). American Elsevier Publishing Co: New York 17.
- Capuro S., 1967: L'Apparato respiratorio dei pesci nella ricerca istochimica. Studi in un Teleosteo, Riv. Istoch. norm. pat. 13: 255-305.
- Cockson A., 1970: Some polysaccharides in the mucous cells in the gills of *Tilapia Shirana* Chilwae Trewavas (Pisces Cichlidae). Cellule. 68, 2: 207-210.
- Colombo G., 1960: Ricerche istochimiche sulle funzione osmoregolatrice delle branchie nelle anguilla europee (*Anguilla anguilla* L.). Arch. Ocean. Limnol. 12: 117-130.

- Kelly J., W., 1956: The metachromatic reaction. *Protoplazmatologia* 2-D2. Wien, 1956.
- Porcelli F., Novell G., 1970: Osservazioni istomorfologiche istochimiche sulle cellule mucipare delle branchie nello sciluppo di Salmo fario. *Arch. ital. anat. e embriol.* 75, 3-4: 157-170.
- Lison L., 1935: *Histochemie Animale*, Gauthier, Paris 1936. *Arch. Biol.* 46: 599.
- Zaccone G., 1972: Comparative histochemical investigations on the mucous cells of the branchial epithelium of *Mugil cephalus* L. and *Anoptichthys jordani* HUBBS and INNES. *Acta histochem.* 44: 106-114.

Translated: mgr Jerzy Zawadzki

R. Zbanyszek

BADANIA HISTOCHEMICZNE MUKOPOLISACHARYDÓW KWAŚNYCH W SKRZELACH WĘGORZA *ANGUILLA ANGUILLA* (L.)

Streszczenie

Przeprowadzono badania histochemiczne mukopolisacharydów kwaśnych w skrzelach węgorza *Anguilla anguilla* (L.) poławianego w Zalewie Szczecińskim. W wyniku przeprowadzonych badań stwierdzono występowanie mukopolisacharydów kwaśnych w komórkach śluzowych warstwy nabłonkowej, w chrząstce listków skrzelowych oraz w błonie podstawowej. W komórkach śluzowych przeważały mukopolisacharydy kwaśne z grupami karboksylowymi, podczas gdy w chrząstce dominowały mukopolisacharydy kwaśne z grupami siarczanowymi jak kwas chondroitynosiarkowy.

ГИСТОХИМИЧЕСКИЕ ИССЛЕДОВАНИЯ КИСЛЫХ МУКОПОЛИСАХАРИДОВ В ЖАБРАХ УГРЯ *ANGUILLA ANGUILLA* (L.)

Р е з ю м е

Автором проведены гистохимические исследования кислых мукополисахаридов в жабрах угря *Anguilla anguilla* (L.), пойманного в Щецинском заливе. В результате исследований установлено наличие кислых мукополисахаридов в слизистых клетках эпителиального слоя, в хряще жаберных пластинок и в основной оболочке. В слизистых клетках преобладали кислые мукополисахариды с карбоксильными группами, в то время как в хряще доминировали кислые мукополисахариды с сульфатными группами, как, например, хондроитинсерная кислота.

Address:

Dr Regina Zbanyszek

Instytut Ichtiologii AR

71-550 Szczecin, ul. Kazimierza Królewicza 4

Polska - Poland

Received: 5 VIII 1975 r.