

Co-occurrence of lung adenocarcinoma and pulmonary fibrosis in a patient: A comprehensive case study and review of existing literature on the successful utilization of nintedanib

Tanya Zlatanova¹, Jeliuzko Arabadjiev¹

¹ *Acibadem City Clinic UMHAT Tokuda, Sofia, Bulgaria*

Corresponding author: Tanya Zlatanova (jarabadjiev@gmail.com)

Received 29 August 2023 ♦ Accepted 18 September 2023 ♦ Published 13 October 2023

Citation: Zlatanova T, Arabadjiev J (2023) Co-occurrence of lung adenocarcinoma and pulmonary fibrosis in a patient: A comprehensive case study and review of existing literature on the successful utilization of nintedanib. *Pharmacia* 70(4): 1127–1134. <https://doi.org/10.3897/pharmacia.70.e111820>

Abstract

Both lung carcinoma and idiopathic pulmonary fibrosis (IPF) have an adverse prognosis, and the co-existence of both diseases is not uncommon. We introduce a clinical case involving a patient diagnosed with concurrent occurrences of lung adenocarcinoma and IPF. The patient underwent a therapeutic regimen comprising the administration of docetaxel in conjunction with nintedanib. This treatment approach was followed by the sustained utilization of maintenance nintedanib over an extended duration, leading to substantial enhancements in the patient's quality of life. Furthermore, we discuss the few therapeutic options concerning this clinical challenge and possible future therapeutic options.

Keywords

Lung carcinoma, idiopathic pulmonary fibrosis, nintedanib

Introduction

IPF is an idiopathic interstitial pneumonia with an unknown origin with specific histomorphological and radiological features (Saulea et al. 2018). It is a relatively rare fibrotic disease, but the incidence is rising mainly due to better diagnostic methods and population aging (Lederer and Martinez 2018). The prognosis of the disease remains poor, with a median survival of 3–5 years after diagnosis (Buendía-Roldán et al. 2017). Approximately 10% of patients with IPF develop lung cancer, mainly of squamous cell histology, and the combination leads to even worse

outcomes (Buendía-Roldán et al. 2017). In addition, lung cancer is the leading cancer-related cause of death worldwide, according to GLOBOCAN, accounting for more than 1,7 million deaths for both sexes for 2020 (Sung et al. 2021). The exact pathophysiological mechanisms for developing lung cancer in IPF patients remain unclear, although both diseases share some common genetic alterations and environmental risk factors, primarily smoking (Sung et al. 2021). The concurrent treatment of IPF and lung cancer is still challenging, both in the early and advanced stages. Nintedanib is a small molecule tyrosine kinase inhibitor that targets the receptor tyrosine kinases

platelet-derived growth factor receptor (PDGFR); fibroblast growth factor receptor (FGFR), vascular endothelial growth factor receptor (VEGFR); and FLT3 (Wollin et al. 2015). The investigators initially designed nintedanib as an anti-angiogenic drug for cancer indications. However, phase III clinical studies subsequently confirmed the role of nintedanib in treating IPF due to its anti-fibrotic and anti-inflammatory activity (Wollin et al. 2015). In the INPULSIS trial, patients with IPF experienced reduction in lung – function decline and acute exacerbations (Richeldi et al. 2014). The phase III LUME- Lung 1 clinical study investigated the efficacy and safety of nintedanib plus docetaxel in patients with stage IIIB/IV recurrent NSCLC progressing after first-line chemotherapy (Reck et al. 2014). The authors concluded that adding nintedanib to docetaxel is an effective second-line treatment for these patients, especially those with adenocarcinoma (Reck et al. 2014). Recently, some publications have speculated upon a possible protective effect of nintedanib in radiation-induced lung toxicity, which could be one of the severe clinical problems in patients receiving definitive radiotherapy for lung cancer (Dy et al. 2021).

Materials and methods

Limited data in the literature focuses on the treatment with nintedanib for patients with concomitant lung cancer and IPF. We used the PubMed and Google Scholar databases to identify only a few clinical cases and isolated clinical trials on this topic. Our clinical case illustrates the beneficial effect of nintedanib for both lung cancer and IPF and demonstrates a prolonged clinical advantage for the patient. Here, we present the medical history, physical examination, and results from the treatment. The treatment was conducted under the Metastatic non-small cell lung cancer: ESMO Clinical Practice Guidelines for diagnosis, treatment and follow-up (Planchard et al. 2018) and the current Pharmacotherapeutic guide in Bulgaria, after thorough discussion at Multidisciplinary Tumor Board of ACC Tokuda Hospital.

Patient presentation

A 54-year-old male presented to the clinic with enlarged lymph nodes in his neck and right armpit. He was complaining of high temperature (38 °C) and fatigue. The patient was prescribed the antibiotic cefixime for ambulatory treatment, but no significant improvement occurred after a week. During the initial clinical examination, he displayed sense, slightly movable, and painless lymph nodes in his neck and supraclavicular area and enlarged lymph nodes in both armpits and the groin region. His Eastern Cooperative Oncology Group performance status (ECOG PS) score was rated as 1, and his laboratory results fell within the normal range.

The patient used to be a smoker with a 40 pack-year smoking history. However, he quit smoking 15 years ago. He is currently employed as a driver. The patient had mild

and well-managed hypertension and no known family history of cancer.

Physical examination and imaging methods

The initial chest computed tomography (CT) scan, conducted on December 29, 2020 (depicted in Fig. 1 [A and B]), exhibited bilateral supraclavicular, right axillary, and mediastinal lymphadenopathy. Furthermore, it demonstrated bilateral interstitial lung parenchymal alterations indicative of fibrotic-phenotype interstitial lung disease. In spite of the aforementioned characteristics, the individual did not present prevalent indications, such as inexplorable dyspnea upon exertion or continual non-productive cough. Despite recommendations advocating for further invasive measures like a pulmonary biopsy to explore the underlying causes of IPF, the patient opted against such interventions, displaying a keenness to commence therapeutic interventions promptly. During this phase, consultation with a pulmonologist was not sought.

This clinical scenario presented a perplexing diagnostic predicament, initially arousing suspicion of lymphoproliferative ailment. Following collaboration with a hematologist, the patient was admitted to the thoracic surgery division for a biopsy. Subsequently, a right cervicotomy was executed, leading to the excision of an enlarged right cervical lymph node.

The histopathological analysis of the biopsy specimen unveiled a metastatic mass originating from lung adenocarcinoma. The tumor exhibited positive immunostaining for CK7, TTF, p63, and ALK (without translocation). Additionally, it displayed a wild-type EGFR status and PD-L1 expression levels ranging between 42% and 45%.

Subsequent positron emission tomography (PET)/CT imaging revealed lung carcinoma and multiple enlarged lymph nodes. Initial brain magnetic resonance imaging (MRI) yielded no evidence of brain metastases. The conclusive diagnosis was established as cT1N3M1 lung adenocarcinoma, following the staging criteria outlined in the 8th edition of the American Joint Committee on Cancer manual. This diagnosis encompassed axillary lymph node involvement and solitary muscle metastasis. However, the tumor exhibited no driver gene mutations amenable to targeted therapeutic strategies.

Given these findings, the multidisciplinary tumor board recommended the initial treatment regimen. This regimen comprised carboplatin dosed at an area under the curve (AUC) of 5 mg/mL per minute, pemetrexed at 500 mg/m², and a fixed dose of pembrolizumab set at 200 mg. The patient completed four cycles of this treatment protocol without incidence of grade 3–4 toxicities. Nevertheless, a grade 1 skin rash and pruritus emerged after the first cycle, classified per the Common Terminology Criteria for Adverse Events version 5.0. These symptoms resurfaced following the oral administration of an antiallergic medication.

Upon reevaluation through CT scanning on May 21, 2021 (depicted in Fig. 1 [C and D]), discernible

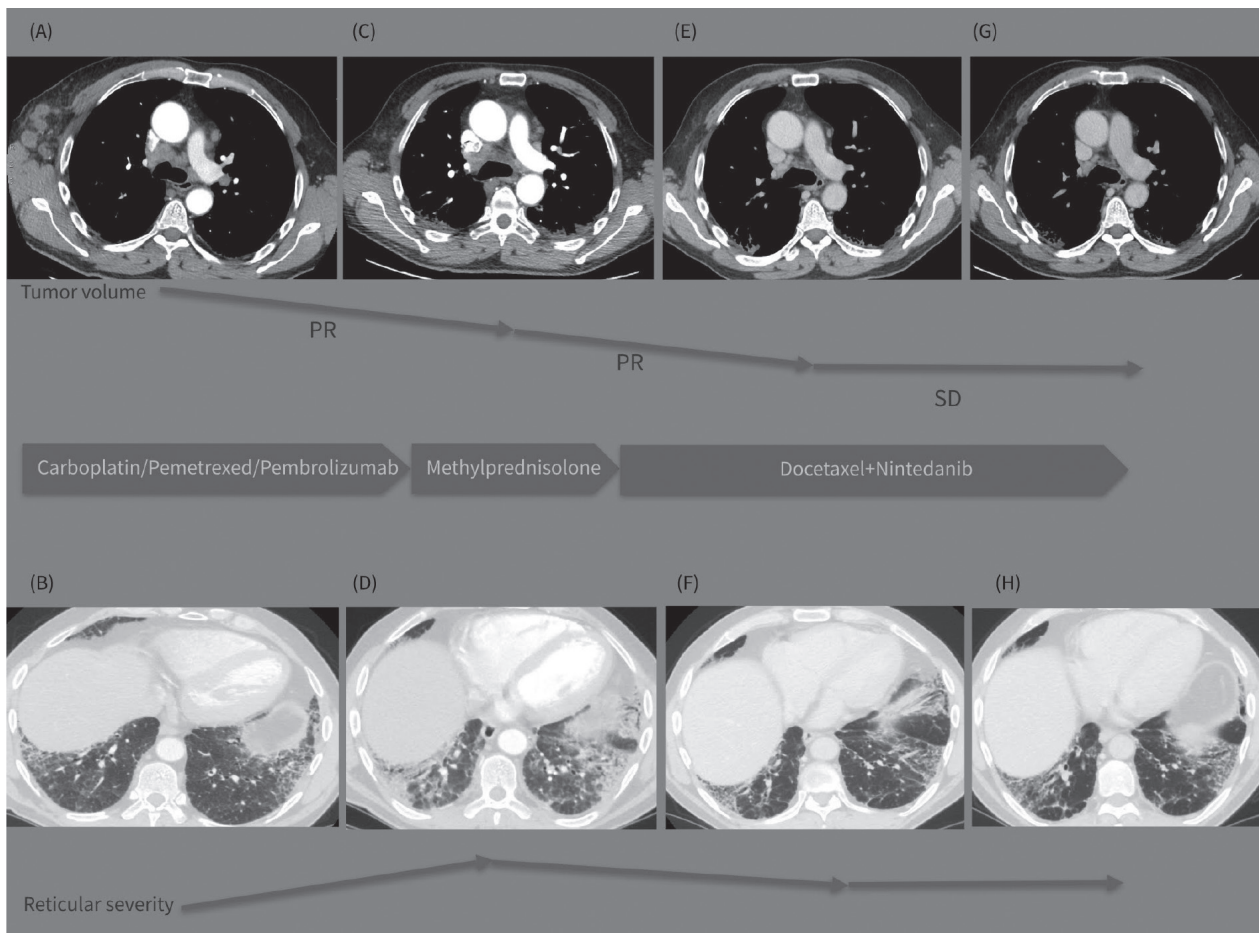


Figure 1. A–H. Graphic summary of the case.

advancements were identified regarding diminished count and mediastinal, axillary, and supraclavicular lymph node dimensions. Concurrently, a noteworthy progression in the context of interstitial lung disease accompanied by lung fibrosis was noted. This phenomenon could plausibly be ascribed to the effects of both immunotherapeutic and chemotherapeutic interventions, given that autoimmune pneumonitis constitutes a prevalent manifestation of treatment-related toxicity stemming from immune checkpoint inhibitors. The patient complained of fatigue, aggravated breathlessness, and recurrent instances of severe coughing.

Subsequently, a referral to a pulmonologist was effected to facilitate the clinical assessment of pulmonary function. After physical examination, manifestations of nail clubbing, an oxygen saturation level of 88%, and bilateral fine “Velcro” crackles upon auscultation came to light. Pulmonary function testing duly corroborated a decline in diffusion capacity, coupled with restrictive ventilatory abnormalities, as detailed in Table 1.

Results

Laboratory findings yielded results within the established normal ranges, including a C-reactive protein (CRP) level of 42.3 mg/L. The autoimmune/myositis panel also displayed adverse outcomes (serological assessment encompassing ANA-profile involving 18 antibody types and

evaluations for ANCA-MRO, PR3, GBM, and AMA M2). Consequently, the initial suspicion of a systemic connective tissue disorder, a common underlying cause of interstitial lung disease, was dismissed.

Oral corticosteroid therapy with methylprednisolone was initiated at a dose of 1 mg/kg per day. The dosage was subsequently gradually tapered, transitioning to prednisone. Following one month of corticosteroid treatment, the patient communicated notable enhancements in his clinical state, with reductions in asthenia and respiratory distress.

The therapeutic dilemma at this juncture pertained to selecting a second-line treatment approach for the patient, who had lung adenocarcinoma concomitant with an underlying interstitial lung disease that had displayed clinical exacerbation during chemotherapy and immune therapy. Deliberations involving a multidisciplinary tumor board, radiologist, and pulmonologist were undertaken to address this complex scenario. The coexistence of lung adenocarcinoma and pulmonary fibrosis prompted the consideration of suitable interventions.

In this context, the medicinal agent nintedanib emerged as a viable option due to its dual effectiveness against lung adenocarcinoma and IPF. Consequently, a second-line therapeutic regimen was initiated, encompassing intravenous infusion of 75 mg/m² docetaxel on day 1, alongside oral administration of 200 mg nintedanib twice daily from days 2 to 21, following a 3-week cycle. This course of treatment was sustained until either unacceptable adverse

Table 1. Pulmonary function tests before treatment and during follow-up.

Value	Before treatment (05/27/2021)		Follow-up on treatment (09/24/2021)		Follow-up on treatment (11/18/2021)	
	Absolute value	% predicted value	Absolute value	% predicted value	Absolute value	% predicted value
DLCO-SB	4.18 mmol/min/kPa	40.2%	4.43 mmol/min/kPa	42.7%	–	–
FVC	2.90 L	62.6%	3.29 L	71.0%	3.39 L	73.4%
FEV1	2.46 L	67.0%	2.73 L	74.3%	2.79 L	75.8%
FEV1/FVC	0.86	86.0%	0.83	83.06%	0.82	81.53%
% Sat.O2		88%		92%		94%

DLCO-SB – Single-breath diffusing capacity of the lung for carbon monoxide; FVC – Forced vital capacity; FEV1 – Forced expiratory volume in 1 second; FEV1/FVC ratio: the ratio of the forced expiratory volume in the first one second to the forced vital capacity of the lungs; Sat.O2 – Oxygen saturation.

events materialized or disease progression ensued. The choice of docetaxel and nintedanib combination therapy draws support from the efficacious outcomes observed in the context of second-line treatment for metastatic non-small cell lung cancer (NSCLC), as documented in the LUME-LUNG 1 study (Reck et al. 2014).

The patient underwent four cycles of docetaxel combined with nintedanib, administered consecutively from July 5 to September 8, 2021. After this regimen, a follow-up CT scan performed on September 23, 2021 (depicted in Fig. 1 [E and F]) unveiled a favorable response in both IPF and lung cancer. This response was marked by notable reductions in the size and quantity of mediastinal lymph nodes and substantial diminishment of consolidation zones, indicative of a partial response. Despite experiencing mild symptoms, the patient exhibited amelioration in pulmonary function (detailed in Table 1) and an enhanced quality of life, leading to a nearly complete restoration of his previously diminished physical capacity. He resumed work without manifesting any apparent adverse effects resulting from the combined treatment, except for a grade 1 peripheral neuropathy, categorized as per the Common Terminology Criteria for Adverse Events version 5.0.

A subsequent phase encompassed four cycles of docetaxel and nintedanib, administered consecutively from October 8 to December 8, 2021. During this period, a mild side effect emerged as a transient pruritic rash on the dorsal surface of the palms. This rash was effectively managed with a week-long application of 0.05% topical betamethasone cream. The

patient reported sustained enhancements in his quality of life and retained his work engagement. Notably, there was no evidence of deteriorating peripheral neuropathy.

In continuation, a subsequent follow-up CT scan conducted on December 18, 2021 (depicted in Fig. 1 [G and H]) revealed stable disease. This stability was characterized by the ongoing presence of enlarged right axillary and mediastinal lymph nodes alongside interstitial fibrosis consistent with the usual interstitial pneumonia (UIP) pattern.

The top line presents sequential CT images on mediastinal window (A, C, E, G) demonstrating the tumor volume regression during the treatment period (Dec 2020-May 2021-Sept 2021-Dec 2021).

The bottom line presents images on lung window (B, D, F, H) from the same CT examinations demonstrating the evolution of the interstitial lung abnormalities in the course of the treatment strategy changes (Dec 2020-May 2021-Sept 2021-Dec 2021).

Encouragingly, lung capacities and oxygen saturation levels displayed significant improvements, as outlined in Table 1. The patient persisted in receiving the same treatment regimen involving docetaxel and nintedanib. For further insight into the chronological sequence of treatments received, refer to Table 2.

Until March 16, 2022, the patient underwent twelve cycles of combined docetaxel and nintedanib therapy. Regular follow-up assessments indicated the patient's condition to be stable per the RECIST 1.1 criteria. In light

Table 2. Clinical timeline.

Time	Medical examination	Diagnosis and treatment evaluation	Treatment
12.29.2020 02.02.2021	Chest CT PET/CT Genetic testing: EGFR, ALK, PD-L1 Brain MRI	Lung adenocarcinoma – cT1N3M1 (axillary lymph nodes, solitary muscle metastasis) – AJCC 8 th edition	Right cervicotomy and lymph node excision
02.13.2021 04.28.2021	CT of chest, abdomen, and pelvis DLCO, FEV1	Lung cancer – PR; Substantial progression of lung fibrosis	4 cycles carboplatin/pemetrexed/pembrolizumab
05.25.2021 06.25.2021	Pulmonary function testing: DLCO, FEV1	Improvement of the pulmonary function	Corticosteroid treatment with methylprednisolone treatment 1 mg/kg with tapering of the dose
07.07.2021 09.10.2021	CT of chest, abdomen, and pelvis Pulmonary function testing: DLCO, FEV1	Lung carcinoma – PR; Pulmonary fibrosis – reduction	4 cycles docetaxel + nintedanib
10.08.2021 12.08.2021	CT of chest, abdomen, and pelvis Pulmonary function testing: DLCO, FEV1	Lung carcinoma – SD; Pulmonary fibrosis – SD	4 cycles docetaxel + nintedanib
12.08.2021 03.16.2022	CT of chest, abdomen and pelvis Pulmonary function testing: DLCO, FEV1	Lung carcinoma – SD; Pulmonary fibrosis – SD	4 cycles docetaxel+Nintedanib
04.01.2022 07.26.2023	CT of chest, abdomen and pelvis Pulmonary function testing: DLCO, FEV1	Lung carcinoma – SD Pulmonary fibrosis – SD	34 cycles Nintedanib

CT, Computed tomography; DLCO, diffusing capacity of the lungs for carbon monoxide; FEV1, Forced expiratory volume in 1 second; PR, partial response; SD, stable disease.

of experiencing peripheral neuropathy in grades 1–2, the decision was made to deescalate the treatment strategy, transitioning to a sole nintedanib regimen. The most recent CT assessment, conducted on July 26, 2023, after thirty-four cycles of nintedanib monotherapy, revealed the patient's medical status to be unchanged. The patient remains fully engaged in activities, with an ECOG PS score of 0. Nintedanib as monotherapy was well tolerated and the patient did not experience any side effects. No dose reduction was needed.

Discussion

Lung carcinoma remains the foremost in cancer-related mortality, contributing to nearly 1.8 million annual deaths as per the GLOBOCAN data for 2020 (Sung et al. 2021). In parallel, IPF constitutes a progressively debilitating pulmonary ailment characterized by an unfavorable prognosis, with a median survival of 3.8 years observed among individuals aged 65 and older in the United States (Raghu et al. 2014). Moreover, the prevalence of IPF has exhibited a gradual global rise (Raghu et al. 2016) (9), with occurrences of coexisting lung cancer among IPF patients varying within the range of 2.7% to 48% across divergent literature sources (Karampitsakos et al. 2017). This disparity underscores the imperative of identifying shared molecular pathways that underlie both disorders and the critical necessity to formulate optimized therapeutic approaches tailored to individuals confronting the dual challenge of lung cancer and IPF.

In the last decade, numerous innovative therapeutic strategies have emerged for lung cancer, encompassing immunotherapy, targeted therapy, and chemotherapy. However, the optimal course of action remains elusive when addressing patients who are confronted with the simultaneous challenge of stage IV lung cancer and accompanying IPF. A consensus has not been established concerning the most efficacious treatment strategy for this complex clinical scenario. The available dataset about chemotherapy in this context is inadequate, thus emphasizing the exigency to ascertain the most suitable therapeutic protocol that effectively addresses both afflictions.

A substantial retrospective investigation carried out in Greece spanning the period from 2011 to 2018 concentrated on examining the occurrence and therapeutic interventions associated with lung cancer within the cohort of patients diagnosed with IPF (Tzouvelekis et al. 2020). This study encompassed a cohort of 1016 individuals with IPF, sourced from eight distinct medical centers (Tzouvelekis et al. 2020). Among these subjects, there were one hundred and two instances of coexisting lung cancer detected, with chemotherapy being administered to 36.5% of these patients (Tzouvelekis et al. 2020).

Pemetrexed, a folate antimetabolite used as both a first and second-line treatment either alone or in combination with cisplatin or with carboplatin and pembrolizumab for locally advanced and metastatic lung adenocarcinoma, has been verified to entail substantial pulmonary

adversities. Kato et al. undertook a retrospective inquiry into the safety and effectiveness of pemetrexed monotherapy in patients with NSCLC, both with and without concurrent interstitial lung disease (ILD) (Kato et al. 2014). This investigation revealed a notably elevated occurrence of pemetrexed-associated pulmonary toxicity in NSCLC patients who presented with ILD compared to those without ILD (Kato et al. 2014).

Docetaxel has also been investigated as a second-line treatment for patients with platinum-refractory advanced NSCLC and coexisting ILD. Watanabe et al. found that docetaxel administered as monotherapy has poor activity and substantial risk when treating platinum-resistant NSCLC with IPF (Watanabe et al. 2015).

A separate retrospective investigation conducted at a single medical center delved into the effectiveness and safety of three distinct chemotherapy protocols – namely, carboplatin in combination with paclitaxel, carboplatin combined with docetaxel, and vinorelbine – as initial therapeutic approaches within a limited cohort of Japanese NSCLC patients simultaneously diagnosed with IPF (Watanabe et al. 2013). Within the context of this study, which involved a participant group of 21 individuals, it was observed that 16 of them received the carboplatin plus paclitaxel regimen, yielding an overall response rate of 56.3% (n=9) and a disease control rate of 87.5% (n=14) (Watanabe et al. 2013).

Within the context of the phase 3 LUME-Lung 1 clinical trial, individuals diagnosed with lung adenocarcinoma exhibited enhanced overall survival outcomes in the cohort receiving a combination of docetaxel and nintedanib, in contrast to those who were administered docetaxel in conjunction with a placebo, serving as second-line treatment for NSCLC (Reck et al. 2014). Nonetheless, this investigation did not assess the effectiveness and safety of nintedanib in individuals affected by both lung cancer and IPF (Reck et al. 2014).

Lately, a meta-analysis based on nine trials conducted between January 2000 and March 2014 suggested that the combination of nintedanib plus docetaxel as a second-line treatment in patients with NSCLC with a better efficacy compared to docetaxel or erlotinib alone (Popat et al. 2015).

The Japanese phase 3 J-SONIC trial aimed to prove the effectiveness of the combination of carboplatin and nanoparticle albumin-bound paclitaxel plus nintedanib in patients with IPF and lung cancer as first-line treatment (Otsubo et al. 2022). The study included 243 enrolled patients between May 2017 and February 2020. The primary end-point was exacerbation-free survival (EFS) which was unmet. However, the combination chemotherapy regimen was effective and tolerable, and adding nintedanib prolonged overall survival in patients with non-squamous histology (Otsubo et al. 2022).

Another smaller prospective pilot study in Japan proposed a similar design, investigating carboplatin and paclitaxel in combination with nintedanib for NSCLC patients with IPF (Makiguchi et al. 2023). Despite the small

number of patients (n=27), the authors found that adding nintedanib to this chemotherapy regimen might be feasible. However, the primary endpoint of incidence of treatment-related acute exacerbation of IPF within eight weeks was not met (Makiguchi et al. 2023).

We identified five publications regarding nintedanib treatment in patients with coexisting IPF and NSCLC using a PubMed and Google Scholar database search (Fukunaga et al. 2018; Yamakawa et al. 2019; Shiratori et al. 2020; Kai et al. 2021; Dabholkar et al. 2022). One patient was an active smoker, while the others were former smokers. Four patients were males, aged 69–82 years, with stage I to IV NSCLC; one was female, 78, with stage IIIB lung cancer. One of the four patients had unknown histology, three had histology of squamous cell carcinoma, and one had lung adenocarcinoma.

In a specific clinical case, nintedanib was administered as the principal therapeutic intervention for idiopathic pulmonary fibrosis (IPF) at an initial dose of 300 mg/day, which was subsequently modified to 200 mg/day due to the observed modest impairment in liver function (Fukunaga et al. 2018). During the continuous monitoring of IPF progression, the identification and subsequent surgical removal of an early-stage squamous carcinoma of the lung occurred (Fukunaga et al. 2018). The authors inferred that nintedanib's multifaceted mechanisms of action contributed to its simultaneous hindrance of the progression of both IPF and the concomitant pulmonary carcinoma (Fukunaga et al. 2018).

The other four clinical cases are centered on managing non-resectable NSCLC in conjunction with IPF. In the clinical case report authored by Shiratori et al., a male patient afflicted with advanced NSCLC and IPF underwent a series of three consecutive lines of combined chemotherapy, encompassing docetaxel in combination with ramucirumab during the second-line therapy phase (Shiratori et al. 2020). Owing to the advancement of lung cancer and the aggravation of IPF, the patient's treatment regimen was ultimately transitioned to the best supportive care, with subsequent administration of nintedanib as a monotherapy for IPF, prescribed at 150 mg twice daily (Shiratori et al. 2020). Approximately one month following the commencement of nintedanib treatment, the authors documented a partial regression in the primary tumor and pleural dissemination without the manifestation of noteworthy severe adverse events (Shiratori et al. 2020).

Kai and colleagues exhibited a case where an 82-year-old male patient with stage IV non-small cell carcinoma displayed a state of partial remission while avoiding any deterioration in his IPF condition (Kai et al. 2021). The patient's treatment encompassed the best supportive care in conjunction with nintedanib administered at an initial 100 mg twice daily, subsequently escalated to 150 mg twice daily (Kai et al. 2021).

In the clinical scenario outlined by Yamakawa et al., the investigators proposed that augmenting immune checkpoint inhibitors with nintedanib could forestall instances of drug-triggered pneumonitis or acute escalations of IPF (Yamakawa et al. 2019). In this instance, the patient

underwent four successive lines of anticancer therapy but encountered drug-induced pneumonitis in response to pembrolizumab and atezolizumab. The incorporation of nintedanib, administered at a dosage of 200 mg/day alongside atezolizumab, facilitated the recommencement of immune checkpoint inhibitors without exacerbating the drug-induced pneumonitis in a case characterized by the coexistence of IPF and lung cancer (Yamakawa et al. 2019).

In a case report of Dabholkar et al., a patient with stage III lung adenocarcinoma and IPF was treated initially with chemotherapy and had a subsequent treatment with nintedanib alone for IPF (Dabholkar et al. 2022). The treatment with the antiangiogenic multikinase inhibitor led to further tumor regression and IPF stability (Dabholkar et al. 2022).

This study presents a clinical case featuring a male patient affected by advanced NSCLC in conjunction with a concomitant, initially asymptomatic IPF. In an ideal scenario, a comprehensive immunogenic evaluation would have been conducted to rule out the autoimmune origins of interstitial lung fibrosis. Despite the absence of testing for myositis-associated autoantibodies, it is plausible that myopathic inflammatory myopathy could have contributed to the high-resolution CT (HRCT) pattern, notwithstanding the lack of ANA reactivity (Marie et al. 2002). This limitation underscores our investigation.

As part of our intervention, we administered first-line combined chemoimmunotherapy comprising standard dosages of carboplatin, pemetrexed, and pembrolizumab. The patient exhibited favorable hematological tolerance and encountered no severe adverse effects. However, after four cycles of this therapeutic regimen, a deterioration in pulmonary function, pulmonary insufficiency, and a decline in daily activities were discerned. Subsequent HRCT imaging confirmed significant interstitial lung disease (ILD) progression, characterized by extensive subpleural fibrosis zones and consolidations. In contrast, there was an observable reduction in the size and count of multiple lymph nodes. In light of the clinical, functional, and HRCT-based indications of deteriorating IPF during chemoimmunotherapy, the decision was made to discontinue the combined carboplatin/pemetrexed/pembrolizumab regimen. Subsequently, corticosteroid treatment was instituted until clinical amelioration manifested. Upon evidence of improvement, the therapeutic approach transitioned to second-line chemotherapy alongside targeted therapy involving docetaxel and nintedanib, selected for their antifibrotic and antitumor properties.

After the patient underwent eight cycles of docetaxel and nintedanib treatment, a notable enhancement in quality of life ensued, coupled with stable disease status reported in the follow-up CT scan. Furthermore, the ILD displayed stabilization, as evidenced by improved pulmonary function test results and a marked decrease in consolidation zones. The patient retained a good quality of life, unchanged pulmonary function, and stability of lung cancer through continued maintenance treatment with nintedanib monotherapy. Recently, a substantial international survey encompassing pulmonologists, thoracic

surgeons, and oncologists emphasized the need for a consensus statement regarding managing individuals affected by IPF and lung cancer (Tzouvelekis et al. 2021).

Conclusion

Our clinical case underscores the potential viability of nintedanib as a therapeutic avenue for patients with lung adenocarcinoma and concurrent IPF. Currently, there is a demand for identifying the most optimal therapeutic reg-

imen for addressing these coexisting lung conditions. To this end, prospective studies involving meticulous patient selection are imperative.

Acknowledgments

The authors would like to acknowledge the contributions of Dr. Jordan Kovachev for technical support; Galina Kirova-Nedyalkova for collecting the images of the patients, Diana Nikova for the pulmonary function tests.

References

- Buendía-Roldán I, Mejía M, Navarro C, Selman M (2017) Idiopathic pulmonary fibrosis: Clinical behavior and aging associated comorbidities. *Respiratory Medicine* 129: 46–52. <https://doi.org/10.1016/j.rmed.2017.06.001>
- Dabholkar S, Gao B, Chuong B (2022) Nintedanib-A case of treating concurrent idiopathic pulmonary fibrosis and non-small cell lung cancer. *Respirology Case Reports* 10: e0902. <https://doi.org/10.1002/rcr2.902>
- Dy GK, Prasad D, Kumar P, Attwood K, Adjei AA (2021) A Phase 2 Randomized, double-blind, placebo-controlled study evaluating nintedanib versus placebo as prophylaxis against radiation pneumonitis in patients with unresectable NSCLC undergoing chemoradiation therapy. *Journal of Thoracic Oncology* 16: e19–e20. <https://doi.org/10.1016/j.jtho.2020.11.019>
- Fukunaga K, Yokoe S, Kawashima S, Uchida Y, Nakagawa H, Nakano Y (2018) Nintedanib prevented fibrosis progression and lung cancer growth in idiopathic pulmonary fibrosis. *Respirology Case Reports* 6: e00363. <https://doi.org/10.1002/rcr2.363>
- Kai Y, Matsuda M, Fukuoka A, Hontsu S, Yamauchi M, Yoshikawa M, Muro S (2021) Remarkable response of non-small cell lung cancer to nintedanib treatment in a patient with idiopathic pulmonary fibrosis. *Thorax Cancer* 12: 1457–1460. <https://doi.org/10.1111/1759-7714.13935>
- Karampitsakos T, Tzilias V, Tringidou R, Steiropoulos P, Aidinis V, Papiiris SA, Bouros D, Tzouvelekis A (2017) Lung cancer in patients with idiopathic pulmonary fibrosis. *Pulmonary Pharmacology & Therapeutics* 45: 1–10. <https://doi.org/10.1016/j.pupt.2017.03.016>
- Kato M, Shukuya T, Takahashi F, Mori K, Suina K, Asao T, Kanemaru R, Honma Y, Muraki K, Sugano K, Shibayama R, Koyama R, Shimada N, Takahashi K (2014) Pemetrexed for advanced non-small cell lung cancer patients with interstitial lung disease. *BMC Cancer* 14: 508. <https://doi.org/10.1186/1471-2407-14-508>
- Lederer DJ, Martinez FJ (2018) Idiopathic pulmonary fibrosis. *The New England Journal of Medicine* 378: 1811–1823.
- Makiguchi T, Tanaka H, Okudera K, Taima K, Tasaka S (2023) Safety and feasibility of carboplatin and paclitaxel in combination with nintedanib for non-small cell lung cancer patients with idiopathic pulmonary fibrosis: a prospective pilot study. *Translational Lung Cancer Research* 12: 719–726. <https://doi.org/10.21037/tlcr-22-699>
- Marie I, Hachulla E, Cherin P, Dominique S, Hatron PY, Hellot MF, Devulder B, Herson S, Levesque H, Courtois H (2002) Interstitial lung disease in polymyositis and dermatomyositis. *Arthritis & Rheumatology* 47: 614–622. <https://doi.org/10.1002/art.10794>
- Otsubo K, Kishimoto J, Ando M, Kenmotsu H, Minegishi Y, Horinouchi H, Kato T, Ichihara E, Kondo M, Atagi S, Tamiya M, Ikeda S, Harada T, Takemoto S, Hayashi H, Nakatomi K, Kimura Y, Kondoh Y, Kusumoto M, Ichikado K, Yamamoto N, Nakagawa K, Nakanishi Y, Okamoto I (2022) Nintedanib plus chemotherapy for nonsmall cell lung cancer with idiopathic pulmonary fibrosis: a randomised phase 3 trial. *European Respiratory Journal* 60: e2200380. <https://doi.org/10.1183/13993003.00380-2022>
- Planchard D, Popat S, Kerr K, Novello S, Smit EF, Faivre-Finn C, Mok TS, Reck M, Van Schil PE, Hellmann MD, Peters S (2018) Metastatic non-small cell lung cancer: ESMO Clinical Practice Guidelines for diagnosis, treatment and follow-up. *Annals of Oncology* 29: iv192–iv237. <https://doi.org/10.1093/annonc/mdy275>
- Popat S, Mellemaard A, Fahrback K, Martin A, Rizzo M, Kaiser R, Griebisch I, Reck M (2015) Nintedanib plus docetaxel as second-line therapy in patients with non-small-cell lung cancer: a network meta-analysis. *Future Oncology* 11: 409–420. <https://doi.org/10.2217/fon.14.290>
- Raghu G, Chen SY, Hou Q, Yeh WS, Collard HR (2016) Incidence and prevalence of idiopathic pulmonary fibrosis in US adults 18–64 years old. *European Respiratory Journal* 48: 179–186. <https://doi.org/10.1183/13993003.01653-2015>
- Raghu G, Chen SY, Yeh WS, Maroni B, Li Q, Lee YC, Collard HR (2014) Idiopathic pulmonary fibrosis in US Medicare beneficiaries aged 65 years and older: incidence, prevalence, and survival, 2001–11. *The Lancet Respiratory Medicine* 2: 566–572. [https://doi.org/10.1016/S2213-2600\(14\)70101-8](https://doi.org/10.1016/S2213-2600(14)70101-8)
- Reck M, Kaiser R, Mellemaard A, Douillard JY, Orlov S, Krzakowski M, von Pawel J, Gottfried M, Bondarenko I, Liao M, Gann CN, Barrueco J, Gaschler-Markefski B, Novello S (2014) Docetaxel plus nintedanib versus docetaxel plus placebo in patients with previously treated non-small-cell lung cancer (LUME-Lung 1): a phase 3, double-blind, randomised controlled trial. *The Lancet Oncology* 15: 143–155. [https://doi.org/10.1016/S1470-2045\(13\)70586-2](https://doi.org/10.1016/S1470-2045(13)70586-2)
- Richeldi L, du Bois RM, Raghu G, Azuma A, Brown KK, Costabel U, Cottin V, Flaherty KR, Hansell DM, Inoue Y, Kim DS, Kolb M, Nicholson AG, Noble PW, Selman M, Taniguchi H, Brun M, Le Maulf F, Girard M, Stowasser S, Schlenker-Herceg R, Disse B, Collard HR (2014) Efficacy and Safety of Nintedanib in Idiopathic Pulmonary Fibrosis. *New England Journal of Medicine* 370: 2071–2082. <https://doi.org/10.1056/NEJMoa1402584>
- Sauleda J, Núñez B, Sala E, Soriano JB (2018) Idiopathic pulmonary fibrosis: Epidemiology, natural history, phenotypes. *Medical Sciences* 6(4): e110. <https://doi.org/10.3390/medsci6040110>

- Shiratori T, Tanaka H, Tabe C, Tsuchiya J, Ishioka Y, Itoga M, Taima K, Takanashi S, Tasaka S (2020) Effect of nintedanib on non-small cell lung cancer in a patient with idiopathic pulmonary fibrosis: A case report and literature review. *Thoracic Cancer* 11: 1720–1723. <https://doi.org/10.1111/1759-7714.13437>
- Sung H, Ferlay J, Siegel RL, Laversanne M, Soerjomataram I, Jemal A, Bray F (2021) Global Cancer Statistics 2020: GLOBOCAN estimates of incidence and mortality worldwide for 36 cancers in 185 countries. *CA: A Cancer Journal for Clinicians* 71: 209–249. <https://doi.org/10.3322/caac.21660>
- Tzouvelekis A, Antoniou K, Kreuter M, Evison M, Blum TG, Poletti V, Grigoriu B, Vancheri C, Spagnolo P, Karampitsakos T, Bonella F, Wells A, Raghu G, Molina-Molina M, Culver DA, Bendstrup E, Moggkoc N, Elia S, Cadranel J, Bouros D (2021) The DIAMORFOSIS (Diagnosis and management of lung cancer and fibrosis) survey: international survey and call for consensus. *ERJ Open Research* 7: 00529–02020. <https://doi.org/10.1183/23120541.00529-2020>
- Tzouvelekis A, Karampitsakos T, Gomatou G, Bouros E, Tzilas V, Manali E, Tomos I, Trachalaki A, Kolilekas L, Korbila I, Tomos P, Chrysikos S, Gaga M, Daniil Z, Bardaka F, Papanikolaou IC, Euthymiou C, Papakosta D, Steiropoulos P, Ntoliou P, Tringidou R, Papiris S, Antoniou K, Bouros D (2020) Lung cancer in patients with Idiopathic Pulmonary Fibrosis. A retrospective multicenter study in Greece. *Pulmonary Pharmacology & Therapeutics* 60: 101880. <https://doi.org/10.1016/j.pupt.2019.101880>
- Watanabe N, Niho S, Kirita K, Umemura S, Matsumoto S, Yoh K, Ohmatsu H, Goto K (2015) Second-line docetaxel for patients with platinum-refractory advanced non-small cell lung cancer and interstitial pneumonia. *Cancer Chemother Pharmacol* 76: 69–74. <https://doi.org/10.1007/s00280-015-2775-y>
- Watanabe N, Taniguchi H, Kondoh Y, Kimura T, Kataoka K, Nishiyama O, Kondo M, Hasegawa Y (2013) Efficacy of chemotherapy for advanced non-small cell lung cancer with idiopathic pulmonary fibrosis. *Respiration* 85: 326–331. <https://doi.org/10.1159/000342046>
- Wollin L, Wex E, Pautsch A, Schnapp G, Hostettler KE, Stowasser S, Kolb M (2015) Mode of action of nintedanib in the treatment of idiopathic pulmonary fibrosis. *European Respiratory Journal* 45: 1434–1445. <https://doi.org/10.1183/09031936.00174914>
- Yamakawa H, Oba T, Ohta H, Tsukahara Y, Kida G, Tsumiyama E, Nishizawa T, Kawabe R, Sato S, Akasaka K, Amano M, Kuwano K, Matsushima H (2019) Nintedanib allows retreatment with atezolizumab of combined non-small cell lung cancer/idiopathic pulmonary fibrosis after atezolizumab-induced pneumonitis: a case report. *BMC Pulmonary Medicine* 19: e156. <https://doi.org/10.1186/s12890-019-0920-9>