



Study of the Human Liver by Ultrasound Examination to Search for Variations of Venous Anatomy

Partha Sarathi Ain¹, Uttam Kumar Roy¹, Rudradev Meyur², Subhajit Chattopadhyay²

¹ Raiganj Government Medical College & Hospital, Raiganj, Uttardinaipur, West Bengal, India

² RG Kar Medical College and Hospital, Kolkata, India

Corresponding author: Uttam Kumar Roy, Raiganj Government Medical College & Hospital, Raiganj, Uttardinaipur, West Bengal, India; E-mail: uroy951@gmail.com

Received: 14 Nov 2020 ♦ **Accepted:** 8 Feb 2021 ♦ **Published:** 31 Oct 2021

Citation: Ain PS, Roy UK, Meyur R, Chattopadhyay S. Study of the human liver by ultrasound examination to search for variations of venous anatomy. *Folia Med (Plovdiv)* 2021;63(5):676-85. doi: 10.3897/folmed.63.e60772.

Abstract

Introduction: Knowledge about venous patterns (especially portal and hepatic venous) and their variations are extremely crucial for liver transplantation and other surgical procedures on liver. Studies have been done at national or international level on variations of hepatic venous patterns by CT or MRI or by dissection on cadaveric liver. No definitive or authentic study on this topic could be noted in electronic and print media, as well as in standard textbook. Considering low cost and noninvasive nature, we utilized ultrasonography to bridge this lacuna.

Aim: To estimate prevalence and types of anatomical variations of hepatic venous system and to determine association of among variations.

Materials and methods: It is an observational cross-sectional study where ultrasonographic evaluation of hepatic venous pattern on adult population of either sex (consecutive sampling) without any major liver disorders was done in RG Kar Medical College and data were analyzed with appropriate statistical procedures.

Results: Normal hepatic venous pattern along with normal portal venous pattern is much higher in our study, which is a unique finding. The proportion of normal portal venous pattern is more in extra hepatic bifurcation group. Variations of portal vein and normal hepatic venous pattern are more in case of intrahepatic bifurcation of portal venous branching group. Overall presence of intrahepatic bifurcation of portal vein is significantly higher than extrahepatic bifurcation.

Conclusions: This study provides an updated database for the prevalence and distribution of anatomic variations of the hepatic venous and portal venous system.

Keywords

anatomy, hepatic vein, liver transplantation, portal vein

INTRODUCTION

Globally as well as in India, the incidence of liver disorders is increasing day by day steadfastly with associated rise of the quantum of cases requiring hepatic transplantation sur-

geries over the last 21 years.¹ According to the latest WHO data (2018), liver disease deaths in India reached 264,193 or 3% of total deaths. The age-adjusted death rate is 21.96 per 100,000 of population which ranks India 61st in the world.² So, to perform consistently successful liver transplantati-

on in our Indian scenario, the detail knowledge about the vascular patterns (especially venous) and their variations is an extremely crucial requirement for the transplantation experts. In most of the hepatic disorders requiring conservative surgical management or in case of liver transplantation management of hepatic neoplasms and even in trans-jugular intrahepatic Porto systemic shunts (TIPSS), in-depth knowledge of this complex vascular anatomy of the liver is required.

Ultrasonographic evaluation of liver can throw a good amount of light on this issue by the clear visualization of inferior vena cava, the hepatic veins, and the main branch of portal vein. Ultrasound evaluation of liver is a basic and dependable noninvasive as well as a cost-effective diagnostic modality, especially in terminally ill patients for whom the results are essential prerequisite for planning effective diagnostic and therapeutic strategies. To learn about this detailed vascular anatomy non-invasive diagnostic modalities plays an invaluable role for the anatomist as well for the surgeons. To acquire this knowledge, multislice computed tomography and magnetic resonance imaging provide gold standard information about these vascular structures. But unlike CT scan, ultrasound is also an effective alternative as far as radiation safety is concerned. Especially in our country, it is a very economic modality of investigation which also does not even require very highly skilled manpower involved. To plan for these lifesaving valuable therapeutic interventions, a thorough knowledge of sonographic features of hepatic vascular anatomy, especially that of venous patterns, is absolutely indispensable.

Liver has a dual venous supply. Major share (approx. 75%) of the incoming deoxygenated but nutrient-rich blood reaches liver mainly from the gut, pancreas and splenic regions by the portal vein, whereas hepatic veins formed after commencing from numerous central veins of classical hepatic lobules and finally drain to inferior vena cava usually via three hepatic veins. In the present study, the normal and variations of hepatic venous pattern were observed in our medical college set up by transabdominal ultrasonography and were compared with other previous studies.

The earlier major studies which have been done at national or international level on hepatic vascular patterns and their variations are almost exclusively done by CT or MRI or by direct dissection of a number of cadaveric liver specimens. No definitive or authentic study, especially in our Indian perspective on this topic, could be noted in electronic and print media, as well as in standard textbook which can help the surgeons to come up with better outcome in future transplantation surgeries, that too by a low cost, less hazardous investigative modality like ultrasonography. My study is basically an attempt to bridge this lacuna.

AIM

(I) To estimate the prevalence and types of anatomical variations of hepatic vein and intrahepatic and extrahepa-

tic portal vein. (II) To determine association of variations among venous distribution.

MATERIALS AND METHODS

The study was performed in the Department of Anatomy and Department of Radiodiagnosis, RG Kar Medical college, Kolkata. It was an observational cross-sectional study. Adult patients who were referred for the hepatobiliary system ultrasound examination or for any upper abdominal complaints / routine abdominal investigation, in the Ultrasonography branch of the Department of Radiodiagnosis, RG Kar Medical College, Kolkata were evaluated, and data was collected with respect to the variation pattern of portal vein and hepatic vein. Patients attending the Radiology Department for upper abdominal ultrasonography were included in our study using consecutive sampling method and patients with major hepatic disease diagnosed clinically and biochemically were excluded from the study. Sample size (N) calculation was based on the formula:

$$(N) = \frac{(Z\alpha)^2 \times p \times q}{d^2} = \frac{(1.96)^2}{25} \times 10 = 139 \text{ (at least)}$$

where 'p' denotes the lower range (in our case 10%)³ of anatomical variations in hepatic portal venous system, and 'd' is the allowable error or absolute precision of value 5. Based on this, our sample size was comprised of 152 patients (Standard normal deviate 1.96, considering 95% confidence interval). After approval from the institutional ethics committee (West Bengal University of Health Sciences Memo No. OG/DEAN/WBUHS/2015-17/01 dated 7th Apr 2016, Kolkata), study participants were recruited and relevant information collected using SAMSUNG SONOACE R7 from Mar 2016 to Feb 2017. For analysis, SPSS version 17 was used.

RESULTS

In our study, there was a uniform distribution of study participants with respect to age and sex. Study participants were from two sources, from outpatient department (OPD) and from indoor admitted patients of various specialty departments. The subject who had been examined once, was never repeated to participate in the study. Maintaining the criteria of inclusion and exclusion, 152 patients were approached for this study, of whom nobody denied participating. For statistical analysis, data were entered into a Microsoft Excel spreadsheet and then analyzed by SPSS 17. Data had been summarized as percentages for categorical variables. A chi-squared test (χ^2 test) was any statistical hypothesis test wherein the sampling distribution of the test statistic is a chi-squared distribution when the null hypothesis is true. Unpaired proportions were compared by chi-square test or Fischer's exact test, as appropriate *p*-value ≤ 0.05 was considered statistically

significant. Collected data were analyzed under two sub-headings: one is the distribution pattern and another is finding association/relationship and all these have been described as well as summarized in tables.

Distribution pattern

Portal vein findings: Normal portal venous bifurcation pattern (right/left) is noted in high proportion (Table 1) of patients and this bifurcation occurred extrahepatically as well as intrahepatically, however trifurcation of portal vein is significantly less (13.15%) in this study, although this is twice more common in the intrahepatic bifurcation (17.2% vs. 8.4% in extrahepatic group) of portal venous group. Rt posterior branch arising as the first branch of main portal vein. Significantly less (9.8%) in this study and that too is lesser in extrahepatic bifurcation (8.4% against 11.1% in the intrahepatic group) of portal venous group. In all cases of abnormal and normal portal venous variants, flow pattern evaluation was consistently normal.

Hepatic vein findings: overall incidence of normal hepatic venous pattern is high (Table 1) but overall incidences of right hepatic vein 02 (double right hepatic vein), middle hepatic vein 02 (double middle hepatic vein), and of left hepatic vein 02 (double Lt hepatic vein) are low (Table 1), but these variations are higher in the intrahepatic bifurcation of portal venous group. Incidences of right hepatic vein 03 (triple right hepatic vein), left hepatic vein 03 (triple left hepatic vein) and left accessory hepatic vein proportion are very less, although this is higher in the extrahepatic bifurcation of portal venous group.

Association / Relationship

Normal portal vein with other hepatic venous patterns: 78.8% of normal hepatic veins show a normal portal ven-

ous pattern, which is remarkably high. And the incidences of association of both triple left hepatic vein as well as left accessory hepatic vein are the least in the normal portal venous group. Normal hepatic venous patterns are significant (65.8%) among normal portal venous group (Table 2).

Trifurcation of portal vein with other hepatic venous patterns

Normal hepatic venous pattern is highest in case of trifurcation of portal vein group and least with left accessory hepatic vein. Incidences of other hepatic variants are also very less in comparison to normal hepatic vein in case of relationship with trifurcation of portal vein (Table 2). Right posterior branch arising as first branch of portal vein with other hepatic venous patterns: in case of right posterior branch arising as first branch of main portal vein, incidences of both double left hepatic vein as well as left accessory hepatic vein are the lowest.

Extrahepatic bifurcation of portal vein with other portal and hepatic venous variations

Though the incidence of normal portal venous pattern is more in both extra as well as intrahepatic bifurcation of portal venous group but is more (83%) in the extrahepatic group. Trifurcation of portal vein is more in case of intra hepatic bifurcation of portal venous branching group. Rt posterior branch of portal vein arising as the first branch from main portal vein is higher in case of intra hepatic bifurcation of portal venous branching group. Normal hepatic venous pattern is marginally higher in case of intra hepatic bifurcation of portal venous branching pattern (Tables 3, 4, 5)

Table 1. Distribution of various portal venous and hepatic venous variations

Sl No.	Variation types	Yes (%)	No (%)
1.	Normal portal venous pattern	117 (77%)	35 (23%)
2.	Extrahepatic bifurcation of portal vein	71 (46.7%)	81 (53.3%)
3.	Trifurcation of portal vein	20 (13.2%)	132 (86.8%)
4.	Rt posterior branch of portal vein arising as 1 st branch of main portal vein	15 (9.9%)	137 (80.1%)
5.	Double left hepatic vein	23 (15.1%)	129 (84.9%)
6.	Double middle hepatic vein	13 (8.6%)	139 (91.4%)
7.	Double right hepatic vein	20 (13.2%)	132 (86.8%)
8.	Triple left hepatic vein	3 (2%)	149 (98%)
9.	Triple right hepatic vein	3 (2%)	149 (98%)
10.	Normal hepatic vein	99 (65.1%)	53 (34.9%)
11.	Left accessory hepatic vein	3 (2%)	149 (98%)

Table 2. Associations between variations of portal and hepatic venous system

Sl No.	Associations between variations of portal and hepatic venous system		Chi-square value	p-value
1.	Trifurcation of portal vein	Normal hepatic vein	86.1805	<0.00001
2.	Trifurcation of portal vein	Double right hepatic vein	0.0000	1.00000
3.	Trifurcation of portal vein	Triple right hepatic vein	13.5937	0.00022
4.	Trifurcation of portal vein	Double middle hepatic vein	1.6657	0.19684
5.	Trifurcation of portal vein	Double left hepatic vein	0.2438	0.62148
6.	Trifurcation of portal vein	Triple left hepatic vein	13.5937	0.00022
7.	Trifurcation of portal vein	Left accessory hepatic vein	13.5937	0.00022
8.	Normal portal vein	Double right hepatic vein	125.0201	<0.00001
9.	Normal portal vein	Triple right hepatic vein	178.9304	<0.00001
10.	Normal portal vein	Double middle hepatic vein	145.3609	<0.00001
11.	Normal portal vein	Double left hepatic vein	116.9923	<0.00001
12.	Normal portal vein	Triple left hepatic vein	178.9304	<0.00001
13.	Normal portal vein	Left accessory hepatic vein	178.9304	<0.00001
14.	RPPV as 1 st branch of main portal vein	Double left hepatic vein	1.9248	0.16532
15.	RPPV as 1 st branch of main portal vein	Double right hepatic vein	0.8072	0.36894
16.	RPPV as 1 st branch of main portal vein	Double middle hepatic vein	0.1573	0.69160
17.	RPPV as 1 st branch of main portal vein	Left accessory hepatic vein	8.5035	0.0035
18.	RPPV as 1 st branch of main portal vein	Triple left hepatic vein	8.5035	0.00354
19.	RPPV as 1 st branch of main portal vein	Triple right hepatic vein	8.5035	0.00354
20.	Normal portal vein	Normal hepatic vein	5.1818	0.0228

RPPV: Rt Posterior branch of portal vein arising as the 1st branch of main portal vein

DISCUSSION

As the complexity of liver interventions by both surgeons and radiologists expands, increasing awareness of standard and variant anatomy is critical. This complexity has been well documented in the liver transplantation literature, and many surgeons routinely obtain preoperative CT or MR angiograms to check vascular pattern. With the increase in percutaneous hepatobiliary interventions and complex surgical resections, a thorough understanding of variants in portal vein anatomy is crucial. Throughout the study, the basic thrust was given to explore and identify the important variations of hepatic portal vein and other hepatic veins in the patients of this region of India, and to compare the variations with other foreign studies.

Definition of variations

Based on detailed review of literatures, the following working definitions of variations have been set for this study keeping in mind the context of our Indian population:

Normal hepatic venous pattern: where three hepatic veins (right, middle and left hepatic vein) drain into the IVC approx. 2 cm caudal to right atrium.

Hepatic venous variations were analyzed based on six

Table 3. Associations of variations in case of extrahepatic bifurcation of portal vein

Sl No.	Associations of variations in case of extrahepatic bifurcation of portal vein	Chi-square value	p-value
1.	Normal hepatic vein	10.4625	0.00121
2.	Double right hepatic vein	40.7937	<0.00001
3.	Triple right hepatic vein	82.5908	<0.00001
4.	Double middle hepatic vein	55.3385	<0.00001
5.	Double left hepatic vein	35.4821	<0.00001
6.	Triple left hepatic vein	82.5908	<0.00001
7.	Normal portal vein	29.4967	<0.00001
8.	Trifurcation of portal vein	40.7937	<0.00001
9.	RPPV as 1 st branch of main portal vein	50.8504	<0.00001

RPPV: Rt Posterior branch of portal vein arising as the 1st branch of main PV

groups⁴: (1) Double right hepatic vein; (2) Triple right hepatic vein; (3) Double middle hepatic vein; (4) Double left hepatic vein; (5) Triple left hepatic vein, and (6) left accessory hepatic vein (**Fig. 1**).

Table 4. Associations of all extrahepatic bifurcation of portal vein with various portal and hepatic venous variations

Sl No.		Extrahepatic bifurcation of portal vein		
		(Yes)	(No)	p-value
1.	Normal portal vein pattern (Rt & Lt bifurcation)	59	93	<0.0001
2.	Trifurcation of portal vein (Rt medial, Lat and Left)	6	146	<0.0001
3.	Rt Posterior branch arising as the 1st branch of main portal vein	6	146	<0.0001
4.	Normal hepatic venous pattern	45	107	<0.0001
5.	Double right hepatic vein	8	144	<0.0001
6.	Triple right hepatic vein	2	150	<0.0001
7.	Double middle hepatic vein	4	148	<0.0001
8.	Double left hepatic vein	11	141	<0.0001
9.	Triple left hepatic vein	2	150	<0.0001
10.	Lt accessory hepatic vein	2	150	<0.0001

Table 5. Associations between variations of hepatic veins and portal vein

		Normal hepatic vein	Double Rt hepatic vein	Triple Rt hepatic vein	Double Middle hepatic vein	Double Lt hepatic vein	Triple Lt Hepatic vein	Lt accessory hepatic vein
Normal portal vein	(Yes)	78	16	03	10	16	02	02
	(No)	74	136	149	142	136	150	150
	p-value	0.64552	<0.0001	<0.0001	<0.0001	<0.0001	<0.0001	<0.0001
Trifurcation of portal vein	(Yes)	13	02	0	02	02	01	0
	(No)	139	150	152	150	150	151	152
	p-value	<0.0001	<0.0001	<0.0001	<0.0001	<0.0001	<0.0001	<0.0001
RPPV arising as the 1st branch of portal vein	(Yes)	08	02	0	01	05	0	01
	(No)	144	150	152	151	147	152	151
	p-value	<0.0001	<0.0001	<0.0001	<0.0001	<0.0001	<0.0001	<0.0001

RPPV: Rt Posterior branch of portal vein arising as the 1st branch of main PV

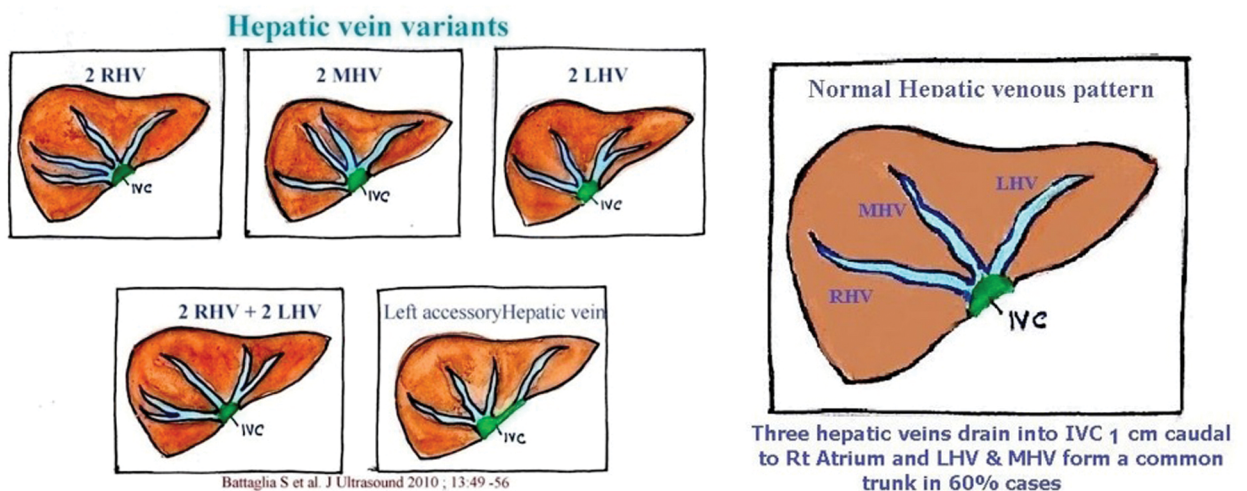


Figure 1. Normal hepatic venous pattern and some of its variants. (Courtesy: Battaglia S, Fachinetti C, Draghi F, Rapaccini GL, de Mattheis N, Abbattista T, et al. Ultrasound examination of the liver: Variations in the vascular anatomy. J Ultrasound 2010; 13(2):49–56).

Main portal venous variations were analyzed based on four groups⁵ (Fig. 2):

- (1) Whether the bifurcation is extra or intrahepatic.
- (2) Normal bifurcation of main portal venous trunk (Type 1) – Rt and left bifurcation of main portal vein with further division of right branch into anterior and posterior and left portal branch takes a bend after a short horizontal course and gives branches to segment II, III and IV (Fig. 2A).
- (3) Trifurcation (Type 2) – It is the most common variant and so called “portal vein trifurcation” where the main portal vein divides into three branches: the left portal vein, the right anterior portal vein, and the right posterior portal vein (Fig. 3A).
- (4) Right posterior branch arising from main portal vein (Type 3) – The second most common variant is a right posterior portal vein (RPPV) originating as the first branch of the portal vein. These two variants account for the majority of main portal vein variation.

In our study, 23% of patients had a variant portal vein anatomy, which is significantly greater than the 10%–15%

described in early published data from two sonography literatures^{6,7} which is still widely quoted but consistent with the range of 20% to 35% of the population as published in an article.⁸ In our cohort, 23.1% of the patients had either trifurcation (type 2) or Z (type 3) anatomy, of which fifteen patients (9.9%) had what we considered a single right posterior branch arising as the first branch of the right portal vein. In one study⁹, more than 22% of patients had either trifurcation (type 2) or (type 3) anatomy and 7% of total patients had what they considered a single posterior segment branch (types 4 and 5) arising as the first branch of the right portal vein in their study, whereas in our cohort it was 9.9%. Identifying these variants in patients who are to undergo left trisegmentectomy can alert the surgeon and avoid a potentially life-threatening complication. As per the article of Schmidt S et al., the most common variant was the so called “portal vein trifurcation”, and the right posterior portal vein (type 2). The second most common variant is a right posterior portal vein originating as the first branch of the portal vein (type 3).¹⁰ These two variants account for the majority of main portal vein variation. Their relative incidence varies from study to study and the

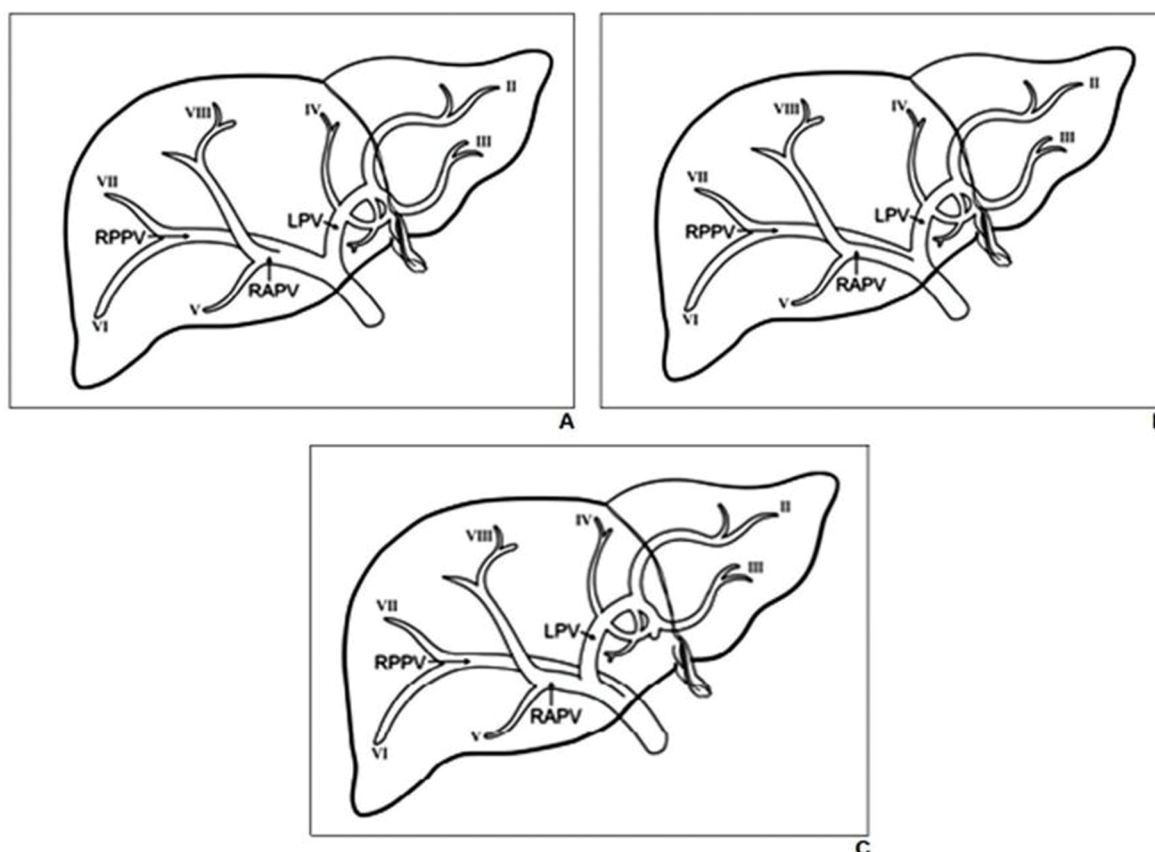


Figure 2. Illustrations show classification scheme of portal vein anatomy. LPV: left portal vein; RPPV: right posterior portal vein; RAPV: right anterior portal vein. (Printed with permission from Memorial Sloan-Kettering Cancer Center) A–C, Drawings depict standard portal vein anatomy (type 1, A), trifurcation (type 2, B), right posterior portal vein as first branch of main portal vein (type 3, C). (Courtesy: Covey AM, Brody LA, Getrajdman GI, Sofocleous CT, Brown KT. Incidence, patterns, and clinical relevance of variant portal vein anatomy. *AJR Am J Roentgenol* 2004 ;183(4):1055–64).

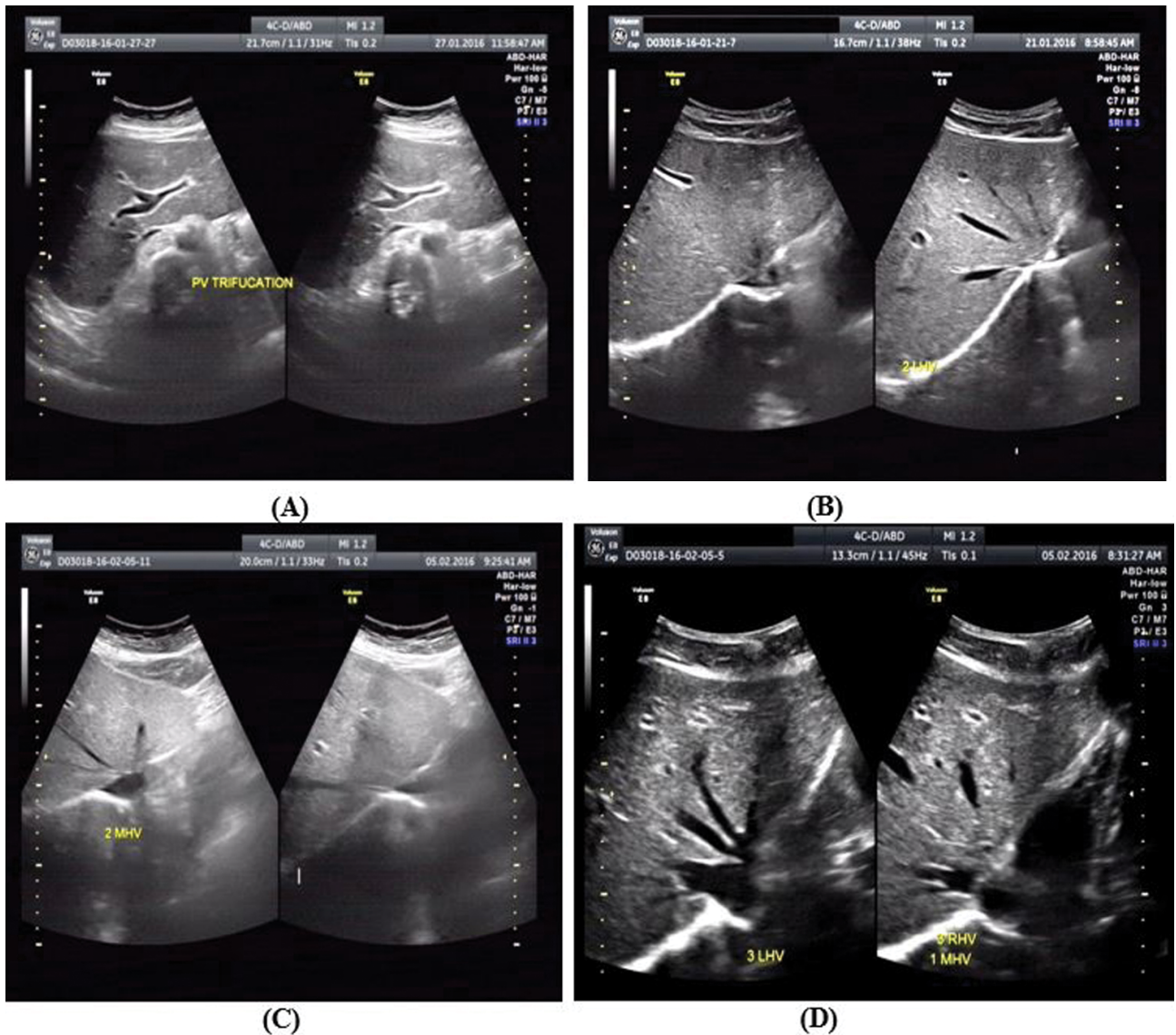


Figure 3. (A) Trifurcation of portal vein; (B) Double left hepatic vein; (C) Double middle hepatic vein; (D) Triple right hepatic vein with triple left hepatic vein.

reported incidence of these variants increases with the use of the most recent imaging modalities. In older reports, the incidence was ranged between 0.09 and 24%.^{5,11,12} The use of 3D reconstruction obtained from thin axial CT images seems the most efficient technique with reported incidences of 27 and 35%.^{5,7,13} In the study of Atasoy and colleagues, type 3 was twice more frequent than type 2 (23.5 and 9.5%, respectively).¹⁴ In the study of Covey et al., the reported incidence of type 2 and 3 were respectively 9 and 13%.⁹ In another recent study including 1384 patients, trifurcation was slightly more frequent than early origin of the right posterior branch of the portal vein (11.1 and 9.7%, respectively).¹² In our study, the incidence of type 2 portal venous variation is 13.2%. In case of variations of hepatic venous pattern, Fang CH et al. stated in their article “The prevailing pattern of the three hepatic veins in these subjects was a right hepatic vein (RHV) and a common trunk for the middle

(MHV) and left (LHV) hepatic veins (122/200, 61%)”. The remaining patients had the RHV, MHV, and LHV draining independently into the inferior vena cava (IVC). In 39% of patients, the RHV was small and was compensated by a large right inferior hepatic vein (21.0%), an accessory RHV (8.5%) or a well-developed MHV (6.5%). A segment 4 vein was seen in 51.5% of patients. This segment 4 vein joined the LHV (26%), the MHV (17.5%), or the IVC (8%). An umbilical vein and a segment 4 vein were seen in 3.5% of patients. These two veins joined either the LHV (2.0%) or the MHV (1.5%)¹⁴ In one article¹⁵, it has been clearly mentioned that an accessory right inferior hepatic vein (RHV) is the most common variation of the hepatic veins and is present in up to 48% of the population draining the posterior part of the right lobe (mainly segments 6 and 7) directly into the inferior vena cava.¹⁴ Right inferior hepatic vein or double right hepatic vein (21.0%) was also reported by

Steinbrück K et al.¹⁶ In case of double middle hepatic vein (MHV), Kamel IR et al. stated that “in 10 patients (20%), a major branch was seen draining each lobe”¹⁶ whereas in case of triple LHV and MHV Chi-Hua Fang et al. stated that those two veins joined either the LHV (2.0%) or the MHV (1.5%). In our cohort, the patterns of variations of hepatic veins differs with the above-mentioned study¹⁴ by Fang CH et al. Double left hepatic vein (LHV) (**Fig. 3B**) is seen in 15.1% and that too is slightly higher in case of extrahepatic bifurcation of portal vein. Double middle hepatic vein (MHV) (**Fig. 3C**) is seen in 8.6% (almost double in case of intrahepatic bifurcation of portal vein) and double right hepatic vein (RHV) (**Fig. 4**) is seen in 13.2% (slightly higher in case of intrahepatic bifurcation of portal vein). Separate incidences of triple RHV, LHV (**Fig. 3D**) and left accessory hepatic vein as described in one study¹⁷ could not be found in other texts.

Those patients requiring liver transplants have a poor scan window in ultrasonography and ultimately need contrast-enhanced CT, multidetector CT (MDCT) scan or MRI scan with or without 3D reconstruction.^{13,18-21} Certainly, these scan methods are much more sensitive and specific in detecting the variations of anatomy of hepatic and portal venous system. We used ultrasonography in our study as it is the most affordable, cheap, non-invasive, and safe initial investigative procedure for a poor set-up in a peripheral medical college. On ultrasound, the inferior vena cava, the openings of the hepatic veins, and the main branch of the portal vein can always be visualized, but intrasegmental vessels (portal, arterial, accessory hepatic venous branches) can be only partially depicted and in some cases not at all.⁴ In a well-conducted study of Battaglia et al., after acknowledging the superiority of multislice CT or MRI over ultrasound, it has been opined that ultrasonographic evaluation is still the method of choice for use in some situations, and a thorough knowledge of the sonographic appearance of the normal hepatic vasculature and its anatomic variants is an absolute requirement (Battaglia S et al.).⁶ Each meticulous scan performed by an expert Associate Profes-

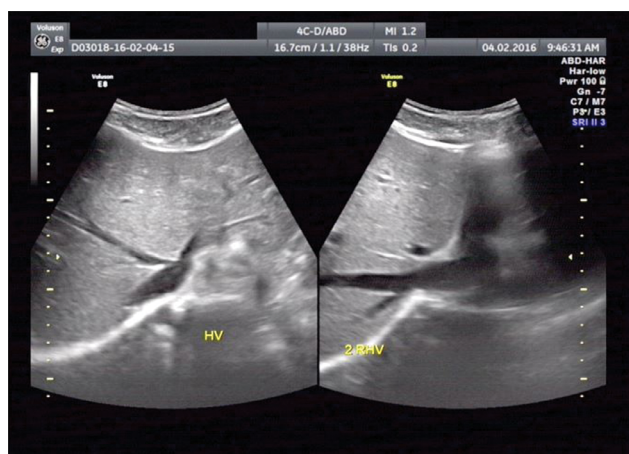


Figure 4. Double right hepatic vein.

sor of Radiodiagnosis, which took median time of 18 minutes on an average to search for the probable variations of hepatic venous system. We faced difficulties in complete visualization of the venous system in case of obese and COPD patients who were excluded during the screening process. In few cases, the intrasegmental portion of portal vein and few accessory veins were poorly visualized.

CONCLUSIONS

This study provides an updated database for the prevalence and distribution of different patterns of anatomic variations of the hepatic venous and portal venous system for which information is scattered and heterogenous. Our study also presents an additional source of information, for those features known to present great variability. Ultrasonographic detailed evaluation of hepatic veins and portal veins is also helpful for clinicians and researchers as all these are newer results for researchers in Indian scenario. Ultrasonographic study was conducted keeping in mind the use of a cost-effective diagnostic modality for the poor patients of a third world country like ours and to build up an indigenous database of hepatic venous variations which will be very much helpful for decision making process.

The uniqueness of the present study is an attempt to establish a head-to-head comparison pattern of various portal venous variations with variations of hepatic venous patterns and that too further has been fine-tuned by analyzing against extra or intrahepatic bifurcation groups of portal vein. No such studies could be found either in standard textbooks or in the Internet. The author suggests carrying out studies involving large number of patients to update its database. Possibilities of chronic liver diseases in those patients having abnormalities in hepatic venous pattern or portal venous anomalies may be searched for.

Acknowledgements

I sincerely convey my acknowledgement to the staff of Department of Radiodiagnosis and Department of Surgery, RG Kar Medical College who have rendered their kind cooperation.

Author contribution

P.S.A.: literature search, clinical studies, data acquisition, data analysis; U.K.R.: statistical analysis, manuscript preparation, manuscript editing, manuscript review, guarantor; R.M.: concepts, design, manuscript editing, definition of intellectual content, literature search, data analysis; S.C.: concepts, design, manuscript editing, definition of intellectual content, clinical studies, data acquisition

Conflict of Interest

The authors have declared that no conflicts of interests exist. The authors have no funding or support to report.

REFERENCES

1. Soin AS, Thiagarajan S. Liver transplant scene in India. *MAMC Journal of Medical Sciences* 2016; 2(1):6.
2. World Life Expectancy [Internet]. [cited 2020 Nov 10]. Available from: <https://www.worldlifeexpectancy.com/india-liver-disease>
3. Lodge P. Liver. In: Standring S, editor. *Gray's Anatomy*. 41st ed. London: Elsevier; 2016:1167.
4. Draghi F, Rapaccini GL, Fachinetti C, et al. Ultrasound examination of the liver: Normal vascular anatomy. *J Ultrasound* 2007; 10(1):5–11.
5. Soyer P, Bluemke DA, Choti MA, et al. Variations in the intrahepatic portions of the hepatic and portal veins: findings on helical CT scans during arterial portography. *AJR Am J Roentgenol* 1995; 164(1):103–8.
6. Battaglia S, Fachinetti C, Draghi F, et al. Ultrasound examination of the liver: Variations in the vascular anatomy. *J Ultrasound* 2010; 13(2):49–56.
7. Atasoy C, Ozyürek E. Prevalence and types of main and right portal vein branching variations on MDCT. *AJR* 2006; 187(3):676–81.
8. Atri M, Bret PM, Fraser-Hill MA. Intrahepatic portal venous variations: prevalence with US. *Radiology* 1992; 184(1):157–8.
9. Filly RA, Laing FC. Anatomic variation of portal venous anatomy in the porta hepatis: ultrasonographic evaluation. *J Clin Ultrasound* 1978; 6(2):83–9.
10. Schmidt S, Demartines N, Soler L, et al. Portal vein normal anatomy and variants: implication for liver surgery and portal vein embolization. In: *Seminars in interventional radiology* 2008; 25(2):86). Thieme Medical Publishers.
11. Erbay N, Raptopoulos V, Pomfret EA, et al. Living donor liver transplantation in adults: vascular variants important in surgical planning for donors and recipients. *AJR* 2003; 181(1):109–14.
12. Fraser-Hill MA, Atri M, Bret PM, et al. Intrahepatic portal venous system: variations demonstrated with duplex and color Doppler US. *Radiology* 1990; 177(2):523–6.
13. Covey AM, Brody LA, Getrajdman GI, et al. Incidence, patterns, and clinical relevance of variant portal vein anatomy. *AJR* 2004; 183(4):1055–64.
14. Fang C-H, You J-H, Lau WY, et al. Anatomical variations of hepatic veins: three-dimensional computed tomography scans of 200 subjects. *World J Surg* 2012; 36(1):120–4.
15. Gaillard F. Accessory right inferior hepatic vein [Internet]. [cited 2020 Nov 10]. Available from: <https://radiopaedia.org/articles/accessory-right-inferior-hepatic-vein>
16. Steinbrück K, Fernandes R, Bento G, et al. Inferior right hepatic vein: a useful anatomic variation for isolated resection of segment VIII. *Case Rep Surg* 2013; 2013:371264.
17. Kamel IR, Lawler LP, Fishman EK. Variations in anatomy of the middle hepatic vein and their impact on formal right hepatectomy. *Abdom Imaging* 2003; 28(5):668–74.
18. Iqbal S, Iqbal R, Iqbal F. Surgical implications of portal vein variations and liver segmentations: a recent update. *J Clin Diagn Res* 2017; 11(2):AE01–AE05.
19. Singh AK, Cronin CG, Verma HA, et al. Imaging of preoperative liver transplantation in adults: what radiologists should know. *Radiographics* 2011; 31(4):1017–30.
20. Ali TF, Tawab MA, EL-Hariri MA, et al. Pre-operative hepatic vascular mapping of living donor for liver transplantation using 64-MDCT. *Egypt J Radiol Nucl Med* 2012; 43(3):325–36.
21. Catalano OA, Singh AH, Uppot RN, et al. Vascular and biliary variants in the liver: implications for liver surgery. *Radiographics* 2008; 28(2):359–78.

Исследование печени человека с помощью ультразвукового исследования для поиска вариаций венозной анатомии

Парта Саратхи Аин¹, Утам Кумар Рой¹, Рудрадев Мейур², Субхаджит Чатопадхияй²

¹ Государственный медицинский колледж и больница Райгандж, Райгандж, Утардинаджпур, Западная Бенгалия, Индия

² Медицинский колледж и больница им. Р.Г. Кар, Колката, Индия

Адрес для корреспонденции: Утам Кумар Рой, Государственный медицинский колледж и больница Райгандж, Райгандж, Утардинаджпур, Западная Бенгалия, Индия; E-mail: uroy951@gmail.com

Дата получения: 14 ноября 2020 ♦ **Дата приемки:** 8 февраля 2021 ♦ **Дата публикации:** 31 октября 2021

Образец цитирования: Ain PS, Roy UK, Meyur R, Chattopadhyay S. Study of the human liver by ultrasound examination to search for variations of venous anatomy. *Folia Med (Plovdiv)* 2021;63(5):676-85. doi: 10.3897/folmed.63.e60772.

Резюме

Введение: Знание моделей вен (особенно воротной и печёночной вены) и их вариаций имеет важное значение для трансплантации печени и других хирургических процедур печени. Исследования на национальном и международном уровнях были выполнены на вариациях моделей печёночной вены с помощью КТ или МРТ или путём рассечения трупной печени. Однозначных или авторских исследований по этой теме в электронных и бумажных носителях, а также в стандартном учебнике не обнаружено. В поисках недорогой и неинвазивной процедуры мы использовали ультразвук, чтобы восполнить пробел в исследованиях.

Цель: Оценить частоту и типы анатомических вариаций печёночной венозной системы и установить связь между вариациями.

Материалы и методы: Это исследование текущего состояния путём наблюдения, в котором ультразвуковая оценка модели печёночной венозной крови у взрослого населения обоих полов (последовательные образцы) без серьёзных нарушений печени была проведена в Медицинском колледже им. Р.Г. Кар, и данные были проанализированы с использованием соответствующих статистических процедур.

Результаты: Модель нормальной печёночной вены вместе с моделью нормальной портальной вены гораздо чаще встречаются в нашем исследовании, что является уникальным открытием. Доля модели нормальной портальной вены больше в группе с дополнительной бифуркацией печени. Вариации воротной вены и нормального печёночного венозного рисунка больше проявляются в виде внутripечёночной бифуркации группы ветвей воротной вены. В целом наличие внутripечёночной бифуркации воротной вены значительно выше, чем внепечёночной бифуркации.

Заключение: Это исследование предоставляет обновленную базу данных о частоте и распространённости анатомических изменений печёночной венозной и портальной венозной систем.

Ключевые слова

анатомия, печёночная вена, трансплантация печени, воротная вена
