



# Ultrasound Fusion Imaging System in Neurology Practice

Marieta V. Peycheva<sup>1</sup>, Lyubomir Chervenkov<sup>2</sup>, Zdravka Harizanova<sup>3</sup>, Ferihan Ahmed-Popova<sup>3</sup>, Zahari I. Zahariev<sup>1</sup>

<sup>1</sup> Department of Neurology, Faculty of Medicine, Medical University of Plovdiv, Plovdiv, Bulgaria

<sup>2</sup> Department of Diagnostic Imaging, Faculty of Medicine, Medical University of Plovdiv, Plovdiv, Bulgaria

<sup>3</sup> Department of Anatomy, Histology and Embryology, Faculty of Medicine, Medical University of Plovdiv, Plovdiv, Bulgaria

**Corresponding author:** Marieta Peycheva, Department of Neurology, Medical University of Plovdiv, 66 Peshtersko shosse Blvd., 4000 Plovdiv, Bulgaria; Email: mpeitcheva@yahoo.com; Tel.: +359 32 602 282

**Received:** 10 Feb 2021 ♦ **Accepted:** 22 Mar 2021 ♦ **Published:** 31 Aug 2022

**Citation:** Peycheva MV, Chervenkov L, Harizanova Z, Ahmed-Popova F, Zahariev ZI. Ultrasound fusion imaging system in neurology practice. *Folia Med (Plovdiv)* 2022;64(4):667-671. doi: 10.3897/folmed.64.e64271.

## Abstract

The ultrasound fusion imaging (UFI) system is a new promising imaging modality that combines live ultrasound investigations with preregistered CT, MRI, or PET images. In this study, we want to present our initial experience with the new method that combines the transcranial color-coded sonography (TCCS) in different insonation planes and the 3T-weighted MRI cerebral images. The study validates the diagnostic capabilities of the system to detect different normal cerebral structures in healthy volunteers. In the present paper, we also discuss the advantages of US fusion imaging technology and its clinical applications in Neurology.

## Keywords

transcranial colour-coded sonography, ultrasound fusion imaging, ultrasound diagnostics

## INTRODUCTION

The ultrasound fusion imaging (UFI) system is a new promising imaging modality that combines live ultrasound investigations with preregistered CT, MRI or PET images.<sup>[1]</sup> The system was first used for analysis of lesions located in the liver<sup>[2]</sup>, breasts<sup>[3]</sup>, and prostate<sup>[4]</sup>. It has a special diagnostic approach for ultrasound-guided biopsies of suspicious lesions.<sup>[5]</sup> Recent publications reported its new application in neurosonology for diagnostics and teaching.<sup>[6,7]</sup>

## AIM

The aim of the present study was to confirm the method of ultrasound fusion imaging with transcranial colour sonography using different planes of insonation, thus detect

different normal cerebral structures, and confirm the diagnostic capabilities of the new method in healthy volunteers.

## MATERIALS AND METHODS

For this small study, we examined 20 healthy volunteers at the mean age of 35 years with no pathology on MR images. All patients signed an informed consent prior the investigations and all of them had no contraindications for electromagnetic field studies. For the current investigations, a premium Philips EPIQ Elite ultrasound system with PercuNav fusion software package and PercuNav accessories was used. Prior to examination, cerebral images from 3T-weighted MR were loaded into the ultrasound machine in DICOM format. The system is compatible with all types

of CT/MR machines. The patient lied down in a supine position. The researcher sat on the side of the patient's head and nearby an adjustable electromagnetic field generator that continuously emits a local electromagnetic field directed to the studied area was fixed. A small electromagnetic patient tracker (motion control sensor) was fixed to the patient's forehead and remained there until the end of examination. A second electromagnetic tracker was attached to a low frequency ultrasound probe used for transcranial insonation. The patient lied still but after fixing the first tracker, he could move his head slightly and breathe calmly. At least three intracranial or extracranial markers between the ultrasound and MR images were used to perform the fusion. The whole process of preparation, positioning, and matching described above took about 10 minutes. During investigation, the images from the ultrasound appeared on the US machine screen and the combined US/MR images were visualized accordingly.

## RESULTS

The presented images are a combination between previously performed 3T weighted MR cerebral images of healthy patients and live provided transcranial color-coded sonography. Ultrasound transcranial colour-coded sonography is a safe method and patients do not need any special preparation but still there are certain limitations. As ultrasound waves are absorbed by the skull bones there are only three available bone windows through which intracranial parenchymal and vascular structures can be studied - transtemporal, suboccipital, and transorbital. Structures like mid-brain, cerebral parenchyma, cerebrospinal cisterns, and

different segments of middle cerebral artery, anterior and posterior cerebral arteries, as well as anterior and posterior communicating arteries can be observed via transtemporal access in axial insonation plane (**Fig. 1**).

By changing to transtemporal coronal insonation plane (**Fig. 2**), distal segments of internal carotid artery and some variations of middle cerebral artery as early bifurcation can be easily seen. The access also allows a coronal view of normal and pathological brain structures.

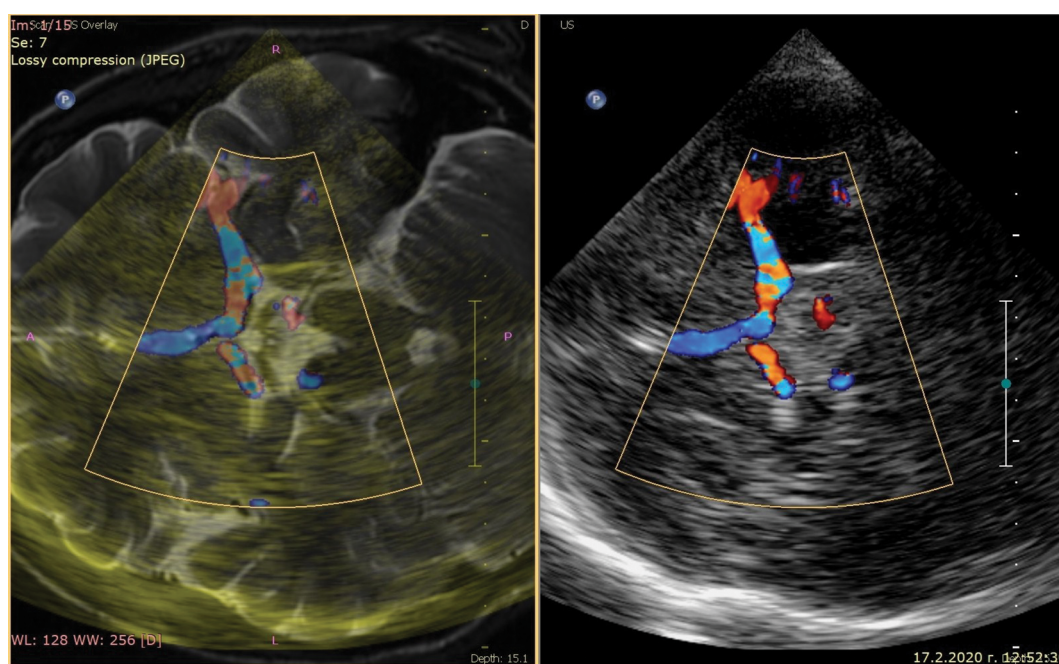
In suboccipital insonation plane (**Fig. 3**), foramen magnum, medulla oblongata, intracranial parts of vertebral arteries and their branches, and basilar artery can be observed.

Despite the limitations of bone windows, the achieved images represent brain structures live and in 3D reconstructed MR images.

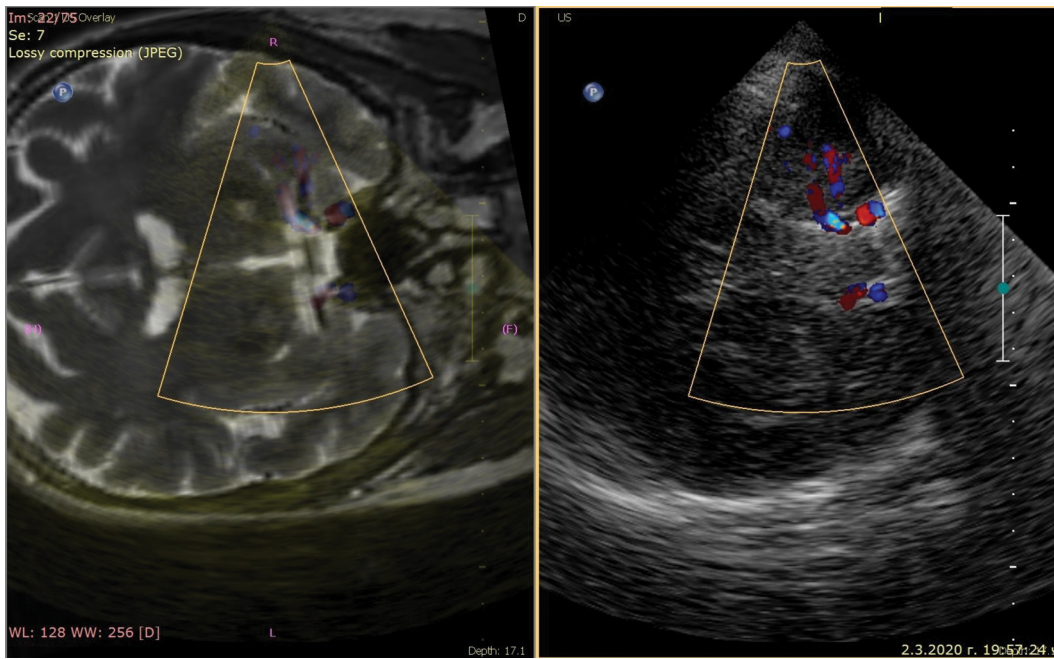
## DISCUSSION

Ultrasound transcranial colour-coded sonography provides real-time imaging, uses no ionizing radiation, and is easily accessible. However, there are certain limitations as ultrasound waves are absorbed by the skull and brain structures are not presented in details. On the other hand, MRI or CT cerebral images are of high quality, but rather expensive, time consuming, and impossible to repeat frequently. The ultrasound fusion imaging system gives new promising possibilities combining the benefits of both modalities. The system allows live and detailed examination of cerebral structures and safety follow-up examinations.

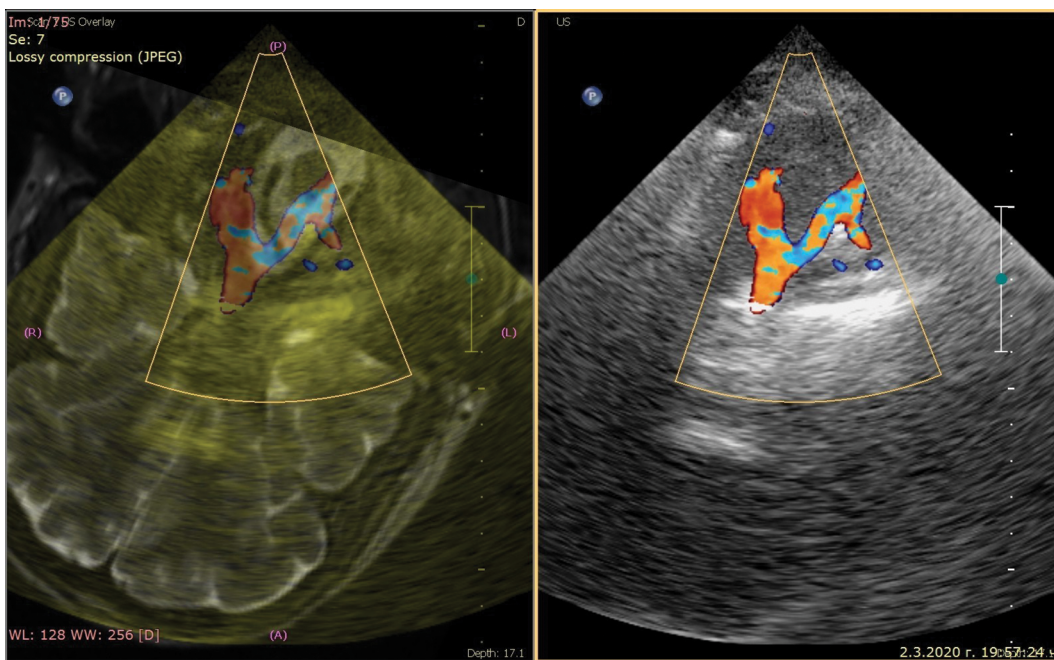
The fusion technique was first used for abdominal investigations and ultrasound guided biopsy of suspicious lesions.<sup>[1,2]</sup> US fusion imaging can also be associated with



**Figure 1.** Ultrasound fusion imaging: transtemporal axial insonation plane of transcranial colour-coded sonography: combined US/3T weighted MR image on the left and ultrasound image on the right.



**Figure 2.** Ultrasound fusion imaging: transtemporal coronal insonation plane of transcranial colour-coded sonography: combined US/3T weighted MR image on the left and ultrasound image on the right.



**Figure 3.** Ultrasound fusion imaging: suboccipital insonation plane of transcranial colour-coded sonography: combined US/3T weighted MR image on left and ultrasound image on the right.

advanced US imaging techniques such as color Doppler US, elastography, and contrast-enhanced US (CEUS).<sup>[8]</sup> The only limitation is that patients with pacemakers should not be exposed to the electromagnetic field of the systems and therefore cannot be examined.

Schreiber et al. first described the applications of the system in neurosonology<sup>[6]</sup> giving some important instructions about verification of different structures on the differ-

ent insonation planes. They also pointed the advantages of the method for repeated measurements in cases of subdural hematoma, hydrocephalus, or arachnoidal cyst.

Walter et al. described the benefits of the use of magnetic resonance-transcranial ultrasound fusion imaging for post-operative control of deep brain stimulation (DBS) electrode location.<sup>[9]</sup> They concluded that this technique may decrease the need for repeated CT or MRI scans in DBS patients.



Other researchers made further investigations and found other applications of the method in neurology.<sup>[10]</sup> These authors used 7T MR neurography-ultrasound fusion for peripheral nerve imaging. They demonstrated the utility of UFI system for more accurate identification of Guillain-Barre syndrome and Charcot-Marie-Tooth disease type 1A.

In our study, in order to validate the diagnostic opportunities of the method for normal anatomical structures, we chose only healthy volunteers, with no abnormalities on cerebral MR images. The mean age of the patients was 35 years, expecting good bone window and excellent quality of the images. We did not include patients with any contraindications for magnetic field studies. In all patients, we achieved very good rate of successful images in the two main insonation planes (transtemporal and suboccipital). In this way, we managed to detect in detail different anatomical structures that could be difficult to observe if using only ultrasound transcranial colour-coded sonography. Another advantage of the method is that we can repeat the investigations if we want to follow up our patients. The patients also felt very comfortable during the study. The examination also provided live information, for example, about the current flow direction and velocity of the vessels, which could not be diagnosed during MR study. We expect certain limitations if we include older patients with poor bone window and patients with contraindications for magnetic field studies. Our further investigations will be focused on patients between 40 and 65 years of age with cerebrovascular disease proving the diagnostic opportunities of the method in this pathology.

## CONCLUSIONS

The ultrasound fusion imaging system is a new promising imaging modality in neurology with multiple reproducibility providing real-time monitoring. In our study, we managed to validate the method for detecting different transcranial structures in healthy volunteers. We also proved that the combination of the two imaging methods (magnetic resonance and ultrasound imaging) increased the volume of diagnostic opportunities for detecting different cerebral structures.

## Acknowledgements

The article is a part of the research project “Cerebrovascular disease - new methods of diagnosis and prevention” funded by the Medical University of Plovdiv, Bulgaria (project code 17/2019).

## Author contributions

All authors listed have contributed sufficiently to the project to be included as authors, and all those who are qualified to be authors are listed in the author by-line.

## REFERENCES

1. Stoll J. Ultrasound fusion imaging. *Perspectives in Medicine* 2012; 1(112):80–1.
2. Tatsugami F, Matsuki M, Nakai G, et al. Hepatic computed tomography for simultaneous depiction of hepatocellular carcinoma, intrahepatic portal veins, and hepatic veins in real-time virtual sonography: initial experience. *J Ultrasound Med* 2007; 26:1065–9.
3. Nakano S, Yoshida M, Fujii K, et al. Fusion of MRI and sonography image for breast cancer evaluation using real-time virtual sonography with magnetic navigation: first experience. *Jpn J Clin Oncol* 2009; 39:552–9.
4. Singh AK, Kruecker J, Xu S, et al. Initial clinical experience with real-time transrectal ultrasonography-magnetic resonance imaging fusion-guided prostate biopsy. *BJU Int* 2008; 101:841–5.
5. Siddiqui MM, Rais-Bahrami S, Turkbey B, et al. Comparison of MR/ultrasound fusion-guided biopsy with ultrasound-guided biopsy for the diagnosis of prostate cancer. *JAMA* 2015; 313(4):390–7.
6. Schreiber SJ, Valdueza JM, Doepp F. Transcranial color coded sonography: advanced approach using ultrasound fusion imaging. *IJC-NMH* 2014; 1(Suppl 1):S16.
7. Zamboni P, Menegatti E, Viselner G, et al. Fusion imaging technology of the intracranial veins. *Phlebology* 2012; 27(7):360–7.
8. European Society of Radiology (ESR), D’Onofrio M, Beleù A, et al. Abdominal applications of ultrasound fusion imaging technique: liver, kidney, and pancreas. *Insights Imaging* 2019; 10(1):6.
9. Walter U, Müller JU, Rösche J, et al. Magnetic resonance-transcranial ultrasound fusion imaging: A novel tool for brain electrode location. *Mov Disord* 2016; 31(3):302–9.
10. Schreiber S, Schreiber F, Peter A, et al. 7T MR neurography-ultrasound fusion for peripheral nerve imaging. *Muscle Nerve* 2020; 61(4):521–6.

# Ультразвуковая система визуализации Fusion в неврологической практике

Мариета В. Пейчева<sup>1</sup>, Любомир Червенков<sup>2</sup>, Здравка Харизанова<sup>3</sup>, Ферихан Ахмед-Попова<sup>3</sup>, Захари И. Захариев<sup>1</sup>

<sup>1</sup> Кафедра неврологии, Факультет медицины, Медицинский университет - Пловдив, Пловдив, Болгария

<sup>2</sup> Кафедра рентгенологии, Факультет медицины, Медицинский университет - Пловдив, Пловдив, Болгария

<sup>3</sup> Кафедра анатомии, гистологии и эмбриологии, Факультет медицины, Медицинский университет - Пловдив, Пловдив, Болгария

**Адрес для корреспонденции:** Мариета В. Пейчева, Кафедра неврологии, Факультет медицины, Медицинский университет - Пловдив, бул. „Пещерско шосе“ № 66, 4000 Пловдив, Болгария; Email: mpeitcheva@yahoo.com; Тел.: +359 32 602 282

---

**Дата получения:** 10 февраля 2021 ♦ **Дата приемки:** 22 марта 2021 ♦ **Дата публикации:** 31 августа 2022

---

**Образец цитирования:** Peycheva MV, Chervenkov L, Harizanova Z, Ahmed-Popova F, Zahariev ZI. Ultrasound fusion imaging system in neurology practice. Folia Med (Plovdiv) 2022;64(4):667-671. doi: 10.3897/foimed.64.e64271.

---

## Резюме

Ультразвуковая система визуализации Fusion (UFI) — это новый многообещающий метод визуализации, который сочетает в себе ультразвуковые исследования в режиме реального времени с предварительно зарегистрированными изображениями КТ, МРТ или ПЭТ. В этом исследовании мы хотим представить наш первоначальный опыт работы с новым методом, который сочетает в себе транскраниальную сонографию с цветовым кодированием (ТКСЦК) в разных плоскостях инсонации и 3Т-взвешенные МРТ-изображения головного мозга. Исследование подтверждает диагностические возможности системы по обнаружению различных нормальных структур головного мозга у здоровых добровольцев. В настоящей статье мы также обсуждаем преимущества технологии ультразвуковой визуализации Fusion и её клиническое применение в неврологии.

---

## Ключевые слова

транскраниальная сонография с цветовым кодированием, ультразвуковая система визуализации Fusion, ультразвуковая диагностика

---