



# Final Fusion in a Complex of Surgical Treatment for Early Onset Scoliosis

Mikhail V. Mikhaylovskiy<sup>1</sup>, Sergey O. Ryabykh<sup>2</sup>, Vasilij A. Suzdalov<sup>1</sup>, Egor Y. Filatov<sup>2</sup>, Dmitry M. Savin<sup>2</sup>, Maria A. Chernyadieva<sup>1</sup>, Alina A. Alshevskaya<sup>3</sup>

<sup>1</sup> Department of Spine Surgery for Children and Adolescents, J.L. Tsivyan Research Institute for Traumatology and Orthopaedics, Novosibirsk, Russia

<sup>2</sup> Department of Spine Pathology and Rare Diseases, National Ilizarov Medical Research Traumatology and Orthopaedics Centre, Kurgan, Russia

<sup>3</sup> Biostatistics and Clinical Trials Center, Novosibirsk, Russia

**Corresponding author:** Mikhail V. Mikhaylovskiy, Department of Spine Surgery for Children and Adolescents, Research Institute for Traumatology and Orthopaedics n.u. J.L.Tsyvijan, 17 Frunze St., 630091 Novosibirsk, Russia; E-mail: mmihailovsky@niito.ru; Tel.: +7 913 946 4877

**Received:** 30 June 2020 ♦ **Accepted:** 14 July 2020 ♦ **Published:** 30 Apr 2021

**Citation:** Mikhaylovskiy MV, Ryabykh SO, Suzdalov VA, Filatov EY, Savin DM, Chernyadieva MA, Alshevskaya AA. Final fusion in a complex of surgical treatment for early onset scoliosis. *Folia Med (Plovdiv)* 2021;63(2):264-71. doi: 10.3897/folmed.63.e55955.

## Abstract

**Introduction:** Surgical treatment of early onset scoliosis (EOS) is one of the most challenging problems of spine surgery and includes staged distraction and final fusion at the end of skeletal maturity that remains debatable.

**Aim:** The objective of the review is to evaluate the efficacy of final fusion following staged distraction with VEPTR instrumentation in patients with EOS.

**Materials and methods:** Outcomes of multi-staged operative treatment of 37 patients with EOS of different etiology were reviewed. Medical records and radiographs of the patients were retrospectively analyzed. Standing postero-anterior and lateral spine radiographs were used for the spinal radiologic assessment before and after each stage of distraction-based treatment, before and after final fusion and at the last follow-up.

**Results:** The mean age of patients at baseline was 5.2 years and the mean age at final fusion was 13.9 years. All patients demonstrated decrease in the angle of primary (from 81.5° to 51.6°) and secondary (from 59.3° to 37.8°) curves, increase of the height and normalized body balance. The mean height increased from 104.8 cm to 141.0 cm, and the mean weight increased from 15 kg to 35 kg throughout the treatment period. The height of the thoracic and lumbar vertebra (Th1-S1) increased from 245 mm to 340 mm, and that of the thoracic vertebra – from 136 mm to 193 mm. There was a mean of 2.3 complications per patient during distraction performed in a staged manner, and they were arrested during elective procedures. There were 7 (19%) complications after final fusion that required 6 (16%) unplanned revisions. Radiologic evidence of spontaneous autofusion was seen in the lumbar spine of the patients with the inferior anchor at the lumbar vertebra.

**Conclusions:** Multi-staged pediatric surgeries performed in the first decade of life facilitate radical changes in the natural history of progressive scoliosis and ensure satisfactory functional and cosmetic results despite multiple difficulties and complications. The VEPTR instrumentation used for the thoracic curve is unlikely to result in the spinal fusion of the major arch and this is the cause for the use of third-generation instrumented final spinal fusion in the patients.

## Keywords

early onset scoliosis, final spondylodesis, surgical treatment, VEPTR instrumentation

## INTRODUCTION

Surgical treatment of early onset scoliosis (EOS) is one of the most challenging problems of spine surgery. EOS is defined as curvature of any etiology in children with onset before age 10 years.<sup>1</sup> The current goal in treatment of EOS is to correct spinal deformity while allowing growth of the spine and thorax and subsequently lung growth, with most rapid development in the first 5-8 years of life.<sup>2</sup> Surgical treatment is the option for a more progressive curve detected during the first orthopaedic screening which cannot be treated with serial casting.<sup>3</sup> Early spinal fusion in younger children does not prevent progression of the spinal deformity causing compromised respiratory function and continued spinal growth.<sup>4</sup> In the last few decades, several correcting metal implants have been developed and the systems fall into three categories based upon the forces of correction the implants exert on the spine: distraction-based, compression-based and guided growth systems.<sup>5</sup> Currently, the distraction-based implants are the most common devices used to treat EOS with no fusion to be involved during staged correction. When patients reach skeletal maturity final fusion surgery can be considered for them to maintain spine curve correction. Multi-staged surgical treatment of EOS is associated with frequent complications following distraction-based treatment and final fusion due to a variable severity of the underlying condition and medical comorbidities.<sup>6,7</sup> EOS includes an inhomogeneous grouping of patients with different etiology of the spinal deformity, and many studies are limited by a small number of observations.<sup>8-11</sup> Based on the experience, a surgeon may question if the final fusion is actually needed with the multiple and extensive spontaneous bone block in the spine and ribs developing at the site of distractors.<sup>9,10,12</sup> The authors reporting their series on the problem focus on the need for cumulative experience of the surgical treatment of EOS to establish a unified approach to the solution of the medical challenge.

## AIM

The objective of the review is to evaluate the efficacy of final fusion following staged distraction-based treatment with VEPTR instrumentation in patients with EOS.

## MATERIALS AND METHODS

Our two hospitals have initiated the use of VEPTR instrumentation in spinal surgery in Russia. A total of 140 patients with EOS underwent surgical treatment between 2008 and 2020; 37 of these (up to 2017) had staged distraction-based procedures with VEPTR instrumentation and final fusion using hook-based systems, transpedicular constructs or hybrid instrumentation and autologous bone. Medical records and radiographs of the patients were retrospectively analyzed. Written informed consent was

obtained from the patients' parents for publication of the findings without identifying details. The study received a favourable opinion from the relevant research ethics committee of both institutions.

Patients' demographics (gender, age, height, body weight, etiology of the curve) were recorded. Surgical interventions with the number of staged distractions, unplanned operations performed, the fixation span including instrumentation and bone-plasty zones were reviewed. Standing posteroanterior and lateral spine radiographs were used for the spinal radiologic assessment before and after each stage of distraction-based treatment, before and after final fusion, and at the last follow-up. The Cobb angle of the major arch, the counter curve, thoracic kyphosis, lumbar lordosis, coronal imbalance [a distance in mm between the central sacral vertical line (CSVL) to the centroid of the Th1 vertebra], vertebral body height (between cranial endplates of Th1 and S1 vertebrae), and space available to the lungs were measured in the patients. The mean period following final fusion was 23.8 (range, 6-36) months.

## Statistical analysis

Statistical data analysis was performed using the tools of Microsoft Excel and Statistica 6.0 software package (StatSoft, USA). Preliminary analysis showed normally distributed variable at baseline. For calculations, a significance level of <0.05 was adopted.

## RESULTS

There were 22 girls and 15 boys in the 37 patients who underwent distraction-based program and final fusion surgery. The mean age at the first distraction with VEPTR device was 5.2 years (range, 1-9 years). An interval between staged distractions ranged between 9 to 12 months.

The etiology of the spinal deformity was congenital (n=19), idiopathic (n=7), associated with underlying systemic syndromes (n=5) and neurofibromatosis (n=5) and secondary to a neuromuscular condition (n=1).

All primary curves were localized in the thoracic spine and counter curves (n=12) were detected in the lumbar and upper thoracic spine. The inferior instrumented vertebra included semi-arch of the lumbar vertebra (n=27) and the iliac crest (n=10). Distraction was produced with one rod (n=34) and two rods (n=3). The mean staged distraction surgeries numbered 6.1 (range 1-10). The mean zone spanned with dynamic rods was 11.9 vertebral segments. Two patients with congenital costal autofusion underwent osteotomy of the bone block and a short distractor implanted in a rib-to-rib manner was mounted in addition to the rib-to-spine distractor.

The Cobb angle showed typical dynamics in both the primary and the secondary curves (**Table 1**) with substantial correction resulting from the first distraction-based treatment followed by gradual decrease in the effect achieved

**Table 1.** Results of roentgenogrammetry at stages of operative treatment

	Before first distraction-based procedure	After first distraction-based procedure	Before final fusion	After final fusion	At the last follow-up
Primary curve	81.5° (40°–118°)	54.3° (25°–98°)	71.1° (34°–101°)	52.0° (9°–83°)	51.6° (9°–83°)
Counter curve	59.3° (27°–82°)	43.3° (15°–81°)	47.6° (31°–67°)	37.8° (7°–79°)	37.8° (5°–78°)
Thoracic kyphosis	38.6° (-7°–142°)	29.7° (1°–104°)	54.2° (-12°–139°)	43.1° (6°–99°)	49.4° (20°–72°)
Lumbar lordosis	45.8° (8°–71°)	35.1° (1°–67°)	53.9° (5°–109°)	48.3° (17°–81°)	52.7° (32°–75)
Coronal imbalance (mm)	25 (1–175)	3.4 (8–18)	25 (4–49)	23 (6–59)	17.1 (7–55)

due to progression of the curve regaining the correction with final fusion. The thoracic kyphosis and lumbar lordosis remained within normal values throughout the entire period of observation. Coronal imbalance was amendable to a lesser extent; however, better realignment was demonstrated following the final fusion at a longer term.

The mean age at final fusion was 13.9 years (range, 11–17 years). The mean length of the final fusion was 13.4 (range, 9–16) vertebral segments with 1.5 segments exceeding the zone of instrumented spine during staged treatment. The height of the thoracic and lumbar vertebra (Th1–S1) increased from 245 mm to 340 mm, i.e. by 95 mm (37%) (Table 2). The height of the thoracic vertebra increased from 136 mm to 193 mm, i.e. by 57 mm (41.9%).

**Table 2.** Dynamics in the height of the thoracic and lumbar (Th1–S1) and thoracic (Th1–Th12) spine during multistage operative treatment of patients with EOS

Th1 – S1 (mm)	
Before first distraction-based procedure	245 (139–317)
After first distraction-based procedure	278 (168–348)
Before final fusion	307 (189–403)
After final fusion	338 (202–407)
At the last follow-up	340 (237–409)
Th1 – Th12 (mm)	
Before first distraction-based procedure	136 (59–177)
After first distraction-based procedure	154 (85–196)
Before final fusion	168 (107–215)
After final fusion	194 (113–323)
At the last follow-up	193 (132–251)

The space available for the lungs (SAL) is a ratio expressed as a percentage of the height of the right and left hemithorax.<sup>2</sup> Deterioration of the SAL measured with serial radiographs indicates inhibition of the longitudinal growth of the concave hemithorax and progression of the curve. The SAL in our series was 88.7% (range, 59.8–97.8%) at baseline, 96.1% (range, 63.6–117.6%) after final fusion and 100.2% (range, 68.9–126.6%) at the end of the follow-up period.

The mean height of the patients was 104.8 cm (range, 72–131 cm) before the distraction-based program, 134.9 cm (range, 124–156 cm) before the final fusion and 141.2 cm (range, 127–157 cm) at the latest follow-up; the mean body weight was 15.1 kg (range, 8–20 kg), 35.2 kg (range, 24–54 kg) and 38.5 kg (range, 28–56 kg), respectively. The mean blood loss at the final fusion was 492 mL (range, 300–970 mL), and the average operative time was 291 minutes (range, 195–460 minutes).

## Complications

The complication rate was high during the distraction program: 78 adverse events developed in 33 patients or there was a mean of 2.3 complications per patient. Most of the complications were implant related including rod fractures and displacements, failures of anchors. The adverse outcomes did not seriously affect the patients' condition and were arrested during the next phase of correction or the exchange of implants at final fusion. There were no unplanned returns to the operating room, no unplanned revisions recorded in the cases.<sup>17</sup> Seven complications were detected in 37 patients after final fusion. These included one intraoperative liquorrhea that was stopped intraoperatively and recurred two days later, unstable cranial clamps in two cases, rod fractures in two patients, one DJK, an abnormally fast heart rhythm (supraventricular tachycardia) in one patient. The adverse events required six unplanned revisions. Ribs were additionally resected in two cases, and two patients underwent anterior spinal fusion.

## DISCUSSION

Building the treatment strategy for EOS patients appears to be simple and logical enough. While the child is actively growing (primarily the spinal column and lung parenchyma) the potential capacities must be thoroughly taken care of in an effort to correct the curve. This is important in preventing the thoracic insufficiency syndrome (TIS)<sup>2</sup> and severe incurable scoliosis. Dorsal final or definitive fusion can be performed with the child's lungs fully developed and growth of the locomotor apparatus being close to the phase of skeletal maturity in order to fix the result achieved.

Staged correction program can be accomplished with the use of multiple devices which were classified by Skaggs et al.<sup>5</sup> into three categories based upon the forces of correction the implants exert on the spine: distraction-based systems (TGR, VEPTR, MCGR), compression-based devices (stapling, tethering) and guided growth systems (Shilla, Luque-trolley). Vertical expandable titanium rib prosthesis (VEPTR) has been shown to be most commonly used device that was employed for the treatment of patients in our series. A cumulative experience has been gained and it changed the initial understanding of the author of the method<sup>2</sup> about multistaged treatment of EOS patients. First, the preplanned 6-month intervals between staged distraction-based treatments appeared to be much longer and developed into a 8-9-to-12-month-and-over period.<sup>11,14,15</sup> One of the reasons for that was the repeated general anesthesia in children that might cause detrimental psychosocial effects.<sup>16</sup> Secondly, concerns of scarring and stiffening of the chest wall were likely to reduce effect from each lengthening surgery (a law of diminishing returns<sup>17</sup>). Third, all authors report high rate of complications requiring unplanned revisions.<sup>13</sup> The reported results of multiple studies convincingly demonstrate that modern treatment may improve on the natural history of pathological process of EOS despite the challenges.<sup>9,11,18-20</sup> So, the age at which the distraction program can start is likely to increase demonstrating the surgeon's intention to initiate multistage treatment later to minimize the total number of surgeries.<sup>10,11,13,14,18,19,21,22</sup> The age at the first distraction-based treatment was reported to increase from 4.8 years to 8 years between 2010 and 2018. Our data are completely in line with those reported in the literature with time intervals being more than 6 months – from 9 to 12 months – between staged distractions.

The age of the patients at the time of final fusion ranges within fairly narrow limits<sup>8,10,11,13,14,19</sup>, between 12 to 14.4 years and 14 years of age is viewed as optimal for definitive fusion.<sup>13,23</sup> All surgeons report technical difficulties with the surgery due to soft tissue and skin scarring and spontaneous spinal or costal autofusion. The problem has not been resolved and is to be discussed separately. Spontaneous autofusion was first described in early 1990s but the prevalence and consequences were not reported.<sup>23,24</sup> Cahill et al.<sup>11</sup> described autofusion as a bone block across the segment(s) that was/were not intended to fuse. The nature of autofusion is multifactorial and involves local muscle disorders (muscle cells differentiating into osteoblasts), immobilization, a tendency for immature bone tissue to fuse at the site of microfractures resulting from the distraction forces. It can also be regarded as a normal biological response of immature spine to immobilization. Implant-related ossifications were classified into three types: (1) at anchor points: mainly a harmless biologic reaction to the polyaxiality of the implant anchor and absence of artificial bone block; (2) along the central part: being troublesome in view of their possible negative impact on chest cage compliance and spinal mobility. This potential side effect

needs to be considered during implant selection. Ossifications can be removed or held as a stabilizing structure at the time of implantation of segmented endocorrector; (3) re-ossifications after thoracostomy are not directly related to the implant but rather to the proximity to bleeding bone surfaces in the settings of immobility provided by endocorrector.

Groenefeld et al.<sup>15</sup> reported evident correlation between the extent of correction resulting from the first distraction-based surgery and the occurrence of ossifications. Curve stiffness was reported to correlate with the occurrence of ossifications. Risk of ossification was shown to be associated with multiple surgical procedures and long-term treatment. The process remains unpredictable and uncontrollable with a high incidence of autofusion noted during staged distraction-based surgeries. Cahill et al.<sup>11</sup> reported the occurrence of autofusion in 89% (8 of the 9 patients), Groenefeld et al.<sup>15</sup>, in 48% (27 of the 57 cases), Zivcovic et al.<sup>21</sup>, in 65% (42 of the 65 cases). Surgical strategy for autofusion is however debatable. Multilevel vertebrotomies can be the method of choice for extensive autofusion to gain correction with a higher risk of complications, greater operative time and blood loss.<sup>11</sup> A careful preoperative assessment of autofusion areas can make the fusion procedure unnecessary due to its stabilizing role for the spinal column.<sup>18</sup>

Spontaneous fusion was noted to develop at the site of the distal clamp and at several levels cranial to the latter in our series (these were 27 cases with the lumbar vertebra used as the caudal fixation point). It should be noted that all patients of our series had a primary curve localized in the thoracic spine but no autofusion was detected in the thoracic spine. On the one hand, this was an indication to fusion procedure, but on the other hand, this was the reason to avoid the correcting osteotomy. We have found out it is an important practical aspect.

Final surgical fusion following the distraction program is not the only option to accomplish operative treatment of EOS. Some authors<sup>9,14,20</sup> reported comparative results of two groups of patients who underwent fusion and those who did not (observation group). Jain et al.<sup>9</sup> identified 167 patients who received growing-rod treatment. From them, thirty patients did not undergo final surgical fusion (from an initial curve of 79° to a final magnitude of 41° at a minimum 2-year follow-up after the last surgery). Final fusion was performed for 137 patients (from 74° at baseline to final 46°). The authors concluded that avoiding final surgical fusion at skeletal maturity is a viable option for patients with spontaneous fusion, satisfactory final alignment and trunk height, a minimal gain in length at the last distraction, and no evidence of implant-related problems. Pizones et al.<sup>14</sup> reported a total of 28 patients, of whom 13 underwent fusion and 15 were observed with a mean follow-up of 8.3 years. The Cobb angle finally decreased from 72° to 43° in the spinal fusion group and from 82° to 49° in observation group. Twelve of 13 patients underwent multiple osteotomies. No major complications were observed in the patients. Indications to final fusion include large progressive

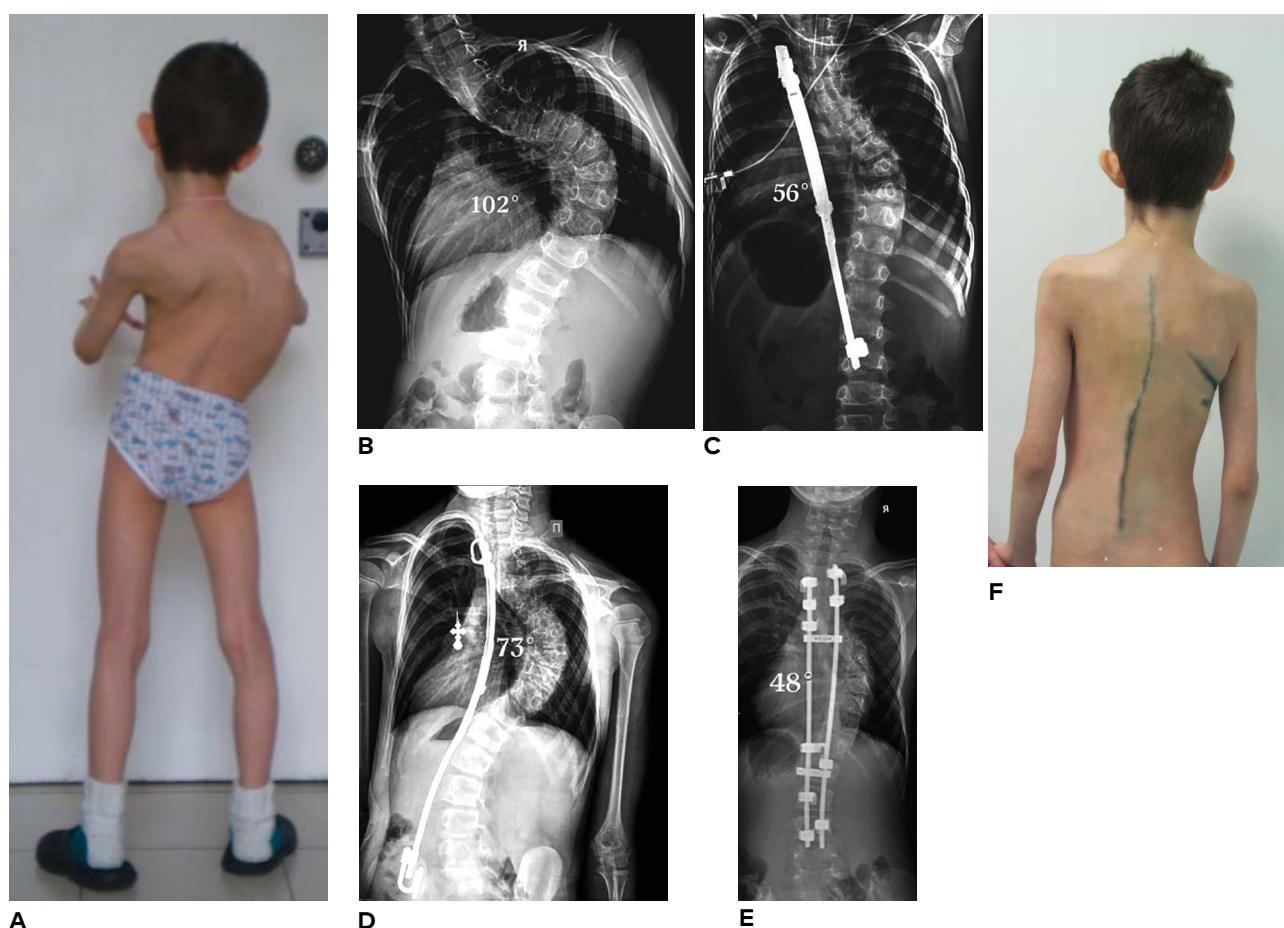


curve, sagittal imbalance, implant related problems. Indications to observation include stable curve less than  $82^\circ$  coronal imbalance of less than 20 mm. Studer et al.<sup>20</sup> treated 34 VEPTR graduates; 17 underwent final fusion surgery, and 17 followed a nonfusion strategy. The authors reported a 41% complication rate (7/17) with final fusion surgery. In cases of severe kyphosis preoperative halo-gravity traction can be recommended before final fusion with family's understanding of final fusion procedure that might happen to be not the last surgery. Removal of the distractor can be an end point for some patients. Olgun et al.<sup>25</sup> suggested the option being unacceptable proposing to leave the distractor or exchange it with another implant.

Lattig et al.<sup>26</sup> and Pizones et al.<sup>14</sup> suggested that the length of final fusion exceeded the spine spanned with distraction rods by 1-2 segments. We observed the same phenomenon in our series. Dynamics in the Cobb angle is not reported elsewhere. The Cobb angles reported by Cahill et al.<sup>11</sup> measured  $72.6^\circ$  preoperatively,  $34.8^\circ$  after the first distraction-based treatment,  $48.7^\circ$  before final fusion and

$24.8^\circ$  after fusion procedure. Measurements of the Cobb angle made by Luhmann et al.<sup>19</sup> were  $64.6^\circ$  preoperatively,  $37.8^\circ$  after the first distraction-based treatment,  $53.4^\circ$  before fusion,  $29.8^\circ$  after fusion procedure and  $35.7^\circ$  at the 7.4-year follow-up. Murphy et al.<sup>22</sup> reported decrease in the initial deformity of  $52.4^\circ$  to  $38^\circ$  before fusion procedure in 13 cases and no substantial correction (more than 51% according to Flynn et al.<sup>8</sup>) could be achieved in the patients. Complications reported by Poe-Kochert et al.<sup>10</sup> included 30 adverse events in 20 patients among 100 patients who underwent spine fusion surgery and required 57 unplanned revisions. Luhmann et al.<sup>19</sup> reported 26 complications in 18 patients after spinal fusion. Sawyer et al.<sup>18</sup> reported 26 complications in 15 patients among 25 patients undergoing fusion that required unplanned surgery in 24%. The authors reported no statistically significant differences in the final outcomes of surgical cases and observation group.

Assessing the type of the curve in our patients with EOS the correction achieved ( $36.7^\circ$  for the major arch and  $36.3^\circ$  for the counter-curve) can be rated as satisfactory (Fig. 1).



**Figure 1.** Photographs and radiographs of an 8-year-old patient with Russel-Silver syndrome, conservative treatment started at 3 years of age. **A)** Preoperative appearance; **B)** Anteroposterior radiographs showing initial scoliosis with the Cobb angle of  $102^\circ$ ; **C)** Radiographs taken after the first distraction-based procedure with the Cobb angle of  $55^\circ$ ; **D)** Radiographs taken at the age of 12 years prior to final fusion following the fifth distraction-based procedure showing the Cobb angle of  $79^\circ$ ; **E)** Radiographs taken after ventral discectomy and final fusion showing the curve with the Cobb angle of  $46^\circ$ ; **F)** Clinical appearance at the last follow-up.

Flynn et al.<sup>8</sup> suggested the percentage correction of less than 20% as minimal, 20% to 50% as moderate and more than 51% as substantial. The height of the spinal column – the distance between the cranial endplates Th1 and S1 vertebrae – increased by 93 mm (37.9%), between Th1 and Th12 by 58 mm (42.6%). Cahill et al.<sup>11</sup> reported increase in Th1-S1 from 255 mm to 368 mm (44%), Luhmann et al.<sup>19</sup> from 181 mm to 233 mm (28.7%), and Pizones et al.<sup>14</sup> reported the minimum of 180 mm. The only parameter that showed minimally positive dynamics in our series was the coronal imbalance. It decreased from 25 mm to 3.4 mm after the first distraction-based surgery, then returned to the baseline value and was nearly normal at a long-term follow-up. Sagittal imbalance data were scarce and could not be used for statistical analysis. Positive dynamics was observed in the SAL in our series.

The literature data show a high complication rate following final fusion. Sawyer et al.<sup>18</sup> reported 26 complications in 25 patients undergoing fusion. Complications reported by Poe-Kochert et al.<sup>10</sup> included 30 adverse outcomes in 20 patients among 100 patients who underwent spine fusion surgery and required 57 unplanned revisions. Luhmann et al.<sup>19</sup> reported 26 complications in 18 patients after spinal fusion. Studer et al.<sup>20</sup> described 65 complications in 34 cases and 40 unplanned returns to the operating room. Our series demonstrated comparatively low complication rate with 7 adverse outcomes and 6 revisions per 37 patients.

## Limitations

The group of our patients is small because VEPTR instrumentation has been available at our hospitals since 2008 due to external circumstances. Our series included an inhomogeneous group of patients for etiological reasons but this is typical for the majority of publications on the issue. There is no control group to include patients undergoing distraction-based treatment with the use of different techniques or exchange of growing rods with segmented instrumentation and fusion or the patients who did not undergo surgical treatment. We cannot rely on a good stabilizing effect of spontaneous autofusion whereas the supporting role of the VEPTR rods can be comparable to that of the segment instrumentation of the third generation.

## CONCLUSIONS

Spinal deformities in the first decade of life, one of the challenges of the spinal surgery, can be addressed with multi-staged operative treatment to facilitate radical changes in the natural history of the condition and ensure satisfactory functional and cosmetic results despite multiple difficulties and complications. Multiple staged distraction-based treatments can often result in an autofusion of vertebral bodies. The use of VEPTR instrumentation for thoracic curve is unlikely to result in the spinal fusion of the major arch and

this is the cause for the use of third-generation instrumented final spinal fusion in the patients to prevent multi-level osteotomies at the site of fusion.

## Authors contribution

M.V.M. is the primary designer and author of the manuscript, S.O.R. carried out a large part of the X-ray investigation and approved the final revision of the manuscript for publication, V.A.S. conducted a significant portion of X-ray studies and statistical analysis, E.Y.F. approved the final revision of the manuscript and data analysis, D.M.S. carried out large part of the clinical data analysis and final revision of the manuscript, M.A.C. carried out a large part of the data analysis, and A.A.A. oversaw the design of methodology and manuscript preparation.

## REFERENCES

1. Skaggs D, Guillaume T, El-Havary R, et al. Early onset scoliosis consensus statement. SRS growing spine committee, 2015. *Spine Deformity*. 2015; 3:107.
2. Campbell R, Smith M, Mayes T, et al. The characteristics of thoracic insufficiency syndrome associated with fused ribs and congenital scoliosis. *J Bone Joint Surg Am* 2003; 85:399–408.
3. Sanders J, Astous J, Fitzgerald M, et al. Derotational casting for progressive infantile scoliosis. *J Pediatr Orthop* 2009; 29:581–7.
4. Karol L. Early definitive spinal fusion in young children. *Clin Orthop Rel Res* 2011; 469:1323–9.
5. Skaggs D, Akbarnia B, Flynn J, et al. A classification of growth friendly spine implants. *J Pediatr Orthop* 2014; 34(3):260–74.
6. Bess S, Akbarnia B, Thompson G, et al. Complications of growing rod treatment for early-onset scoliosis: analysis of one hundred and forty patients. *J Bone Joint Surg Am* 2010; 92(15):2533–43.
7. Parnell S, Effmann E, Song K, et al. Vertical expandable prosthetic titanium rib (VEPTR): a review of indications normal radiographic appearance and complications. *Pediatr Radiol* 2015; 45(4):606–6.
8. Flynn J, Tomlinson L, Pawelek J, et al. Growing-rod graduates: lessons learned from ninety-nine patients who completed lengthening. *J Bone Joint Surg Am* 2013; 95:1745–50.
9. Jain A, Sponseller P, Flynn J, et al. Avoidance of ‘final’ surgical fusion after growing-rod treatment for early onset scoliosis. *J Bone Joint Surg Am* 2016; 98:1073–8.
10. Poe-Kochert C, Shannon C, Pawelek J, et al. Final fusion after growing-rod treatment for early onset scoliosis. Is it really final? *J Bone Joint Surg Am* 2016; 98:1913–7.
11. Cahill P, Marvil S, Cuddihy L, et al. Autofusion in the immature spine treated with rowing rods. *Spine* 2010; 35:E1199–E1203.
12. Ramo B, Richards B. Repeated surgical interventions following “definitive” instrumentation and fusion for idiopathic scoliosis: five years update on a previously published cohort. *Spine* 2012; 37(14):1211–7.
13. Anari J, Flynn J, Cahill P, et al. Unplanned return to OR (UPROR) for children with early onset scoliosis (EOS): a comprehensive evaluation of all diagnoses and instrumentation strategies. *Spine Deformity* 2020; 8:295–302.
14. Pizones J, Martin-Buitrago MP, Marques JMS, et al. Decision mak-

- ing of graduation in patients with early-onset scoliosis at the end of distraction-based programs: risks and benefits of definitive fusion. *Spine Deformity* 2018; 6:308–13.
15. Groenefeld B, Hell A. Ossifications after Vertical Expandable Prosthetic Titanium Rib treatment in children with thoracic insufficient syndrome and scoliosis. *Spine* 2013; 38:E819–E823.
  16. Matsumoto H, Williams B, Corona J, et al. Psychosocial effects of repetitive surgeries in children with early onset scoliosis: are we putting them at risk? *J Pediatr Orthop* 2014; 34(2):172–8.
  17. Sankar W, Skaggs D, Yazici M, et al. Lengthening of dual growing rods and the law of diminishing returns. *Spine* 2011; 36:806–9.
  18. Sawyer J, de Mendonca R, Flynn T, et al. Complications and radiographic outcomes of posterior spinal fusion and observation in patients who have undergone distraction-based treatment for early onset scoliosis. *Spine Deformity* 2016; 4:407–12.
  19. Luhmann S, Smith J, McClung A, et al. Radiographic outcomes of Shilla Growth Guidance System and traditional growing rods through definitive treatment. *Spine Deformity* 2017; 5:277–82.
  20. Studer D, Buchler P, Hasler C. Radiographic outcome and complication rate of 34 graduates after treatment with Vertical Expandable Prosthetic Titanium Rib (VEPTR); a single centre report. *J Pediatr Orthop* 2019; 39(10):e731–e736.
  21. Zivkovic V, Buchler P, Ovidia D, et al. Extraspinal ossifications after implantation of Vertical Expandable Prosthetic Titanium Rib (VEPTRs). *J Child Orthop* 2014; 8:237–44.
  22. Murphy R, Pacult M, Barfield W, et al. Experience with definitive instrumented final fusion after posterior-based distraction lengthening in patients with early-onset spinal deformity: single center results. *J Pediatr Orthop* 2019; 28(1):10–6.
  23. Mardjetko S, Hammerberg K, Lubicky J, et al. The Luque trolley revisited: review of nine cases requiring revision. *Spine* 1992; 17:582–9.
  24. Fisk J, Peterson H, Laughlin R, et al. Spontaneous fusion in scoliosis after instrumentation without arthrodesis. *J Pediatr Orthop* 1995; 15:182–5.
  25. Olgun ZD, Kocyigit A, Eroglu M, et al. Graduation protocol after growing rod treatment: is removal of hardware without new instrumentation a realistic approach? *Spine Deformity* 2016; 4:450.
  26. Lattig F, Taurman R, Hell A. Treatment of early-onset spinal deformity (EOSD) with VEPTR: a challenge for the spinal correction spondylodesis – a case series. *Clin Spine Surg* 2016; 29:E246–E251.

# Финальный спондилодез в комплексе хирургического лечения ранних сколиозов

Михаил В. Михайловский<sup>1</sup>, Сергей О. Рябых<sup>2</sup>, Василий А. Суздалов<sup>1</sup>, Егор Ю. Филатов<sup>2</sup>, Дмитрий М. Савин<sup>2</sup>, Мария А. Чернядьева<sup>1</sup>, Алина А. Альшевская<sup>3</sup>

<sup>1</sup> Отделение детской и подростковой вертебрологии, Научно-Исследовательский Институт Травматологии и Ортопедии им. Я.Л.Цивьяна, Новосибирск, Россия

<sup>2</sup> Отделение позвоночника и редких заболеваний, Национальный Научно-Исследовательский Центр Травматологии и Ортопедии им. Г.А.Илизарова, Курган, Россия

<sup>3</sup> Центр Биостатистики и Клинических Исследований, Новосибирск, Россия

**Адрес для корреспонденции:** Михаил В. Михайловский, Отделение детской и подростковой вертебрологии, Научно-Исследовательский Институт Травматологии и Ортопедии им. Я.Л.Цивьяна, Новосибирск, Россия, ул. Фрунзе №17, 630091 Новосибирск, Россия; E-mail: mmihailovsky@niito.ru; Тел.: +7 913 946 4877

**Дата получения:** 30 июня 2020 ♦ **Дата приемки:** 14 июля 2020 ♦ **Дата публикации:** 30 апреля 2021

**Образец цитирования:** Mikhaylovskiy MV, Ryabikh SO, Suzdalov VA, Filatov EY, Savin DM, Chernyadieva MA, Alshevskaya AA. Final fusion in a complex of surgical treatment for early onset scoliosis. Folia Med (Plovdiv) 2021;63(2):264-71. doi: 10.3897/folmed.63.e55955.

## Резюме

**Введение:** Хирургическое лечение ранних сколиозов – одна из сложнейших проблем вертебрологии. Оно включает программу этапных дистракций и ‘финальный’ спондилодез в возрасте завершения формирования скелета. Отношение к этой операции остается неоднозначным.

**Цель** настоящей публикации – оценка эффективности операции ‘финального’ спондилодеза после этапных дистракций с помощью инструментария VEPTR в группе больных с ранними сколиозами.

**Материалы и методы:** Исследованы результаты многоэтапного оперативного лечения 37 больных с ранними сколиозами различной этиологии. Истории болезней и рентгенограммы этих больных были изучены ретроспективно. Были проанализированы фронтальные и профильные спондилограммы, выполненные в положении стоя до и после каждого этапа дистракции, до и после ‘финального’ спондилодеза и в конце периода наблюдения.

**Результаты:** Средний возраст начала лечения – 5.2 года, средний возраст ‘финального’ спондилодеза – 13.9 года. У всех больных удалось существенно уменьшить величину угла как первичной (с 81.5° до 51.6°), так и вторичной (с 59.3° до 37.8°) сколиотической дуги, добиться увеличения роста и нормализации баланса туловища. Средний рост пациента увеличен за период лечения со 104.8 см до 141 см, средний вес – с 15 кг до 35 кг соответственно. Высота грудного и поясничного отделов позвоночника (Th1-S1) увеличилась с 245 до 340 мм, грудного отдела – со 136 до 193 мм. В ходе этапных дистракций осложнения отмечены со средней частотой 2.3 на одного больного, но все купированы в ходе плановых дистракций. Количество осложнений после выполнения ‘финального’ спондилодеза – 7, количество незапланированных операций – 6. У всех больных с нижней опорой на поясничный позвонок спонтанные костные блоки выявлены только в поясничной области.

**Заключение:** Многоэтапное оперативное лечение детей первой декады жизни с прогрессирующими сколиозами, несмотря на многочисленные трудности и осложнения, позволяет радикально изменить естественное течение заболевания и получать в большинстве случаев вполне удовлетворительный функциональный и косметический результат. При деформациях позвоночника грудной локализации использование инструментария VEPTR не приводит к блокированию позвонков на протяжении основной дуги. Это обстоятельство является обоснованием для выполнения ‘финального’ спондилодеза с использованием инструментария III и позволяет избежать выполнения многоуровневых вертебротомий на уровне формирования спонтанных костных блоков.

## Ключевые слова

ранние сколиозы, хирургическое лечение, инструментарий VEPTR, ‘финальный’ спондилодез