



Sporadic Spinal Schwannomas and Neurofibromas – a Review

Georgi Apostolov¹, Borislav Kitov², Elena Poryazova³, Ivo Kehayov²

¹ Clinic of Neurosurgery, St George University Hospital, Medical University of Plovdiv, Plovdiv, Bulgaria

² Department of Neurosurgery, Faculty of Medicine, Medical University of Plovdiv, Plovdiv, Bulgaria

³ Department of General and Clinical Pathology, Faculty of Medicine, Medical University of Plovdiv, Plovdiv, Bulgaria

Corresponding author: Ivo Kehayov, Department of Neurosurgery, Faculty of Medicine, Medical University of Plovdiv, 15A Vassil Aprilov Blvd., 4002 Plovdiv, Bulgaria; E-mail: dr.kehayov@gmail.com; Tel.: +359 899 105 352

Received: 26 May 2020 ♦ **Accepted:** 15 June 2020 ♦ **Published:** 30 June 2021

Citation: Apostolov G, Kitov B, Poryazova E, Kehayov I. Sporadic spinal schwannomas and neurofibromas – a review. *Folia Med (Plovdiv)* 2021;63(3):309-14. doi: 10.3897/folmed.63.e54750.

Abstract

Tumours arising from the spinal nerve roots are more common in men between the third and fourth decades of life, located mainly in the intradural space of the lumbar region. The clinical symptoms of spinal schwannomas and neurofibromas are similar and depend on the location of the tumour and its relationship to the spinal cord and nerve roots. The pain (radiculalgia and/or vertebralgia) is the earliest symptom, followed by sensory deficit, while motor deficits and sphincter disorders are late symptoms. Magnetic resonance imaging is the diagnostic tool of choice and should be performed when the disease is suspected, as early and accurate diagnosis is essential for treatment outcome. The treatment of these lesions is surgical aiming at total tumour resection that promotes neurological recovery and prevents from recurrences. Subtotal removal also provides favourable outcome but at higher recurrence rates. The aim of this literature review was to study some important characteristics of sporadic spinal schwannomas (SSS) and neurofibromas (SSN), i.e. those not associated with neurofibromatosis type I and II.

Keywords

MRI, neurofibroma, outcome, schwannoma, surgery

INTRODUCTION

About 40% of spinal tumours are intradural extramedullary, 55% are extradural, and 5% are intradural intramedullary.¹ Some of the most common intradural extramedullary neoplasms are the tumours originating from the Schwann cells of the spinal nerve roots, precisely schwannomas and neurofibromas.² These tumours are described together under either the name of schwannomas (neurinomas) or neurofibromas.³ Most of them are benign and show significant cellular maturity, but multiple forms are observed in cases with neurofibromatosis.⁴ Neurofibromatosis type 1 (NF1) has been found to be associated with a defect in the neurofibrin gene in chromosome 17, and neurofibromatosis type 2 – with a defect in the merlin/schwannomin

gene in chromosome 22.³ Neurofibromas are associated primarily with NF1, while schwannomas are associated with NF2.⁴

The aim of this literature review was to study some important characteristics of sporadic spinal schwannomas (SSS) and neurofibromas (SSN), i.e. those not associated with neurofibromatosis type I and type II.

EPIDEMIOLOGY

Primary spinal tumours are relatively rare and account for about 4-6% of all central nervous system (CNS) neoplasms.⁵ Due to differences in the size of the studied population and the classification of neoplasms, the frequency of

different spinal cord tumours varies in the different publications. Although there are many reports on the epidemiology of all CNS tumours, there are significantly fewer reports focused only on the epidemiology of spinal cord tumours.⁶

Sporadic spinal schwannomas account for about 25% of spinal intradural tumours, while neurofibromas account for only 3%.² Solitary SSSs are the most common tumours arising from the nerve sheaths of the spinal nerve roots.⁷ In a large retrospective study involving 678 primary spinal tumours, Hirano et al. found 388 (57.3%) SSS and 23 neurofibromas (3.4%), while the meningiomas were only 79 (11.6%).⁵ Various publications show that in Asian countries, the incidence of tumours originating from the sheaths of the spinal nerve roots (TOSSNR) is higher than that of meningiomas.⁵ This trend is particularly pronounced in East Asian countries, while the incidence of meningiomas in the United States, Europe, and Australia is equal to or greater than that of TOSSNR tumours.⁵

SEX AND AGE

According to McCormick et al., SSSs are distributed equally between the two sexes, and according to Conti et al., they are more common in men.^{8,9} In a study of 367 patients with SSS, Lenzi et al.¹⁰ found a male-to-female ratio of 51.5:49.5%. Hirano et al.⁵ found that out of 388 patients with schwannomas and 23 with neurofibromas, males were 241 (58.7%) while females – 170 (41.3%). Generally, SSSs are observed in middle age, most often in the 4th and 5th decades of life, while SSNs occur at a younger age between 30 and 40 years.^{2,9}

LOCALIZATION

SSS are commonly found in the lumbar region in 25.6% to 60% of the cases.^{1,5,10,11} According to Jinnai et al., the higher incidence of lumbar SSS is due to the anatomical features of the spinal nerves which run a longer distance in the composition of cauda equina.¹² The second most common localization is the thoracic and thoracolumbar regions while Emel et al. report that this is the cervical region.^{1,10,13} Sporadic spinal neurofibromas are more often localized in the cervical region and this frequency varies from 30 to 66%.^{3,14} About 80% of SSS arise from the intradural part of the sensory radices of the nerve roots and present as a globular, well-defined, encapsulated mass, separated from adjacent spinal cord roots.^{15,16} Rarely do SSS arise from the anterior (motor) roots.¹⁷ In about 15% of cases, the SSS cross the dura mater, due to growth of the tumour along the nerve root, forming an intra- and extradural part, or the so-called dumbbell-type tumour¹² (Fig. 1). In contrast to SSS, neurofibromas more often pass through the dura mater into the extradural space, with a frequency ranging from 25% to 66%.^{3,18}

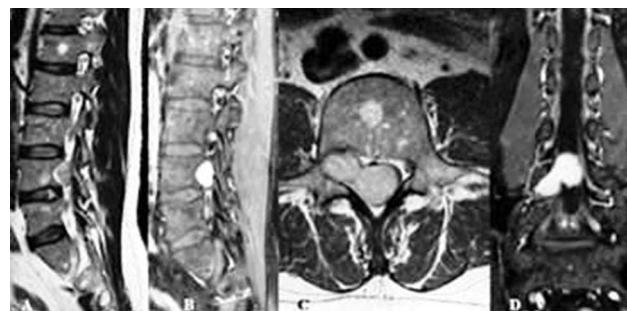

Figure 1. MRI of a schwannoma at the level of L4 vertebra. A) T1 MRI sagittal view without enhancement demonstrating enlargement of the neuroforamen and remodeling of dorsal wall of L4 vertebra; B) – D) Enhanced T1 MRI in sagittal, axial and coronal views show the homogeneous accumulation of contrast and tumour propagation along the L5 nerve root.

HISTOLOGY

Neurinomas and neurofibromas are difficult to distinguish clinically and histologically, so they are often described together as tumours of the nerve sheaths.¹⁶ Sporadic spinal schwannomas and SSN belong to a large category of tumours originating from the Schwann's sheath of peripheral nerves, but differ in their etiology, location and histology.¹⁹ The majority of SSSs are benign tumours with cell maturity with rounded solid shape, and contain Antoni A and Antoni B type cells¹ (Fig. 2). They contain benign neoplastic Schwann cells, while neurofibromas are composed of a mixture of Schwann cells, perineural cells, and fibroblasts, interconnected with nerve fibers and myxoid matrices²⁰ (Fig. 3). Sporadic spinal neurofibromas can be nodular and well-demarcated or diffuse, with intraneural neurofibromas usually growing along the length of the nerve.²¹ At certain sites, SSNs may contain Antoni B cell types, but unlike SSS, Antoni A cell types and hyalinized blood vessels are absent,

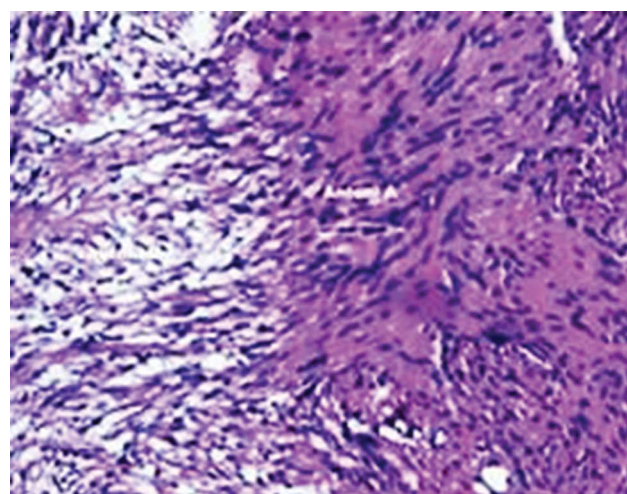


Figure 2. Schwannoma with Antoni A and Antoni B regions. The hypercellular Antoni A region on the right of the field contrasts with the poorly organized hypocellular Antoni B region on the left of the field (hematoxylin-eosin, × 400).

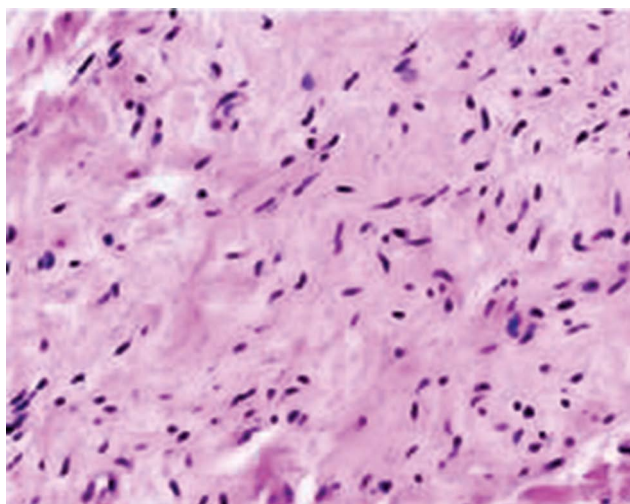


Figure 3. Neurofibroma. Improperly arranged small groups of spindle cells. The cells have a sparse cytoplasm and oval elongated nuclei. Eosinophilic zones with collagen fibers are visible between them. Fibroblasts and mast cells are present. Nucleoli are not visible. Hypercellular areas are missing (hematoxylin-eosin, $\times 200$).

with the cellular component of Schwann cells expressing the S100 and SOX10 proteins.²¹ The highly cellular, monomorphic neurofibromas with nuclear atypism and random mitotic figures are atypical. Microscopic examinations of the nerve roots from which SSS originate show that they, as well as the feeding artery, are usually unaffected by the pathological process, although its axons are abundant in both the tumour capsule and tumour tissue.²² It is suspected that the affected spinal nerve root conduction is gradually deactivated, and its functions are slowly compensated by the surrounding roots.^{22,23} This statement explains why the postoperative neurological deficit is limited or absent, when the spinal nerve root from which the tumour originates is cut. A study by Celli et al. indicates that a significant number of patients with postoperative deficits show a partial or complete recovery after several months or years.¹¹

CLINICAL PRESENTATION

The duration of complaints before diagnosis varies from 3-4 weeks to 2 or more years, while in the series of Celli et al. the longest period is 6 years.^{11,16}

The clinical symptoms of SSS and SSN are similar and depend on the location of the tumour and its relationship to the spinal cord and nerve roots. The pain (radiculargia and/or vertebralgia) is reported as the earliest symptom, followed by sensory deficit, while the motor deficits and sphincter disorders are late symptoms.^{9,12} Initially, the local pain is due to impaired nerve conduction as a result of a direct or indirect irritation of the nerve root or its compression by the tumour.^{11,24}

In SSS and SSN, radicular pain is the first symptom in 49 to 75% of cases, the most common symptom in 72 to 85%, and the only symptom in 30%.¹¹ Lenzi et al. found presence

of radiculopathy in 58.3% of cases, vertebralgia in 39.8%, myelopathy in 22.8%, and sphincter disorders in 13.6%.¹⁰

DIAGNOSIS

The final diagnosis of SSS and SSN is made on the basis of clinical findings and magnetic resonance imaging (MRI) results, which is the diagnostic method of choice.² MRI visualizes the size, location, presence of cystic degeneration and the relationship of the tumour to the surrounding structures. MRI images in spinal schwannomas and neurofibromas are similar, being hypointense in T1 and moderately hyperintense in T2. In some cases, lower-intensity focal areas associated with intralesional hemorrhages or collagen depositions, as well as higher intensity focal regions corresponding to cystic regions, are observed in T2 sequences (Figs 4, 5). After enhancement, a homogene-

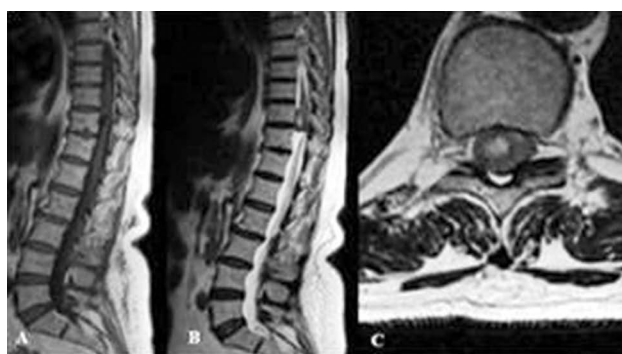

Figure 4. MRI of a schwannoma at the level of Th10-Th11: A) Sagittal view in T1 – isointense signal; B – C) Sagittal and axial views in T2 – moderate hyperintensity with a focal area with higher signal intensity.

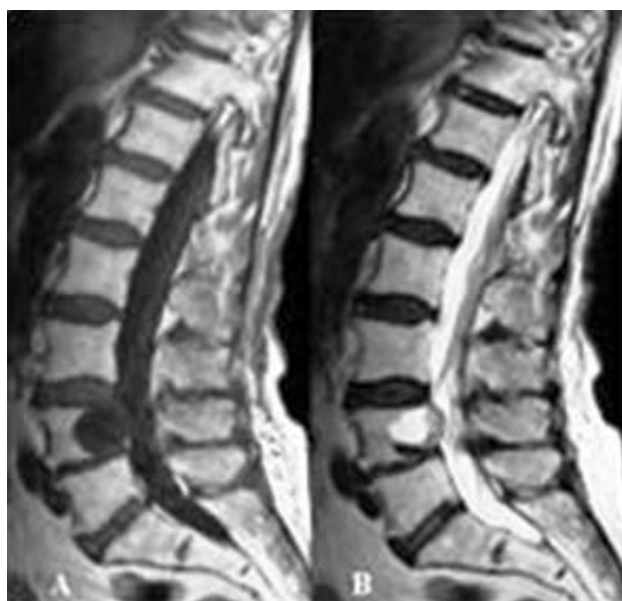

Figure 5. Sagittal MRI views of a neurofibroma at the level of L4: A) T1 – hypointense signal; B) T2 – hyperintense signal with a focal zone of hypointense signal.

ous or non-homogeneous accumulation of contrast in the tumour is visualized. Spinal schwannomas and neurofibromas have an irregular configuration and can accumulate contrast in the periphery of the tumour (**Fig. 6B**). Asano et al. found that there is a greater amount of fluid in the Antoni B type SSS which makes them prone to cystic degeneration.²⁵ Computed tomography (CT) is able to visualize enlargement of the intervertebral foramen and erosion of the pedicles and vertebral bodies (**Fig. 7**). Schwannomas are usually nodular and have a well-defined capsule which is not always typical of neurofibromas. In some neurofibromas, T2 MRI can demonstrate a central stellate part with low signal intensity that remains non-enhanced, which is caused by the presence of nerve fibers within the tumour (**Fig. 6**). There is a diagnostic test for schwannomas

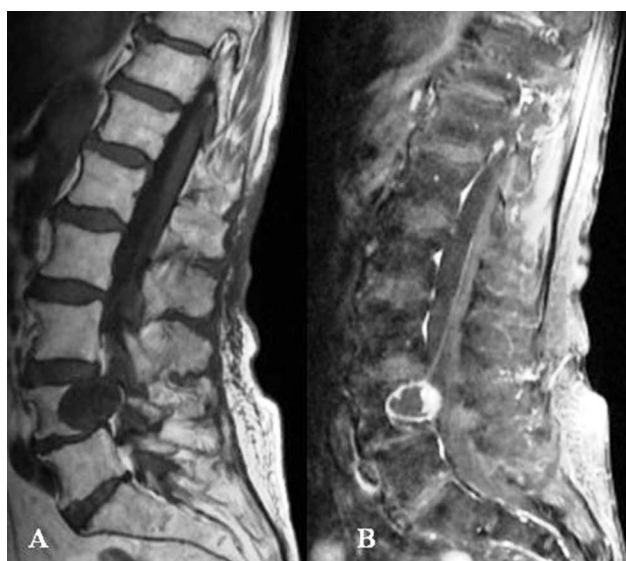

Figure 6. Sagittal MRI views of a neurofibroma at the level of L4: **A)** T1 without enhancement – hypointense signal; **B)** T1 with contrast – peripheral accumulation of contrast material.

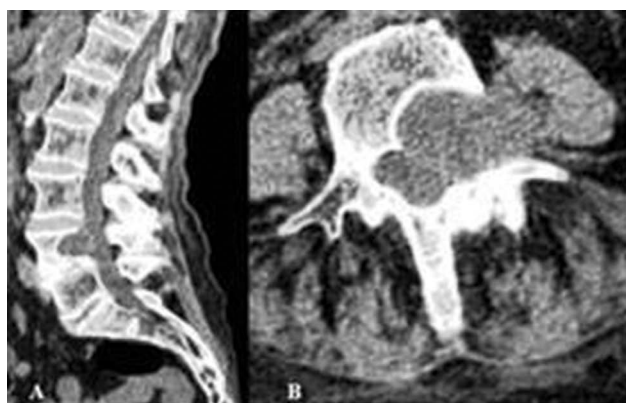


Figure 7. CT of a neurofibroma at the level of L4: **A)** The sagittal reconstruction visualizes the erosion of the posterior wall of the vertebral body; **B)** The axial view shows erosion of the pedicle and arch and expansion of the neuroforamen.

which is based on several parameters: craniocaudal location, presence of hyperintense and/or heterogeneous signal in the T2-weighted MRI, and heterogeneous accumulation of contrast material in the tumour.²⁶ This test supports the diagnosis of SSS with a sensitivity of 96.4% and a specificity of 83.3%.²⁶

TREATMENT

The gold standard of treatment for schwannomas and neurofibromas is total resection, which promotes complete neurological recovery of patients and reduces the recurrence rates.¹⁰ The posterior approach is most commonly utilized by performing laminectomy and incision of the dura mater.^{27,28} Subsequent development of instability and deformity due to extensive bone removal may require posterior instrumentation.¹ Although laminoplasty reduces spinal instability, it cannot be completely avoided.¹ Therefore, whenever possible, less destructive approaches such as hemilaminectomy should be employed to remove such tumours. Modified posterior accesses are used for large and dumbbell-type tumours.²⁷⁻²⁹ The main goal of surgery is to remove the tumour without damaging surrounding neural structures while avoiding spinal instability.^{28,30} In some dumbbell-type tumours spreading into the paraspinal thoracic space, the approach has to be widened by performing a costotransversectomy.^{27,29} The specific surgical approach and the size of the bone window used must take into account the location of the tumour and the size of its extradural component.^{9,24,27}

Even for the most skilled spinal surgeons, there is a risk of postoperative neurological deterioration after a surgical intervention due to SSS and SSN. In recent years, intraoperative neurophysiological monitoring in spinal surgery has become extremely important. It enables the surgeon to safely perform total tumour removal without damage to important anatomical structures.¹⁰ Tumours in the subaxial cervical spine can be accessed via anterior, anterolateral or in combination with posterior approach.¹¹ Radiotherapy is the second treatment option for patients in whom surgery is contraindicated, or in the presence of recurrence.³¹

PROGNOSIS

The prognosis of spinal schwannomas and neurofibromas depends on early diagnosis and adequate surgical intervention, as well as on their histological characteristics and location. In general, postoperative outcome is favourable.^{1,32} In some difficult cases, total resection is not possible.^{7,13} Obstacles to total resection are the presence of dense adhesions between the tumour and spinal cord due to hemorrhage, inflammation or subpial invasion as well as the involvement of major vessels by extradural expansion of the tumour.³³ Giant tumours that violate bone structures and facet joints also pose a challenge to the surgeon. Some

studies have shown that the deficit caused by resecting the nerve root invaded by the tumour is usually not definitive and is well tolerated by patients.³ Recurrences are usually associated with subtotal resection, but such after total resection have also been reported.¹³

CONCLUSIONS

Tumours arising from the sheaths of the spinal nerve roots are one of the most common primary spinal tumours, with schwannomas being more frequent than neurofibromas. They are predominantly benign, slow-growing tumours that affect males more often and debut with radiculargia and/or vertebralgia and sensory disturbances, but over time can cause significant neurological deficits. MRI is the diagnostic tool of choice and should be performed when the disease is suspected because early and accurate diagnosis is essential for the outcome of treatment. The total tumour removal promotes recovery and prevents from recurrence. Subtotal removal also provides favourable outcome but at higher recurrence rates.

REFERENCES

- Canbay S, Hasturk AE, Basmaci M, et al. Management of thoracic and lumbar schwannomas using a unilateral approach without instability: an analysis of 15 cases. *Asian Spine Journal* 2012; 6(1):43–49.
- Engelhard HH, Villano JL, Porter KR, et al. Clinical presentation, histology, and treatment in 430 patients with primary tumors of the spinal cord, spinal meninges, or cauda equina. *J Neurosurg Spine* 2010; 13:67–77.
- Seppälä MT, Haltia MJ, Sankila RJ. Long-term outcome after removal of spinal neurofibroma. *J Neurosurg* 1995; 82:572–77.
- Holland K, Kaye AH. Spinal tumors in neurofibromatosis-2: management considerations – a review. *J Clin Neurosci* 2009; 16:169–77.
- Hirano K, Imagama S, Sato K, et al. Primary spinal cord tumors: review of 678 surgically treated patients in Japan. A multicenter study. *European Spine Journal*, 2012; 21(10):2019–26.
- Schellinger KA, Propp JM, Villano JL, et al. Descriptive epidemiology of primary spinal cord tumors. *J Neurooncol* 2008; 87:173–79.
- Li P, Zhao F, Zhang J, et al. Clinical features of spinal schwannomas in 65 patients with schwannomatosis compared with 831 with solitary schwannomas and 102 with neurofibromatosis type 2: a retrospective study at a single institution. *Journal Neurosurg Spine* 2016; 24(1):145–54.
- McCormick PC, Post KD, Stein BM. Intradural extramedullary tumors in adults. *Neurosurg Clin N Am* 1990; 1:591–608.
- Conti P, Pansini G, Mouchaty H, et al. Spinal neurinomas: retrospective analysis and long-term outcome of 179 consecutively operated cases and review of the literature. *Surg Neurol* 2004; 61:34–43.
- Lenzi J, Anichini G, Landi A, et al. Spinal nerves schwannomas: experience on 367 cases – historic overview on how clinical, radiological, and surgical practices have changed over a course of 60 years. *Neurol Res Int* 2017;2017:3568359.
- Celli P, Trillò G, Ferrante L. Spinal extradural schwannoma. *J Neurosurg Spine* 2005; 2:447–56.
- Jinnai T, Hoshimaru M, Koyama, T. Clinical characteristics of spinal nerve sheath tumors: analysis of 149 cases. *Neurosurgery* 2005; 56(3):510–15.
- Emel E, Abdallah A, Sofuoglu OE, et al. Long-term surgical outcomes of spinal schwannomas: retrospective analysis of 49 consecutive cases. *Turk Neurosurg* 2017; 27(2):217–25.
- Levy WJ, Latchaw J, Hahn JF, et al. Spinal neurofibromas: a report of 66 cases and a comparison with meningiomas. *Neurosurgery* 1986; 18:331–4.
- Banczerowski P, Veres R, Vajda J. Modified surgical approach to cervical neurinomas with intraforaminal components: minimal invasive facet joint sparing open-tunnel technique. *Journal of Neurological Surgery, Part A: Central European Neurosurgery* 2014; 75(1):16–9.
- Ito K, Aoyama T, Miyaoka Y, et al. Surgical strategies for cervical spinal neurinomas. *Neurol Med Chir (Tokyo)* 2015; 55:557–63.
- Safae MM, Lyon P, Barbaro HM, et al. Neurological outcomes and surgical complications in 221 spinal nerve sheath tumors. *J Neurosurg Spine*, 2017; 26(1):103–11.
- Sanguinetti C, Specchia N, Gigante A, et al. Clinical and pathological aspects of solitary spinal neurofibroma. *J Bone Joint Surg (Br)* 1992; 75:141–47.
- Samii M, Giordano M. Spinal schwannomas. In: Arnautović KI, Gokaslan ZL, editors. *Spinal Cord Tumors*. Springer 2018; p 161–69.
- Pilavaki M, Chourmouzi D, Kiziridou A, et al. Imaging of peripheral nerve sheath tumors with pathological correlation: pictorial review. *Eur J Radiol* 2004; 52:229–39.
- Bienkowski M, Furtner J, Hainfellner JA. Clinical neuropathology of brain tumors. In: Aminoff MJ, Boller F, Dick F, editors. *Handbook of clinical neurology*. Swaabvolume Elsevier 2018; 145:477–534.
- Hasegawa M, Fujisawa H, Hayashi Y, et al. Surgical pathology of spinal schwannomas: a light and electron microscopic analysis of tumor capsules. *Neurosurgery* 2001; 49(6): 1388–93.
- Hasegawa M, Fujisawa H, Hayashi Y, et al. Surgical pathology of spinal schwannoma: has the nerve of its origin been preserved or already degenerated during tumor growth? *Clinical Neuropathology*, 2005; 24(1):19–25.
- Park SC, Chung SK, Choe G, et al. Spinal intraosseous schwannoma: A case report and review. *J Korean Neurosurg Soc* 2009; 46:403–8.
- Asano K, Kubo O, Tajika Y, et al. A clinico-pathological study of cystic spinal schwannomas. *No To Shinkei* 1996; 48:245–51.
- De Verdellan O, Haegelen C, Carsin-Nicol B, et al. MR imaging features of spinal schwannomas and meningiomas. *J Neuroradiol* 2005; 32:42–49.
- Sim JE, Noh SJ, Song YJ, et al. Removal of intradural-extramedullary spinal cord tumors with unilateral limited laminectomy. *J Korean Neurosurg Soc* 2008; 43:232–36.
- Agrawal A, Srivastava S, Joharapurkar SR, et al. Single stage complete excision of large thoracic dumbbell schwannoma by modified posterior approach. *Surg Neurol* 2008; 70:432–36.
- Nakamura H, Komagata M, Nishiyama M, et al. Resection of a dumbbell-shaped thoracic neurinoma by hemilaminectomy: a case report. *Ann Thorac Cardiovasc Surg* 2007; 13:36–39.
- Choudry Q, Younis F, Smith RB. Intraosseous schwannoma of D12 thoracic vertebra: diagnosis and surgical management with 5-year follow-up. *Eur Spine J* 2007; 16 Suppl 3:283–86.
- Shin D-W, Sohn M-J, Kim H-S, et al. Clinical analysis of spinal stereotactic radiosurgery in the treatment of neurogenic tumors. *J Neuro-*

- surg Spine 2015; 23(4):429–37.
32. Safavi-Abbasi S, Senoglu M, Theodore N, et al. Microsurgical management of spinal schwannomas: evaluation of 128 cases. J Neurosurg Spine 2008;9:40–47.
33. Jeon JH, Hwang HS, Jeong JH, et al. Spinal schwannoma; analysis of 40 Cases. J Korean Neurosurg Soc 2008; 43(3):135–38.

Спорадические шванномы и нейрофибромы позвоночника – обзор

Георги Апостолов¹, Борислав Китов², Елена Порязова³, Иво Кехайов²

¹ Клиника нейрохирургии, УМБАЛ „Св. Георги“, Медицинский университет – Пловдив, Пловдив, Болгария

² Кафедра нейрохирургии, Факультет медицины, Медицинский университет – Пловдив, Пловдив, Болгария

³ Кафедра общей и клинической патологии, Факультет медицины, Медицинский университет – Пловдив, Пловдив, Болгария

Адрес для корреспонденции: Иво Кехайов, Кафедра нейрохирургии, Факультет медицины, Медицинский университет – Пловдив, Пловдив, бул. „Васил Априлов“ №15А, 4002 Пловдив, Болгария; E-mail: dr.kehayov@gmail.com; Тел.: +359 899 105 352

Дата получения: 26 мая 2020 ♦ **Дата приемки:** 15 июня 2020 ♦ **Дата публикации:** 30 июня 2021

Образец цитирования: Apostolov G, Kitov B, Poryazova E, Kehayov I. Sporadic spinal schwannomas and neurofibromas – a review. Folia Med (Plovdiv) 2021;63(3):309-14. doi: 10.3897/folmed.63.e54750.

Резюме

Опухоли, возникающие из корешков спинномозговых нервов, чаще встречаются у мужчин в возрасте от 30 до 40 лет и располагаются в основном в интрадуральном пространстве поясничной области. Клинические симптомы шванном и нейрофибром позвоночника схожи и зависят от локализации опухоли и её связи с позвоночником и нервными корешками. Боль (радикулалгия и / или вертебралгия) – это самый ранний симптом, за которым следует сенсорный дефицит, в то время как двигательный дефицит и нарушения сфинктера – поздние симптомы. Магнитно-резонансная томография является предпочтительным диагностическим инструментом и должна быть назначена при подозрении на заболевание, поскольку ранняя и точная диагностика имеет решающее значение для результата лечения. Лечение этих поражений является хирургическим и направлено на полную резекцию опухоли, которая поддерживает неврологическое восстановление и предотвращает рецидив. Промежуточное удаление также обеспечивает благоприятный исход, но с более высокой частотой рецидивов. Целью обзора литературы было изучить некоторые важные особенности спорадических шванном позвоночника (СШП) и нейрофибром (СНП), т.е. те, которые не связаны с нейрофиброматозом 1 и 2 типа.

Ключевые слова

МРТ, нейрофиброма, исход, шваннома, операция