



Unexpected Hearing Improvement after Treatment with Valganciclovir in a Child with Congenital Cytomegalovirus Infection

Silvia Palma¹, Laura Mazzoni², Maria Federica Roversi³, Cecilia Botti⁴, Daniele Monzani², Alberto Berardi³, Elisabetta Genovese²

¹ Audiology, Primary Care Unit, Modena, Italy

² Audiology, Department of Diagnostic, Clinical and Public Health Medicine, University of Modena and Reggio Emilia, Modena, Italy

³ Neonatal Intensive Care Unit, Department of Medical and Surgical Sciences of the Mother, Children and Adults, University of Modena and Reggio Emilia, Modena, Italy

⁴ PhD Program in Clinical and Experimental Medicine, University of Modena and Reggio Emilia, Modena, Italy

Corresponding author: Cecilia Botti, PhD Program in Clinical and Experimental Medicine, University of Modena and Reggio Emilia, Via del Pozzo, 41125 Modena, Italy; E-mail: botceci@gmail.com; Tel.: +39 059 4222402

Received: 24 May 2020 ♦ **Accepted:** 2 July 2020 ♦ **Published:** 30 Apr 2021

Citation: Palma S, Mazzoni L, Roversi MF, Botti C, Monzani D, Berardi A, Genovese E. Unexpected hearing improvement after treatment with valganciclovir in a child with congenital cytomegalovirus infection. *Folia Med (Plovdiv)* 2021;63(2):297-301. doi: 10.3897/folmed.63.e54665

Abstract

A 32-week preterm-born male with symptomatic congenital cytomegalovirus infection was treated with valganciclovir. He was also affected by congenital severe bilateral hearing loss and, unexpectedly, a normalization of the hearing threshold was reached at one year of age. The improvement of hearing level in relationship with both the late development of the auditory system and the administration of antiviral therapy is discussed. This case also highlights the importance of early diagnosis of congenital cytomegalovirus associated with close follow-up.

Keywords

CMV, congenital, cytomegalovirus, hearing, hearing loss, valganciclovir

INTRODUCTION

Cytomegalovirus (CMV) is the most frequent etiologic agent of congenital infection. Approximately 40%-60% of symptomatic infants will develop permanent sequelae of variable severity.¹ Hearing loss is the most common sequelae and it may be present at birth or late onset, mono- or bilateral, fluctuating or progressive.^{2,3} Treatment with valganciclovir is an accepted treatment option for children with symptomatic congenital CMV infection involving the central nervous system.⁴ Moreover, valganciclovir seems to be effective in improving hearing dysfunction in infants with congenital CMV (cCMV) infection, with the excep-

tion of forms of severe hearing loss.⁵ We report a case of a preterm newborn with cCMV infection affected by bilateral severe hearing loss with threshold improvement after antiviral therapy.

CASE REPORT

This male born abroad was delivered at 32 weeks gestational age for unstoppable labour via caesarean section. A prenatal ultrasound brain scan and a fetal MRI showed cerebral lesions compatible with cCMV infection. The detection of viral deoxyribonucleic acid (DNA) copies in the

amniotic fluid by quantitative polymerase chain reaction (PCR)-based assays had indicated the diagnosis of cCMV infection. Forty-five days after birth, the infant was referred to our Neonatal Unit and 4.477.830 viral DNA copies/mL were found at urine analysis and 3.837 copies/mL were found in blood samples by quantitative PCR-based assays. Neurological evaluation found rigid spontaneous motility, stereotypical cramped synchronized movements, with increased upper and lower girdle muscle tone. Blood tests revealed total bilirubin 14.82 mg/dL, direct bilirubin 12.76 mg/dL, AST 162 U/L, ALT 118 U/L, gamma-GT 491 U/L. Antiviral treatment with valganciclovir syrup (16 mg/kg BID) was administered for 6 weeks. Magnetic resonance imaging (MRI) performed at 3 months of age showed a subependymal cyst in the right temporal pole (Fig. 1A) associated with changes in the signals of the related white matter. At one-year follow-up, cerebral MRI was normal (Fig. 1B), and the research of viral DNA copies at the urine analysis was negative.

The first auditory evaluation was performed at two months of age, twelve days after the beginning of antiviral therapy. Transient evoked otoacoustic emissions (TEOAEs) failed bilaterally. Auditory brainstem responses (ABR) showed the presence of a V wave up to an intensity of 80 dB nHL of stimulus in the right ear, while in the left the presence of a wave V was not identified (Fig. 2). All subsequent hearing evaluations are reported in Table 1. Otoscopy and tympanometry were normal at every evaluation. Considering the clinical history of the child and the audiological evaluation, air conduction hearing aids were prescribed at 5

months of age with an initial low gain. At six months of age, the hearing-aids amplification was modified and rehabilitative speech therapy was started. At a further evaluation, the mother reported irregular use of the hearing aids and the child's continued attempts to remove them. The child began babbling and speaking his first words at 11 months of age. At 11 months the hearing aids were discontinued. The speech therapist indicated good comprehension of the Italian language (the child was exposed to bilingualism).

The child is still in follow-up according to guidelines as auditory threshold can fluctuate over time.³

DISCUSSION

Threshold improvements have been reported in congenitally infected infants even without antiviral treatment⁶⁻⁸ but not often in symptomatic cCMV children or in case of hearing loss of severe entity. In particular, in case series with children treated with antiviral therapy, it was found that the probability of hearing loss was inversely related to the severity of the impairment at birth.⁹ Therefore, a normalization of the hearing threshold was not expected as the child presented symptoms and lesions of cCMV infection documented by cerebral MRI. This clinical condition prompted the decision to suggest the very early use of hearing aids, delayed intervention being unjustified. In fact, the second audiological evaluation indicated a possible slight fluctuation of the hearing but the third still indicated a severe bilateral hearing loss.

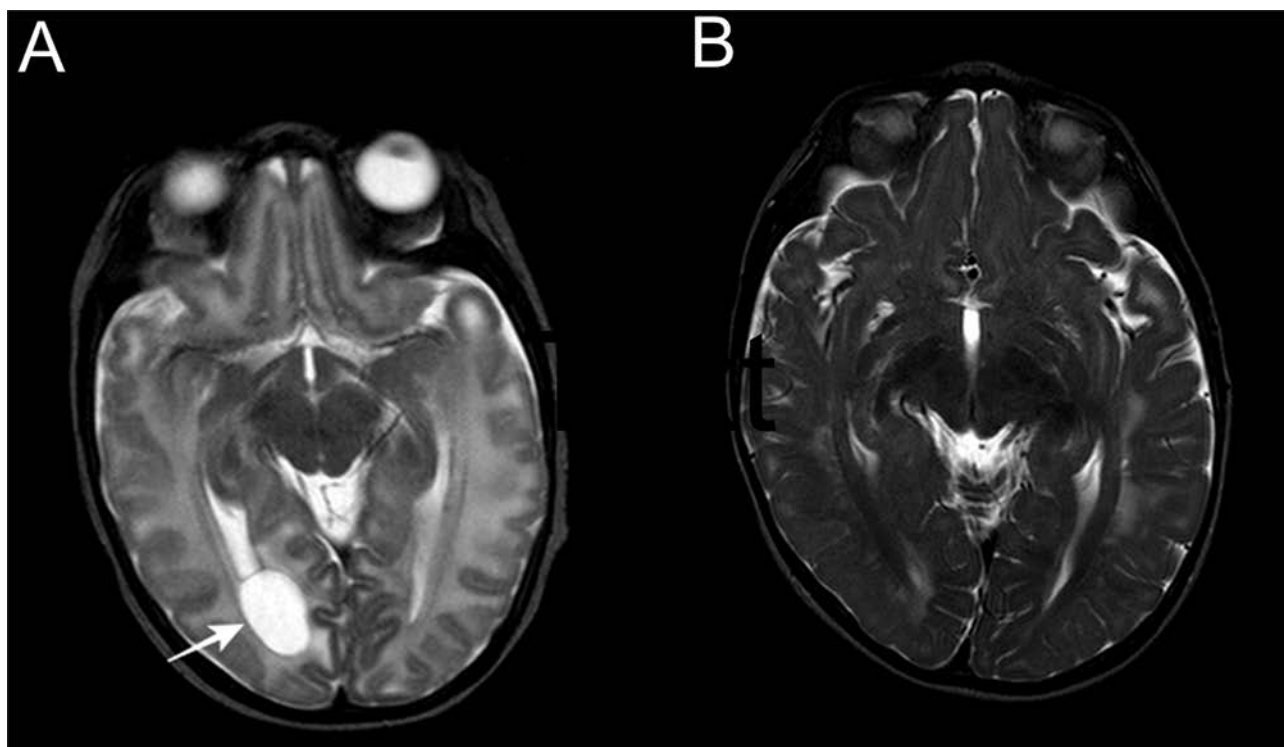


Figure 1. MRI brain scan: **a)** cystic lesion (arrow) (max. diameter 12 mm) in the right temporal pole, very close to the temporal horn of the right ventricle; **b)** one year later, the absence of the lesion can be noted.

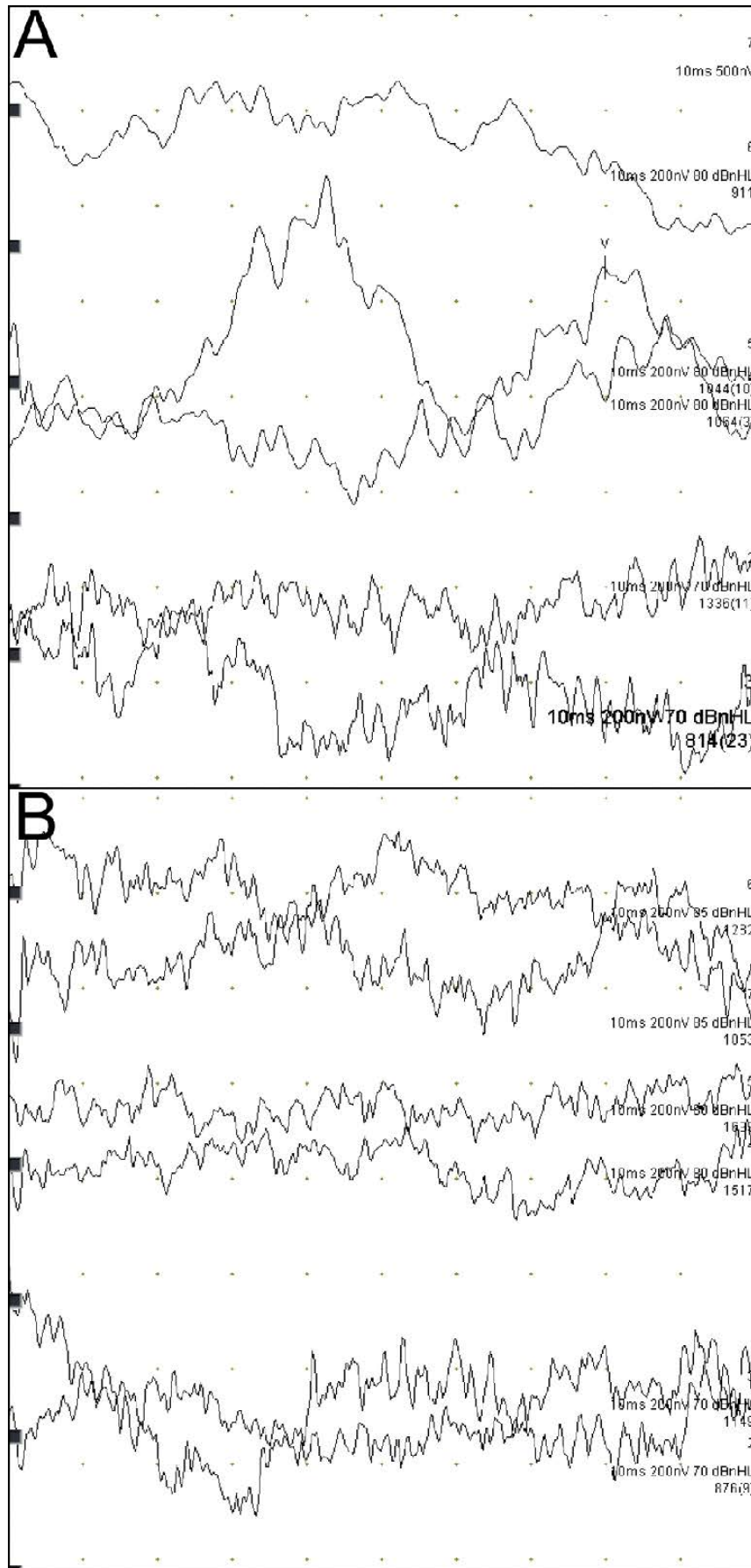


Figure 2. Auditory brainstem responses: A. right ear; B. left ear.

Table 1. Hearing evaluations

Age	TEOAEs		ABR (dB nHL)		VRA (1-4 KHz)
	Right	Left	Right	Left	
2 months	Refer	Refer	80	Absent	
3 months	Refer	Refer	70	80	
4 months + 10 days	Refer	Refer	70	80	
6 months			65	60	
8 months					40 dB HL
11 months	Refer	Pass			35 dB HL
13 months					30 dB HL
2 years					30 dB

TEOAEs: transient evoked otoacoustic emission; ABR: auditory brainstem responses (ABR is detected in spontaneous sleep in a sound proofed room, with TDH39\49 headphones, broadband click stimuli of 100 ms, alternating polarity, with a repetition rate of 21 p/s; wave latency is compared to the normative data established by Cox4; replication of responses is always performed); VRA: visual reinforcement audiometry (warble stimulus/narrow band noise stimulus at 90° azimuth)

In the case presented, we should take into consideration a delay in the development of the auditory system, as the auditory nerve is usually completely mature in a term newborn, with the exception of the fibers related to high frequencies which become completely mature during the first post-natal trimester.¹⁰ However, it is not possible to clearly distinguish between the effects of the antiviral treatment and late development of the hearing apparatus.

Given the influence that speech and environment have on the gradual determination of neural connections of the auditory pathway¹¹, whose development is characterized by continuous synaptogenesis and myelination of the nerves, rehabilitative treatment was important to guarantee hearing function.

It might be hypothesized that both auditory rehabilitation and antiviral therapy could have contributed to the good functional result. However, the normalization of cerebral MRI lesions suggests the positive effect of valganciclovir.⁹

CONCLUSION

In the case reported a preterm newborn with cCMV infection showed a threshold improvement after antiviral therapy with valganciclovir. We might hypothesize that both antiviral therapy and auditory rehabilitation could have contributed to the good functional result. However, further research is mandatory in order to confirm the positive effect of valganciclovir on hearing function. This case also highlights the importance of early diagnosis of cCMV infection associated with close follow-up.

Funding

None.

Conflicts of interest

None.

Acknowledgements

None.

Ethical statement

This research was conducted in accordance with the World Medical Association Declaration of Helsinki (2002). Informed consent of the parents was obtained.

ICMJE Statement

All authors meet the ICMJE authorship criteria.

REFERENCES

1. Dollard SC, Grosse SD, Ross DS. New estimates of the prevalence of neurological and sensory sequelae and mortality associated with congenital cytomegalovirus infection. *Rev Med Virol* 2007; 17(5):355–63.
2. Dahle AJ, Fowler KB, Wright JD, et al. Longitudinal investigation of hearing disorders in children with congenital cytomegalovirus. *J Am Acad Audiol* 2000; 11(5):283–90.
3. Foulon I, De Brucker Y, Buyl R, et al. Hearing loss with congenital Cytomegalovirus infection. *Pediatrics* 2019; 144(2):e20183095.
4. Kimberlin DW, Jester PM, Sánchez PJ, et al. Valganciclovir for symptomatic congenital cytomegalovirus disease. *N Engl J Med* 2015; 372(10):933–43.
5. Ohshima S, Morioka I, Fukushima S, et al. Efficacy of valganciclovir

- treatment depends on the severity of hearing dysfunction in symptomatic infants with congenital cytomegalovirus infection. *Int J Mol Sci* 2019; 20(6):1388.
6. Iwasaki S, Yamashita M, Maeda M, et al. Audiological outcome of infants with congenital cytomegalovirus infection in a prospective study. *Audiol Neurotol* 2007; 12:31–6.
 7. Kashiwagi Y, Kawashima H, Nakajima J, et al. Efficacy of prolonged valganciclovir therapy for congenital cytomegalovirus infection. *J Infect Chemother* 2011; 17(4):538–40.
 8. Bovo R, Trevisi P, Ghiselli S, et al. Is very early hearing assessment always reliable in selecting patients for cochlear implants? A case series study. *Int J Ped Otorhinolaryngol* 2015; 79(5):725–31.
 9. Bilavsky E, Shanar-Nissan K, Pardo J, et al. Hearing outcome of infants with congenital cytomegalovirus and hearing impairment. *Arch Dis Child* 2016; 101(5):433–8.
 10. Eggermont JJ, Ponton CW. Auditory-evoked potentials studies on cortical maturation in normal hearing and implanted children: correlations with changes in structure and speech perception. *Acta Otolaryngol* 2003; 123(2):249–52.
 11. Talero-Gutiérrez C, Carvajalino-Monje I, Samper BS, et al. Delayed auditory pathway maturation in the differential diagnosis of hypoacusis in young children. *Int J Pediatr Otorhinolaryngol* 2008; 72(4):519–27.

Неожиданное улучшение слуха после лечения валганцикловиром у ребёнка с врождённой цитомегаловирусной инфекцией

Силвия Палма¹, Лаура Мазони², Мария Федерика Роверси³, Сесилия Боти⁴, Даниеле Монзани², Алберто Берарди³, Елисабета Дженовезе²

¹ Аудиология, Отделение первичной медицинской помощи, Модена, Италия

² Аудиология, Кафедра диагностики, клинической и общественной медицины, Университет Модены и Реджо Эмилия, Модена, Италия

³ Отделение интенсивной терапии новорожденных, Кафедра медицинских и хирургических наук для матерей, детей и взрослых, Университет Модены и Реджо Эмилия, Модена, Италия

⁴ Докторантская программа клинической и экспериментальной медицины, Университет Модены и Реджо Эмилия, Модена, Италия

Адрес для корреспонденции: Сесилия Боти, Докторантская программа клинической и экспериментальной медицины, Университет Модены и Реджо Эмилия, Виа Дел Поцо, 41125 Модена, Италия; E-mail: botceci@gmail.com; Тел.: +39 059 4222402

Дата получения: 24 мая 2020 ♦ **Дата приемки:** 2 июля 2020 ♦ **Дата публикации:** 30 апреля 2021

Образец цитирования: Palma S, Mazzoni L, Roversi MF, Botti C, Monzani D, Berardi A, Genovese E. Unexpected hearing improvement after treatment with valganciclovir in a child with congenital cytomegalovirus infection. *Folia Med (Plovdiv)* 2021;63(2):297-301. doi: 10.3897/folmed.63.e54665.

Резюме

Недоношенный ребёнок мужского пола 32 недель с врождённой симптоматической цитомегаловирусной инфекцией лечился валганцикловиром. У него также была врождённая тяжёлая двусторонняя потеря слуха, и неожиданно была достигнута нормализация порога слуха в возрасте одного года. Обсуждается улучшение слуха в связи с поздним развитием слухового аппарата и назначением противовирусной терапии. Этот случай также подчёркивает важность ранней диагностики врождённой цитомегаловирусной инфекции, связанной со строгим наблюдением.

Ключевые слова

ЦМВ, врождённый, цитомегаловирус, слух, потеря слуха, валганцикловир