



# Surgical Treatment of Urethral Stricture Disease – the Earlier, the Better

Valeri Mariyanovski, Emil Dorosiev, Boris Mladenov

NI Pirogov UMHATEM, Sofia, Bulgaria

**Corresponding author:** Boris Mladenov, Clinic of Urology, NI Pirogov UMHATEM, 21 Tottleben Blvd., Sofia 1000, Bulgaria; E-mail: boris\_mladenov@abv.bg; Tel.: +359 884 551 093

**Received:** 30 Sep 2020 ♦ **Accepted:** 13 Jan 2021 ♦ **Published:** 31 Aug 2021

**Citation:** Mariyanovski V, Dorosiev E, Mladenov B. Surgical treatment of urethral stricture disease – the earlier, the better. *Folia Med (Plovdiv)* 2021;63(4):481-7. doi: 10.3897/folmed.63.e57517.

## Abstract

**Introduction:** Surgical treatment of urethral strictures is a constantly evolving process. There are various treatment options like internal urethrotomy (IUT) and open surgery. A variety of techniques for urethral reconstruction are available (grafts, flaps, and excision-reanastomosis). Functional results of urethral reconstructive surgery are very satisfying and with low rate of complications.

**Aim:** We assessed the early open surgical reconstruction in comparison with the continuation with the endourological treatment – IUTs.

**Materials and methods:** The study included 129 patients with urethral strictures referred to our center. At that time point, they had received two unsuccessful IUTs and were divided into two groups – consecutive IUT and surgical repair, which included excision and reanastomosis or augmented urethroplasty. These patients were evaluated at 12 months using urethrography and uroflowmetry. Sexual function was evaluated using the international index of erectile function questionnaire 5-IIEF. Chi-squared test for statistical analysis was used.

**Results:** Successful outcomes (urethrography presented equal caliber and Qmax was >15 ml/sec 12 months after the procedure) were achieved in 59 (88%) of the patients using reconstructive surgery versus 26 (41.9%) of the patients with consecutive IUT ( $p<0.001$ ). Mild sexual dysfunction was reported by 12 (17.9%) patients from the group with open surgery and 7 (11.3%) from the group with continuous IUT ( $p=0.289$ ).

**Conclusions:** Early open surgery seems a reasonable solution to the problem of urethral strictures as there are only a few complications from this surgery and the functional results are satisfactory. The success rate using open surgery was found to be significantly greater than that in the consecutive IUT group, whereas no differences in the complication rates regarding sexual function were observed.

## Keywords

IUT, long-term results, urethral stricture, urethroplasty

## INTRODUCTION

Urethral stricture is a scarring process involving the anterior urethra, narrowing the urethral lumen. Posterior urethral stricture is an obliterative process in the posterior urethra that results in fibrosis and is generally the effect of distraction in that area caused by either trauma or radical

prostatectomy. The surgical treatment of urethral strictures is a constantly evolving process.<sup>1</sup> Some authors claim that open surgery is the best treatment option.<sup>2</sup> Buccal mucosa graft is a simple technique with good surgical outcomes.<sup>3</sup> Different techniques for urethral reconstruction are available – grafts, flaps and excision-reanastomosis.<sup>4</sup> The urethral reconstructive surgery is becoming more and more aggressive with less complications.<sup>5</sup>

The currently available types of stricture corrections are as follows:

1. Urethral dilatation: The goal is to stretch the scar without producing more scarring. It has short and midterm efficacy rates equal to IUT<sup>4</sup>;

2. Internal urethrotomy (IUT): It involves incision through the scar to healthy tissue to allow the fibrotic tissue to expand over a urethral catheter and the lumen to heal enlarged. The goal is for the resultant larger luminal caliber to be maintained after healing;

3. Open surgical reconstruction: Urethral channel can be reconstructed by one- or two-stage procedures.

There is no one surgical technique appropriate for any urethral stricture but it depends on the characteristics of the stricture: location, length, severity, and previous urethral interventions. Many authors advocate early surgical repair after failed IUT, pointing out the better long-term success rates.<sup>5</sup> Some concerns about erectile dysfunction after open surgery are raised.<sup>6</sup>

## AIM

To assess the value of early open surgical reconstruction in comparison with the continuation with the endourological treatment (IUT), to compare the success and complication rates of both treatment approaches, which are both largely applied nowadays.

## MATERIALS AND METHODS

The study recruited 129 patients, all of them either our patients or patients referred to our center by other regional hospitals. We compared two groups of patients: group 1 including 67 patients with surgical repair of the urethral stricture after a second unsuccessful IUT, and group 2 with 62 patients with 3 or 4 previous IUT.

The median follow-up lasted 6 years ending January 2018.

Median age was 59.3 years (range 24-78). We excluded patients with total obliteration, multiple consecutive strictures, urethrocutaneous fistula, and history of urethroplasty.

The IUT is performed using the technique of cold knife. The narrowed urethra is incised. The stricture is cut at 12 o'clock position. This is done without cauterization and coagulation in order to avoid the thermal damage of the tissue.

Ethics Committee Approval from the institution was obtained. All patients signed approved informed consent prior to treatment.

Etiology of the strictures in the group of reconstructive surgery was as follows:

1. Catheter placement – 9 cases: most of the patients were cared previously in the ICU department.

2. Perineal trauma – 8 cases: the cases with severe pelvic fractures and hematoma and urinoma, which required immediate surgical exploration were excluded. We included also 2 cases with penile trauma after sexual intercourse associated with partial urethral lesion.

3. Transurethral surgery – 15 cases. We had patients after TURP, HOLEP, TUIP and TURBT.

4. Hypospadias repair – 9 cases.

5. Post infectious strictures – 12 cases: a consequence of sexually transmitted diseases.

6. Lichen sclerosus – 6 cases. The skin is atrophic, white colored, and dry. Lichen sclerosus was histologically proven.

7. Unknown etiology – 8 cases.

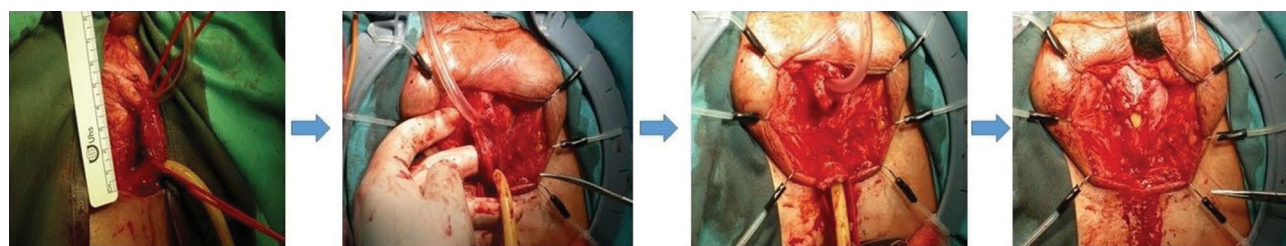
Stricture length for the surgery group was: 1-2 cm – 15 cases; 2 to 3 cm – 20 cases; 3 to 4 cm – 19 cases; 4 to 5 cm or more – 13 cases.

We performed the following surgical corrections:

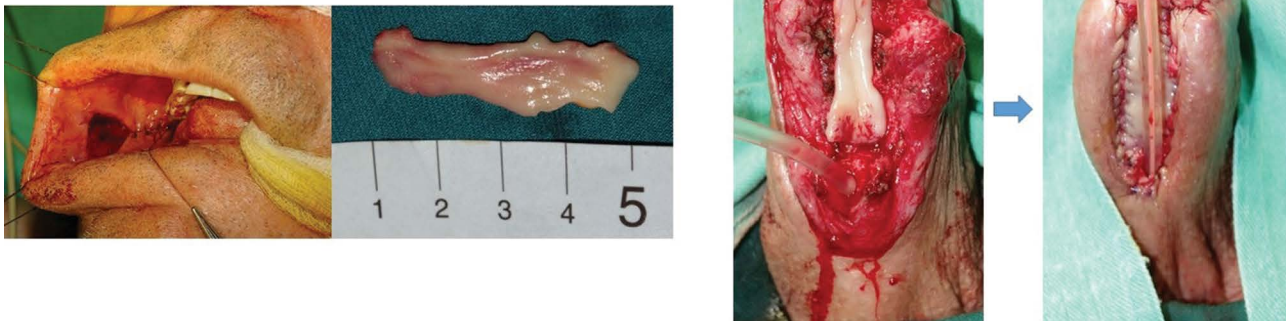
Excision and reanastomosis – 14 cases. We transect the urethra at the previously determined site of the stricture, remove the scarred tissue with enough length of adjacent whitish or grey appearing urethra and the two normal and viable edges are sutured together (**Fig. 1**). We regard the augmented reanastomosis technique as a subtype of the previous one – if the length of the excised, scarred urethra is too big, sometimes direct reanastomosis is impossible or possible under not optimal conditions – tension and danger of fistulisation. In such circumstances, we approach and stitch just the one end of the approximated ends and put a patch of buccal mucosa as a “roof” in the place.

Augmented urethroplasty with buccal mucosa graft (dorsal or ventral onlay – one- or two-stage procedures) – 46 cases. The procedure of harvesting the graft runs as follows: nasal or oral intubation. We take the graft from single cheek and suture the wound.

In penile urethroplasty, we used dorsal onlay with complete excision of the scarred urethra (**Fig. 2**). In one case, we tried a tube graft with remodeling concomitantly with ventral and dorsal onlay after Asopa's technique. In 39 of the patients, the surgeries were completed as a one-stage procedure, but we performed two-stage procedures



**Figure 1.** Excision and reanastomosis of urethra.



**Figure 2.** Penile urethroplasty with dorsal onlay (buccal mucosa graft).

in 7 cases. During the first stage the urethra is opened or completely removed and replaced by a wide strip of oral mucosa. The strip is sutured to the corpora and at 12 months, the edges are tubularised and covered by a second layer of penile skin. The diseased mucosa is excised leaving a midline strip of native urethral mucosa on the dorsal side. The buccal mucosal graft (BMG) is fixed on either side of this strip over a silicone catheter. The glans wings are opposed in midline taking anchoring bites on the mucosal graft ventrally.

Substitution urethroplasty – penile skin flap in 7 cases (in 5 cases prepuce and in 2 cases – the penile shaft skin).

Patients were given oral antibiotics – quinolones in the absence of allergy until the catheter is removed, usually 3 weeks after grafting.

The duration of the catheterization in the IUT group was between 3 and 11 days.

Statistical analysis was performed using the SPSS 21.0 – chi-squared test for statistical inference.

We performed objective evaluation of the results with urethrography and uroflowmetry at 12 months. Clinical outcome was considered successful if the urethrography 12 months after surgery shows equal caliber throughout the whole continuity, Q max postoperatively is above 15 ml/sec.

Sexual function was evaluated via IIEF-5 patient questionnaire.<sup>8</sup>

## RESULTS

The results from the comparison of the success rate of reconstructive surgery group (67 patients) and consecutive IUT group (62 patients) are presented in **Table 1**.

**Table 1.** Differences in the success rates in both groups according to the results at 12 months

	Consecutive IUT	Reconstructive surgery
12 months – equal urethral caliber ( <b>Fig. 3</b> )	26	59
12 months – Qmax > 15 ml/sec	30	59
Success rate (number of patients, %)	26 out of 62 patients (41.9%)	59 out of 67 patients (88%)

Eight (11.9%) patients of the reconstruction surgery patients had treatment failure – with recurrent stricture on the urethrography and Qmax on the uroflowmetry <15 ml/sec. The failures were in the flap-repaired patients. These eight patients were managed as follows: five by repeated IUT and three with definitive perineostomy.

There was a statistically significant difference in the success rate of both approaches – reconstructive surgery and consecutive IUT ( $p<0.001$ ) (**Fig. 4**).

Mild sexual dysfunction was found in 12 (17.9%) patients from the group with open surgery and 7 (11.3%) from the group with continuous IUT – cold glans, hyposensitivity of the penis, ejaculation without a stream but in form of dribbling of the drops.

No statistically significant difference was found between both groups in the sexual dysfunction as a complication of the method used ( $p=0.289$ ) (**Fig. 5**).

## DISCUSSION

Initial studies showed very different outcomes of IUT with success rates ranging from 50% to 100%.<sup>9,10</sup> However, these studies reported only short-term results. Recent studies with longer follow-ups have shown a poor success rate, ranging from 6% to 60%.<sup>11</sup> There are publications for the use of mitomycin, hyaluronic acid, triamcinolone or carboxymethylcellulose as injections in the area of the IUT for improving the results and make them lasting.<sup>12-14</sup>

IUT has its value for shorter strictures and initial treatment.<sup>15,16</sup> If the good result after IUT is not long lasting and the stricture recurs after less than 6-9 months, it is usually pointless to continue with it, because of the better long-term success rates of urethroplasty<sup>17</sup>, which is fully consistent

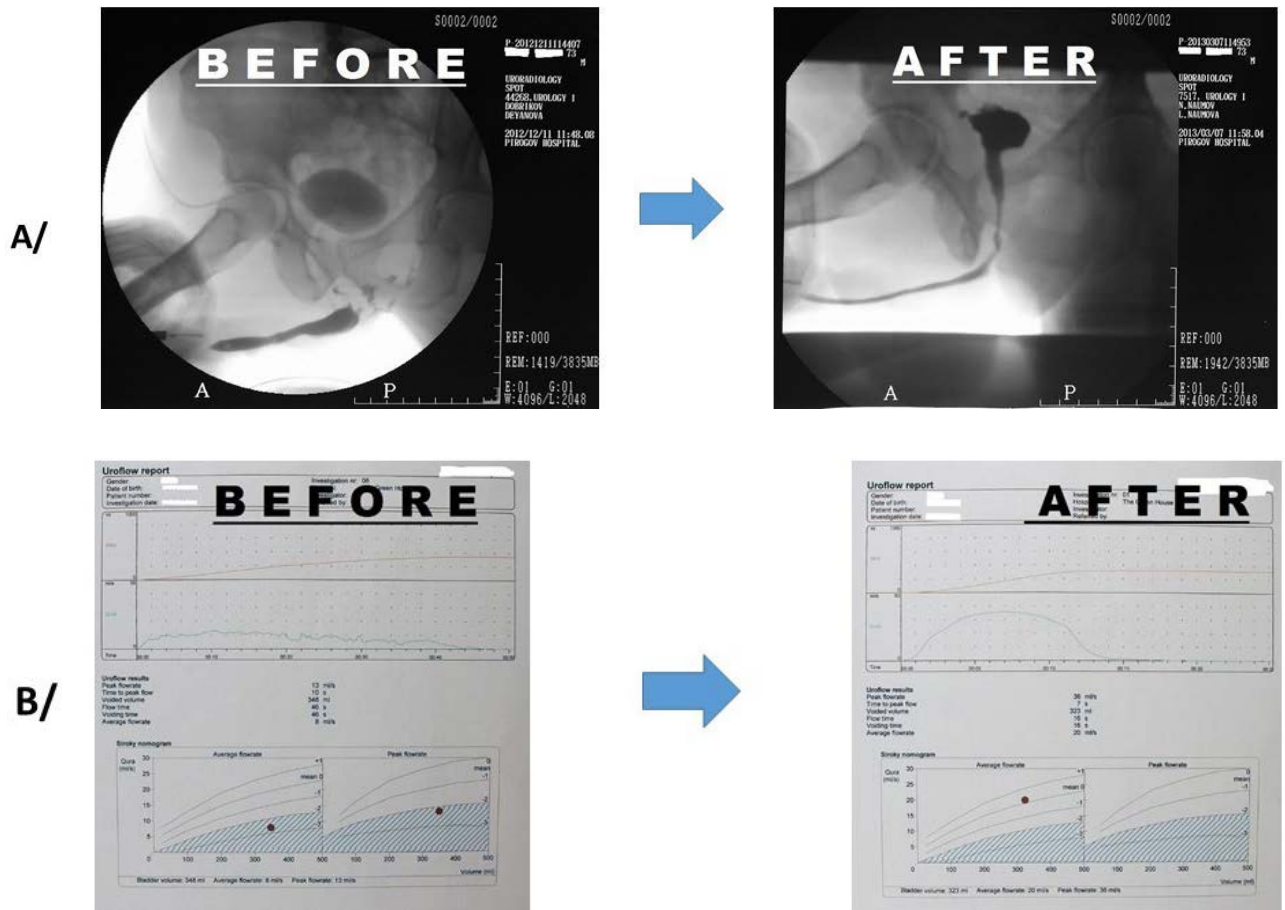


Figure 3. Urography of a patient before and after surgery.

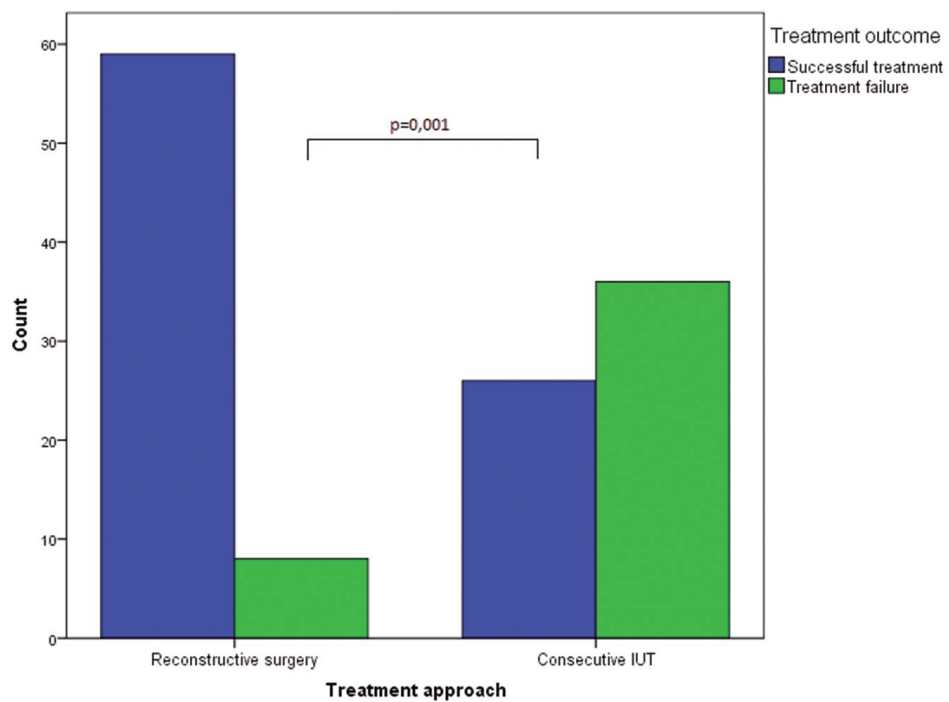
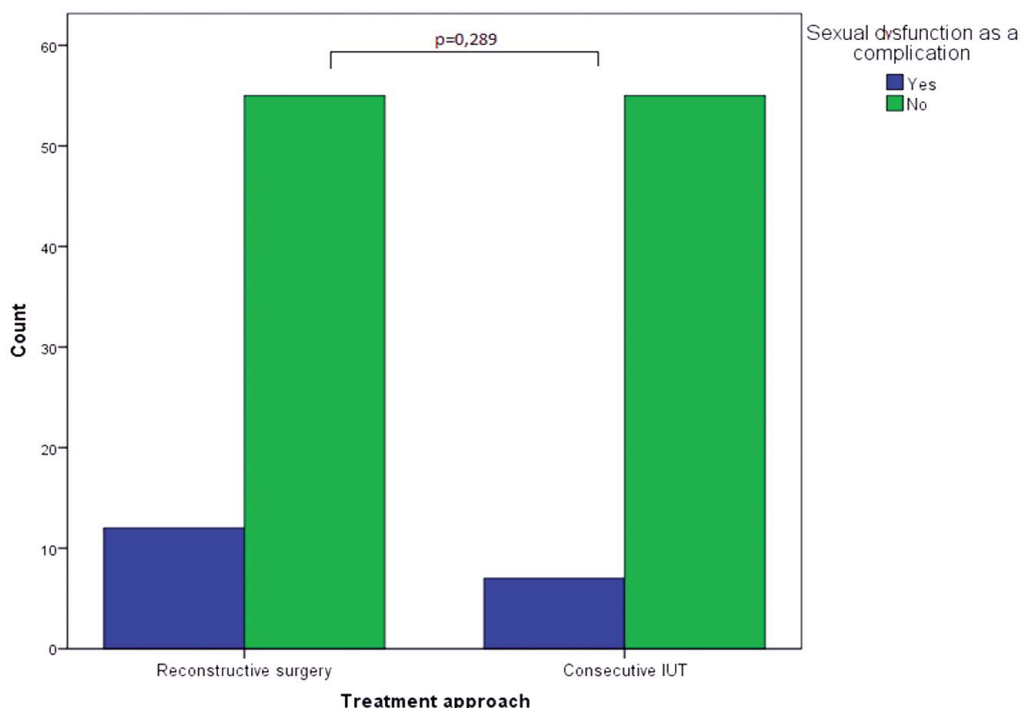


Figure 4. Differences in the success rate of reconstructive surgery and consecutive IUT.



**Figure 5.** Sexual dysfunction as a complication of reconstructive surgery and consecutive IUT.

with the outcomes of the present study. This conclusion is not quite confirmed by the study of Wong et al.<sup>18</sup> who found no sufficient data to determine which intervention was best-suited for urethral stricture disease in terms of balancing efficacy, adverse events and costs. Referring to the cost effectiveness and the clinical benefit, Greenwell et al.<sup>19</sup> clearly advised to proceed after the failure of the 1 IUT to open urethroplasty.

Although the treatment of urethral stricture disease dates to the foundations of our specialty, the considerable progress made over the last 50 years allows many of the most complex strictures to be reliably reconstructed in one stage. Our endeavour has always been to reconstruct the urethra in one stage if the conditions are available – the quality of life of patient is much better with one-stage than with two-stage procedures. We perform two-stage procedures if they are inevitable because of poor vascularization of the tissues and lack of reconstructive material. This option is used by many surgeons.<sup>20,21</sup> Complex and recurrent strictures can be treated without mobilizing the urethra but just via ventral sagittal urethrotomy and dorsal free graft urethroplasty using oral mucosa.<sup>22,23</sup> We found the technique of Asopa especially useful if the scar is dense. Another option for urethral sparing is the concomitant use of preputial and buccal grafts.<sup>24</sup>

Anastomotic repair includes complete excision of the area of fibrosis, with a primary reanastomosis of the normal ends of the anterior urethra. We achieve best results when the following technical points are observed: the area of fibrosis and the surrounding compromised tissue are totally excised; the urethral anastomosis is widely spatu-

lated, creating a large ovoid anastomosis; and the anastomosis is tension free. Defects up to 5 cm can be successfully excised and primarily reconstructed.<sup>25</sup> Based on our results, it is advisable to avoid this technique in strictures longer than 3 cm despite some descriptions of replacement of defects for up to 5 cm. The exact length of the compromised part of the urethra is established through urethrography and urethrocystoscopy as described by Kuo et al.<sup>24</sup>

Most of the authors prefer buccal mucosa and lingual grafts for reconstruction.<sup>25,26</sup> We used only the oral mucosa because it is easy to harvest and there are just a few complications on the donor site. The qualities of the oral mucosa are unsurpassable. We consider the other alternatives almost as just theoretical and much more invasive in comparison with the oral mucosa. We encountered bleeding, continued once on the day after the surgery and more pronounced swelling that interfered with the opening of the mouth, three cases complained with difficult smiling and two with dry mouth. There were occasional reports of numbness and oversensitivity at the place of harvesting. Taking the graft from the lower lip resulted in more difficulties – smiling and sometimes with food intake. The buccal mucosa harvesting has low morbidity according to all authors.<sup>27,28</sup>

Complications following reconstructive surgery for urethral stricture disease are mostly related to infection in the immediate postoperative period. We prevent this by using antibiotics for the duration of the catheter stay and rinsing the mouth with antiseptic solutions regularly for 5 days before the oral mucosa harvesting. This has been observed also by Lacy et al.<sup>29</sup> Other complications accor-

ding to the specialized literature include bleeding, fistulae, thromboembolic, positioning-related, and Foley catheter malfunction.<sup>30,31</sup> Complication rates for anastomotic and substitution urethroplasty were 9.1% and 17%, respectively.<sup>5</sup> Most of our complications were related to the flap substitution – fistula and torsion of the penis. Similar data are also reported.<sup>31</sup> Erectile dysfunction after urethroplasty was raised as a concern<sup>6</sup>, however, our results do not show any statistically significant difference in the patients treated either with open surgery or IUT.

A limitation of the present study is the fact that the groups compared were unequal according to some indicators (for instance length of stricture), which can potentially lead to bias and statistical errors.

## CONCLUSIONS

Early open surgery is a reasonable solution to the problem of urethral strictures because of the fewer complications from this surgery and the reliability of the functional results. The success rate of open surgery was found to be significantly greater than that of consecutive IUTs, while no differences in the complication rates regarding sexual function were observed.

## REFERENCES

- Dubey D. The current role of direct vision internal urethrotomy and self-catheterization for anterior urethral strictures. *Indian J Urol* 2011; 27(3):392–6.
- Albers P, Fichtner J, Brühl P, et al. Long-term results of internal urethrotomy. *J Urol* 1996; 156(5):1611–4.
- Wein AJ, Kavoussi LR, Novick AC, et al., editors. *Campbell-Walsh Urology*. 10th revised edition. Saunders; 2011:979–91.
- Steenkamp JW, Heyns CF, de Kock ML. Internal urethrotomy versus dilation as treatment for male urethral strictures: a prospective, randomized comparison. *J Urol* 1997; 157(1):98–101.
- Barbagli G, Palminteri E, Lazzeri M, et al. Long-term outcome of urethroplasty after failed urethrotomy versus primary repair. *J Urol* 2001; 165(6 Pt 1):1918–9.
- Kałużny A, Krukowski J, Matuszewski M. Erectile dysfunction after urethroplasty. *Cent European J Urol* 2019; 72(4):402–7.
- Navai N, Erickson BA, Zhao LC, et al. Complications following urethral reconstructive surgery: a six-year experience. *Int Braz J Urol* 2008; 34(5):594–600.
- Rhoden EL, Telöken C, Sogari PR, et al. The use of the simplified International Index of Erectile Function (IIEF-5) as a diagnostic tool to study the prevalence of erectile dysfunction. *Int J Impot Res* 2002; 14(4):245–50.
- Islam M, Anwar F, Ahmed S, et al. Optical urethrotomy in strictures following fracture pelvis. *J Ayub Med Coll Abbottabad* 2010; 22:106–8.
- Ali MN. Experience with cold knife optical internal urethrotomy. *J Coll Physicians Surg Pak* 2001; 11:693–5.
- Santucci R, Eisenberg L. Urethrotomy has a much lower success rate than previously reported. *J Urol* 2010; 183:1859–62.
- Ayyildiz A, Nuhoglu B, Gulerkaya B, et al. Effect of intraurethral mitomycin-C on healing and fibrosis in rats with experimentally induced urethral stricture. *Int J Urol* 2004; 11:1122–6.
- Liaqat Ali, Muhammad Shahzad, Nasir Orakzai, et al. Efficacy of mitomycin C in reducing recurrence of anterior urethral stricture after internal optical urethrotomy. *Korean J Urol* 2015; 56:650–5.
- Moradi M, Derakhshandeh K, Karimian B, et al. Safety and efficacy of intraurethral mitomycin C hydrogel for prevention of post-traumatic anterior urethral stricture recurrence after internal urethrotomy. *J Inj Violence Res* 2016; 8(2):75–9.
- Khan S, Khan RA, Ullah A, et al. Role of clean intermittent self-catheterisation (CISC) in the prevention of recurrent urethral strictures after internal optical urethrotomy. *J Ayub Med Coll Abbottabad* 2011; 23:22–5.
- Jackson MJ, Veeratterapillay R, Harding CK, et al. Intermittent self-dilatation for urethral stricture disease in males. *Cochrane Database Syst Rev* 2014; 12:CD010258.
- Husmann DA, Rathbun SR. Long-term follow-up of visual internal urethrotomy for management of short (less than 1 cm) penile urethral strictures following hypospadias repair. *J Urol* 2006; 176(4 Pt 2):1738–41.
- Wong SS, Aboumarzouk OM, Narahari R, et al. Simple urethral dilatation, endoscopic urethrotomy, and urethroplasty for urethral stricture disease in adult men. *Cochrane Database Syst Rev* 2012; 12:CD006934.
- Greenwell TJ, Castle C, Andrich DE, et al. Repeat urethrotomy and dilation for the treatment of urethral stricture are neither clinically effective nor cost-effective. *J Urol* 2004; 172(1):275–7.
- Joshi PM, Barbagli, Batra V, et al. A novel composite two-stage urethroplasty for complex penile strictures: A multicenter experience. *Indian J Urol* 2017; 33(2):155–8.
- Figler BD, Gomella A, Hubbard L. Staged urethroplasty for penile urethral strictures from lichen sclerosus and failed hypospadias repair. *Urology* 2018; 112:222–4.
- Asopa HS, Garg M, Singhal GG, et al. Dorsal free graft urethroplasty for urethral stricture by ventral sagittal urethrotomy approach. *Urology* 2001; 58(5):657–9.
- Palminteri E, Berdondini E, Florio M, et al. Two-sided urethra-sparing reconstruction combining dorsal preputial skin plus ventral buccal mucosa grafts for tight bulbar strictures. *Int J Urol* 2015; 22(9):861–6.
- Kuo TL, Venugopal S, Inman RD, et al. Surgical tips and tricks during urethroplasty for bulbar urethral strictures focusing on accurate localisation of the stricture: results from a tertiary centre. *Eur Urol* 2015; 67(4):764–70.
- Barbagli G, Palminteri E, Guazzoni G, et al. Bulbar urethroplasty using buccal mucosa grafts placed on the ventral, dorsal or lateral surface of the urethra: are results affected by the surgical technique? *J Urol* 2005; 174(3):955–7.
- Soave A, Dahlem R, Pinnschmidt HO, et al. Substitution urethroplasty with closure versus nonclosure of the buccal mucosa graft harvest site: a randomized controlled trial with a detailed analysis of oral pain and morbidity. *Eur Urol* 2018; 73(6):910–22.
- Rosenbaum CM, Schmid M, Ludwig TA, et al. Redo buccal mucosa graft urethroplasty: success rate, oral morbidity and functional outcomes. *BJU Int* 2016; 118(5):797–803.
- Lacy JM, Madden-Fuentes RJ, Dugan A, et al. Short-term complication rates following anterior urethroplasty: an analysis of na-

- tional surgical quality improvement program data. *Urology* 2018; 111:197–202.
29. Al-Qudah HS, Santucci RA. Extended complications of urethroplasty. *Int Braz J Urol* 2005; 31(4):315–23.
30. MacDonald S, Haddad D, Choi A, et al. Anterior urethroplasty has transitioned to an outpatient procedure without serious rise in complications: data from the national surgical quality improvement program. *Urology* 2017; 102:225–8.
31. Blaschko SD, Harris C, Zaid UB, et al. Trends, utilization, and immediate perioperative complications of urethroplasty in the United States: data from the national inpatient sample 2000–2010. *Urology* 2015; 85(5):1190–4.

## Хирургическое лечение стриктуры уретры – чем раньше, тем лучше

Валери Марияновски, Емил Доросиев, Борис Младенов

УМБАЛСМ „Н.И. Пирогов“, София, България

**Адрес для корреспонденции:** Борис Младенов, Клиника урологии, УМБАЛСМ „Н.И. Пирогов“, София, България; E-mail: boris\_mladenov@abv.bg; Тел.: +359 884 551 093

**Дата получения:** 30 сентября 2020 ♦ **Дата приемки:** 13 января 2021 ♦ **Дата публикации:** 31 августа 2021

**Образец цитирования:** Mariyanovski V, Dorosiev E, Mladenov B. Surgical treatment of urethral stricture disease – the earlier, the better. *Folia Med (Plovdiv)* 2021;63(4):481-7. doi: 10.3897/folmed.63.e57517.

### Резюме

**Введение:** Хирургическое лечение стриктур уретры – это постоянно развивающийся процесс. Существуют различные терапевтические варианты, такие как внутренняя уретротомия (IUT) и открытая операция. Доступны различные другие методы реконструкции уретры (трансплантаты, лямбда и эксцизионно-реанастомоз). Функциональные результаты реконструктивной хирургии уретры чрезвычайно удовлетворительны и с низкой частотой осложнений.

**Цель:** Мы оценили раннюю открытую хирургическую реконструкцию по сравнению с продолжением эндоурологической терапии – IUT.

**Материалы и методы:** В исследование включены 129 пациентов со стриктурами уретры, обратившихся в наш центр. К тому времени у них были по две неудачные IUT и они были разделены на две группы – с последующей IUT и с хирургической реконструкцией, которая включала иссечение и реанастомоз или аугментированную уретропластику. Эти пациенты были обследованы через 12 месяцев с помощью уретрографии и урофлоуметрии. Сексуальная функция оценивалась с помощью опросника 5-ИИФ (Международный индекс эректильной функции). Для статистического анализа использовался критерий хи-квадрат.

**Результаты:** Успешный результат (уретрография показала тот же размер и  $Q_{max} > 15$  мл/сек через 12 месяцев после процедуры) был достигнут у 59 (88%) пациентов после реконструктивной хирургии против 26 (41.9%) пациентов с последующей IUT ( $p < 0.001$ ). Лёгкая сексуальная дисфункция была отмечена у 12 (17.9%) пациентов в группе открытого хирургического вмешательства и у 7 (11.3%) пациентов в группе последующей IUT ( $p = 0.289$ ).

**Заключение:** Раннее открытое хирургическое вмешательство представляется разумным решением проблемы стриктур уретры, так как при этом хирургическом вмешательстве имеется всего несколько осложнений, а функциональные результаты удовлетворительны. Показатель успешности открытого хирургического вмешательства оказался значительно выше, чем в группе с последующей IUT, при этом никаких различий в частоте осложнений сексуальной функции не наблюдалось.

### Ключевые слова

IUT, долгосрочные результаты, стриктура уретры, уретропластика