



Risk Factors for Anastomotic Leakage after Low Anterior Resection

Gancho G. Kostov¹, Rossen S. Dimov¹, Daniela D. Almeida²

¹ Department of Special Surgery, Medical University of Plovdiv, Plovdiv, Bulgaria

² Department of Surgery, Faculty of Medicine, Medical University of Plovdiv, Plovdiv, Bulgaria

Corresponding author: Gancho Kostov, Department of Special Surgery, Medical University of Plovdiv, Kaspela University Hospital, Department of Surgery, 64 Sofia St., Plovdiv; E-mail: caspela@abv.bg; Tel.: 0895762972

Received: 12 Mar 2019 ♦ **Accepted:** 08 Aug 2019 ♦ **Published:** 30 June 2020

Citation: Kostov GG, Dimov RS, Almeida DD. Risk factors for anastomotic leakage after low anterior resection. *Folia Med (Plovdiv)* 2020;62(2):290-4. doi: 10.3897/folmed.62.e47727.

Abstract

Introduction: Low anterior resection (LAR) is a standard surgical procedure for distal rectal carcinoma that allows creation of a colorectal anastomosis, with anal sphincter preservation and permanent colostomy avoidance. Anastomotic leakage (AL) is a potential complication of LAR present in 3% to 20% of cases leading to a significant increase in postoperative morbidity. AL represents a communication between the intra luminal and extra luminal compartments caused by a violation of the integrity of the intestinal wall. The risk factors of this procedure have been discussed and still remain a controversial issue. Prevention is the best management. Patients with predisposing factors should be paid special attention.

Aim: Our objective was to identify and analyze the risk factors of anastomotic leakage after low anterior resection of rectal carcinoma.

Patients and methods: This study included all patients who underwent low anterior resection for rectal cancer at the Department of Surgery of University Hospital Kaspela between 2011 and 2016.

Results: Low anterior resections were performed in 141 patients during the study period. Due to a positive air leak test on 16 patients, a protective ileostomy was created and these patients were eliminated from the study. The sex distribution of the remaining 125 patients was 69 men (55.2%) and 56 women (44.8%). The height of the anastomosis from the dentate line was 3.0 cm on an average (range 2.5 to 4 cm).

Conclusion: Anastomotic leakage remains the most feared and serious complication after low anterior resection surgery. The evidence suggests that the main risk factors for anastomotic leakage at low anterior resection are the height of the anastomosis and the high ASA score.

Keywords

anastomotic leakage, low anterior resection, total mesorectal excision.

INTRODUCTION

Low anterior resection (LAR) is a standard surgical procedure for distal rectal carcinoma that allows the creation of anastomosis and anal sphincter preservation.¹ Anastomotic leakage (AL) is a potential complication of LAR that is present in 3% to 20% of cases, leading to a significant

increase in postoperative morbidity.² AL is a communication between intraluminal and extraluminal compartments of the intestinal wall caused by a violation of the integrity of the intestinal wall in the zone of attachment between the colon and the rectum.³ There are still controversies over the risk factors of this complication.⁴ Prevention is believed to be the best approach when close attention is paid to patients with risk factors.⁵

AIM

Our objective was to identify and analyze the risk factors for anastomotic leakage after low anterior resection for treatment of rectal carcinoma

PATIENTS AND METHODS

This study includes all patients who underwent low anterior resection for rectal cancer at the Department of Surgery of University Hospital Kaspela between 2011 and 2016. The patients were monitored from their hospital discharge day to one month after.

In all patients, intestinal tract preparation and bowel cleaning was achieved using four sachets of "Fortrans". Pre-operative corrections of the imbalance in fluids, electrolytes and protein were accomplished, as well as prophylaxis with low molecular heparin and antibiotics of the cephalosporin group. Surgeries were performed by highly qualified team of surgeons. Conventional LAR was performed in 37 patients and laparoscopic LAR in 104 patients. The surgical technique was consistent with the oncological requirements. In all cases we performed a total mesorectal excision (TME) with medial-to-lateral approach, low ligation of the inferior mesenteric vessels and a partial or full mobilization of the left flexure to reach the required colon length avoiding the occurrence of tension on the anastomosis. The distal rectum was divided by articulating Endo GIA™ Articulating Medium/Thick Reload with Tri-Staple™ (Cincinnati, OH, USA) in laparoscopic surgery or with the TA-45 TA™. Single use reloadable staplers and reloads were used in conventional or laparoscopic assisted procedures. All anastomoses were performed in termino-lateral fashion using circular staplers No 29-32 depending on the diameter of the intestine. Anastomoses were routinely tested with an 'air leakage test'. In cases where the test was positive, a protective ileostomy was performed, the defect was sutured and these patients were excluded from the study. During the post-operative period, patients were monitored daily for the following clinical signs suggesting the presence of anastomotic leakage: fever, increased WBC, abdominal pain, prolonged post-operative ileus, tachycardia, and tachypnea, increased secretion from abdominal drainages, elevation of CRP (C-reactive protein) and renal function impairment. Definitive signs of anastomotic leakage were established as the presence of peritoneal irritation and/or extravasation of

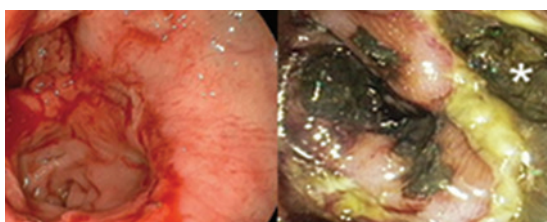


Figure 1. Anastomotic dehiscence.

feces at the anastomotic site. In addition to physical examination and laboratory tests, x-rays, computed tomography and endorectal ultrasonography were performed for visual confirmation and assessment of the leakage (Fig. 1).

RESULTS

During the study period, low anterior resections were performed in 141 patients. Due to a positive air leak test on 16 patients, a protective ileostomy was created and these patients were excluded from the study. Of the remaining 125 patients, gender distribution was as follows: 69 males (55.2%) and 56 females (44.8%). The height of the anastomosis from the dentate line was 3.0 cm on the average, varying from 4 to 2.5 cm. Of these patients, 41 (38.8%) were referred to non-adjuvant chemo-radiation therapy. Seventy-eight (62.4%) patients were smokers. The average

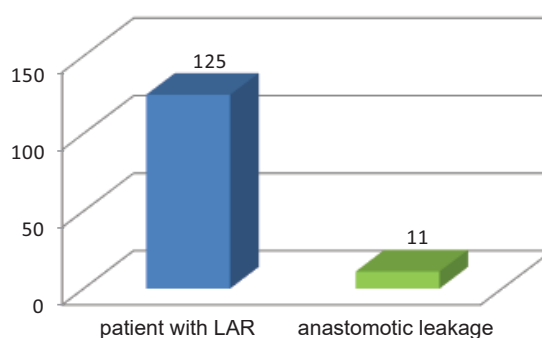


Figure 2. Patients with anastomotic leakage.

BMI of the patients was 24.43. Perioperative blood loss was on average 80 ml. A high ASA score was found in 27 patients (21.6%). Perioperative transfusion of blood and blood products was required in 20 patients (16%). Anastomotic leakage was observed in 11 patients (8.8%) (Fig. 2).

The gender distribution in this group is as follows: 6 males and 5 females.

Anastomotic leakage most commonly occurred in patients with a risk factor combination of high ASA score

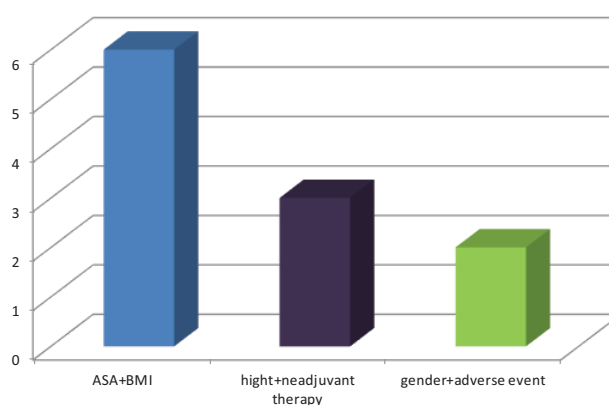


Figure 3. Risk factors for anastomotic leakage.

and a BMI > 27 and it was observed in 6 patients (54.5%) distributed equally between males and females. In addition to the height of anastomosis and smoking, non-adjuvant chemo/radiation therapy was associated with an increased risk of anastomotic leak in 3 patients (27.3%). Two patients (18.2%) had a combination of anastomosis height, male

| Colon Leakage Score (CLS) and Points Per Variable | | Score |
|---|---|-------|
| Age | <60 | 0 |
| | 60-69 | 1 |
| | 70-79 | 2 |
| | >80 | 4 |
| Gender | Female | 0 |
| | Male | 1 |
| ASA | I | 0 |
| | II | 1 |
| | III | 3 |
| | IV | 6 |
| BMI | 19-24 | 0 |
| | 25-30 | 1 |
| | >30/<19 or wt loss (>5kg/6 mo) | 3 |
| Intoxication | No | 0 |
| | Smoking | 1 |
| | Alcohol (>3 U/d) | 1 |
| | Steroids (present use excluding inhalers) | 4 |
| Neoadjuvant therapy | No | 0 |
| | Radiotherapy | 1 |
| | Chemoradiation | 2 |
| Emergency surgery | No | 0 |
| | Bleeding | 2 |
| | Obstruction | 3 |
| | Perforation | 4 |
| Distance of anastomosis to anal verge | >10 | 0 |
| | 5-10 | 3 |
| | <5 | 6 |
| Additional procedures | No | 0 |
| | Yes | 1 |
| Blood loss (cc), Blood transfusion | <500 | 0 |
| | 500-1000 | 1 |
| | 1001-2000 | 3 |
| Duration of operation (h: min) | >2000 | 6 |
| | <2:00 | 0 |
| | 2:00-2:59 | 1 |
| | 3:00-3:59 | 2 |
| | >4:00 | 4 |

Figure 4. Colon leakage score (From Dekker JW, Liefers GJ, de Mol van Otterloo JC, et al. Predicting the Risk of Anastomotic Leakage in Left-sided Colorectal Surgery Using a Colon Leakage Score. *Journal of Surgical Research* 2011; 166(1).

gender and increased operating time > 200 minutes due to intraoperative hemorrhage requiring perioperative transfusion of blood products (**Fig. 3**).

DISCUSSION

Our results show that a high ASA score and the height of anastomosis are the most common risk factors for anastomotic leakage. Comorbidity as a factor for AL has been supported by a number of studies that show a significant increase in the incidence of anastomotic dehiscence in patients presenting with more than two concomitant diseases.⁶

On the other hand, the height of anastomosis is an independent predictor of AL. According to Vignali it is <7 cm, Karanjia – <6 cm, Rullier – <5 cm, and Eriksen – <3 cm from the dentate line. Rose et al.⁷ reported AL complication in 16.8% of cases at a distance of LAR less than 10 cm from the dentate line.

The present study shows that anastomotic leakage is more than twice as common in male gender. This is confirmed by some studies and is due to the narrow male pelvis and poor visualization during dissection.⁸

Patients with intra-operative adverse events leading to prolongation of the surgery, such as excessive blood loss requiring preoperative blood transfusion and fecal contamination of the abdominal cavity showed more than 4 times an increased risk of developing AL.^{9,10}

The question remains whether neo-adjuvant chemo-radiation therapy can increase the risk of dehiscence in low rectal anastomosis. Several studies have been published reporting that it significantly increases the incidence of AL.¹¹ Other authors reported no difference in both patient groups.^{12,13} In our study, non-adjuvant therapy was not observed to be a major risk factor associated with anastomotic complications.

A high BMI was a proven risk factor of anastomotic complications, especially in combination with other risk factors.¹⁴

Smoking as an element causing vascular wall damage and other factors affecting blood vessel disorders such as diabetes mellitus and atherosclerosis have a significant impact on the severity of complications of low rectal anastomoses.^{15,16}

Many systems including 'colon leakage score' have been developed for the assessment of the risk factors for anastomotic leakage and its prevention (**Fig. 4**).

CONCLUSIONS

Anastomotic leakage after low anterior resection remains the most feared and serious complication of this surgery. Based on our own experience with the procedure, we can conclude that the main risk factors for anastomotic leakage are the height of the anastomosis and a high ASA score.

REFERENCES

1. Griffen FD, Knight CD, Whitaker JM, et al. The double stapling technique for low anterior resection. Results, modifications, and observations. *Ann Surg* 1990; 211: 745-51.
2. Eberl T, Jagoditsch M, Klingler A, et al. Risk factors for anastomotic leakage after resection for rectal cancer. *Am J Surg* 2008; 196: 592-598.
3. Rahbari NN, Weitz J, Hohenberger W, et al. Definition and grading of anastomotic leakage following anterior resection of the rectum: a proposal by the International Study Group of Rectal Cancer. *Surgery* 2010; 147: 339-51.
4. Schrock TR, Deveney CW, Dunphy JE. Factor contributing to leakage of colonic anastomoses. *Ann Surg* 1973; 177: 513-8.
5. Cong Z-j, Fu C-g, Wang H-t, et al. Influencing factors of symptomatic anastomotic leakage after anterior resection of the rectum for cancer. *World J Surg* 2009; 33: 1292-7.
6. Makela JT, Kiviniemi H, Laitinen S. Risk factors for anastomotic leakage after left-sided colorectal resection with rectal anastomosis. *Dis Colon Rectum* 2003; 46: 653-60.
7. Rose J, Schneider C, Yildirim C, et al. Complications in laparoscopic colorectal surgery: results of a multicentre trial. *Tech Coloproctol* 2004; 8: S25-S28.
8. Poon RT, Chu KW, Ho JW, et al. Prospective evaluation of selective defunctioning stoma for low anterior resection with total mesorectal excision. *World J Surg* 1999; 23: 463-7.
9. Vignali A, Fazio VW, Lavery IC, et al. Factors associated with the occurrence of leaks in stapled rectal anastomoses: a review of 1,014 patients. *J Am Coll Surg* 1997; 185: 105-13.
10. Matthiessen P, Hallbook O, Andersson M, et al. Risk factors for anastomotic leakage after anterior resection of the rectum. *Colorectal Dis* 2004; 6: 462-9.
11. Holm T, Rutqvist LE, Johansson H, et al. Postoperative mortality in rectal cancer treated with or without preoperative radiotherapy: causes and risk factors. *Br J Surg* 1996; 83: 964-8.
12. Sauer R, Fietkau R, Wittekind C, et al. Adjuvant vs. Neoadjuvant radiochemotherapy for locally advanced rectal cancer: the German trial CAO/ARO/AIO-94. *Colorectal Dis* 2003; 5: 406-5.
13. Enker WE, Merchant N, Cohen AM, et al. Safety and Efficacy of Low Anterior Resection for Rectal Cancer : 681 consecutive cases from a specialty service. *Ann Surg* 1999; 230: 544-52.
14. Nickelsen TN, Jørgensen T, Kronborg O. Lifestyle and 30-day complications to surgery for colorectal cancer. *Acta Oncol* 2005; 44: 218-23.
15. Sørensen LT1, Jørgensen T, Kirkeby LT, et al. Smoking and alcohol abuse are major risk factors for anastomotic leakage in colorectal surgery. *Br J Surg* 1999; 86:927-931.
16. Wadwa RP. Cardiovascular disease risk in youth with diabetes mellitus. *Rev Endocrine Metab Disord* 2006; 7(3): 197-204.

Факторы риска развития несостоятельности анастомоза после низкой передней резекции

Ганчо Г. Костов¹, Росен С. Димов¹, Даниела Д. Алмейда²

¹ Кафедра специализированной хирургии, Медицинский университет – Пловдив, Пловдив, Болгария

² Кафедра хирургии, Факультет медицины, Медицинский университет – Пловдив, Пловдив, Болгария

Автор для корреспонденции: Кафедра специализированной хирургии, Медицинский университет – Пловдив, УМБАЛ „Каспела“, Отделение хирургии, ул. „София“ № 64, Пловдив, Болгария; E-mail: caspela@abv.bg; Tel.: 0895762972

Дата получения: 12 марта 2019 ♦ **Дата приемки:** 8 августа 2019 ♦ **Дата публикации:** 30 июня 2020

Образец цитирования: Kostov GG, Dimov RS, Almeida DD. Risk factors for anastomotic leakage after low anterior resection. Folia Med (Plovdiv) 2020;62(2):290-4. doi: 10.3897/folmed.62.e47727.

Резюме

Введение: Низкая передняя резекция (НПР) является стандартной хирургической процедурой при дистальной карциноме прямой кишки, которая позволяет выполнять колоректальный анастомоз, сохраняя анальный сфинктер и избегая постоянной колостомы. Несостоятельность анастомоза (НА) является потенциальным осложнением НПР, возникающим в 3-20% случаев, что приводит к значительному увеличению послеоперационной заболеваемости. НА является связующим звеном между внутрипросветными и внепросветными компартментами, вызванными нарушением целостности кишечной стенки. Факторы риска являлись предметом обсуждения и всё ещё представляют собой спорный вопрос. Профилактика является самым эффективным способом предупреждения развития осложнения. Пациенты с предрасполагающими факторами должны находиться под пристальным наблюдением.

Цель: Наша цель состояла в том, чтобы идентифицировать и проанализировать факторы риска возникновения несостоятельности анастомоза после низкой передней резекции рака прямой кишки.

Пациенты и методы: В это исследование были включены все пациенты, перенёвшие низкую переднюю резекцию по поводу рака прямой кишки в отделении хирургии при Университетской клинике „Каспела“ в период с 2011 по 2016 год.

Результаты: Низкие передние резекции были выполнены у 141 пациента в течение периода исследования. Ввиду положительной инсuffляционной воздушной пробы (air leak test) 16 пациентам была выполнена защитная илеостомия, и эти пациенты были исключены из исследования. Распределение по полу среди оставшихся 125 пациентов составило 69 мужчин (55,2%) и 56 женщин (44,8%). Высота расположения анастомоза над зубчатой линией составляла в среднем 3,0 см (колеблется от 2,5 до 4 см).

Заключение: Несостоятельность анастомоза остается наиболее опасным и серьёзным осложнением после низкой передней резекции. Данные показывают, что основными факторами риска несостоятельности анастомоза при низкой передней резекции являются высота расположения анастомоза и высокий критерий риска по шкале Американского общества анестезиологов (ASA score).

Ключевые слова

несостоятельность анастомоза, низкая передняя резекция, тотальная мезоректумэктомия
