



# Keloid Formation after Circumcision: A Case Report and Current Literature Review

Yavuz Guler<sup>1</sup>, Akif Erbin<sup>2</sup>, Gokhun Ozmerdiven<sup>3</sup>

<sup>1</sup> Private Safa Hospital, Istanbul, Turkey

<sup>2</sup> Department of Urology, Haseki Training and Research Hospital, Istanbul, Turkey

<sup>3</sup> Medical Faculty, Istanbul Aydin University, Istanbul, Turkey

**Corresponding author:** Akif Erbin, Department of Urology, Haseki Training and Research Hospital, Haseki Sultan, Haseki Eğitim ve Araştırma Hst., 34096 Fatih/Istanbul, Turkey; E-mail: akiferbin@hotmail.com

**Received:** 23 Dec 2019 ♦ **Accepted:** 9 Apr 2020 ♦ **Published:** 30 Sep 2020

**Citation:** Guler Y, Erbin A, Ozmerdiven G. Keloid formation after circumcision: A case report and current literature review. *Folia Med (Plovdiv)* 2020;62(3):601-4. doi: 10.3897/folmed.62.e49619.

## Abstract

Although penile keloid formation can be seen after major penile surgeries, it is rarely reported after circumcision and there is no standard method for the treatment of this complication. We present a patient who was admitted with a penile keloid mass that occurred after circumcision surgery and discuss the treatment we administered in light of the current literature review. A 7-year-old white boy was admitted to our clinic with a swollen stiff mass on the foreskin six months after circumcision. The parents indicated that no complication occurred in the early postoperative period. Physical examination revealed a white-colored stiff mass measuring approximately 2×1.5 cm in size along the penile ventral surface. Intralesional injection of 0.5 ml triamcinolone acetonide was administered for 12 weeks. At 9 months after circumcision, the keloid tissue was resected. Beginning from the first postoperative week, a silicone gel sheet and topical steroid application were administered for 8 weeks. At a 1-year follow-up, the penis had a satisfactory appearance.

## Keywords

circumcision, large keloid, penile keloid

## INTRODUCTION

Male circumcision is one of the most common surgical procedures administered around the world for medical and religious reasons (in Jewish and Muslim communities and in some African, American, and Australian tribes). Recent reviews indicate that male circumcision reduces the incidence of penile cancer, acquired immunodeficiency syndrome (AIDS), and sexually transmitted diseases.<sup>1,2</sup>

Male circumcision has a low complication profile (2-4%) and rarely causes complications, which may include bleeding, infection, hematoma, edema, dehiscence, decreased penile sensitivity, urethral injury, meatal stenosis, and penile glans necrosis. Although penile keloid formation can be seen after hypospadias and penile curvature repair and major penile surgeries such as phalloplasty, it is rarely re-

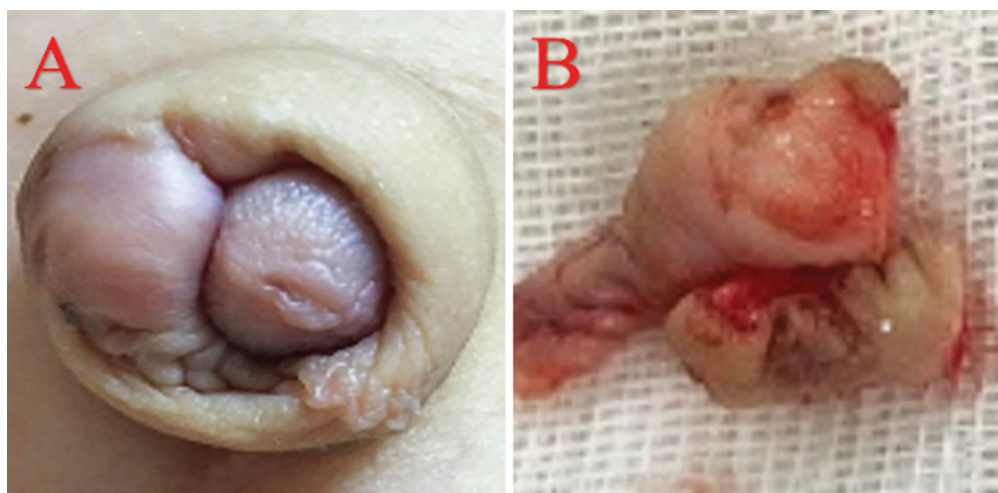
ported after circumcision.<sup>3</sup> Keloids are defined as excessive accumulation of extracellular matrix, particularly collagen, in the dermis and subcutaneous tissue. Keloids may occur at any age, with a peak incidence during and after adolescence. The most common sites of keloid formation include sternal region, deltoid areas, upper back, posterior neck, and earlobes. In patients with keloid predisposition, clinical conditions causing increased tension such as surgical saturation, delayed wound healing, infection, and foreign body reaction increase the risk of keloid formation. Penile keloids may lead to pain, itching, and cosmetic concerns in children and may additionally cause sexual dysfunction and anxiety in adults. Literature reviews indicate a limited number of studies reporting keloid formation after circumcision. Additionally, to our knowledge, there is no standard method for the treatment of this complication. We present a patient who was admitted with a penile keloid mass that

occurred after circumcision surgery and resulted in cosmetic deformity and discuss the treatment we administered to the patient in light of a literature review.

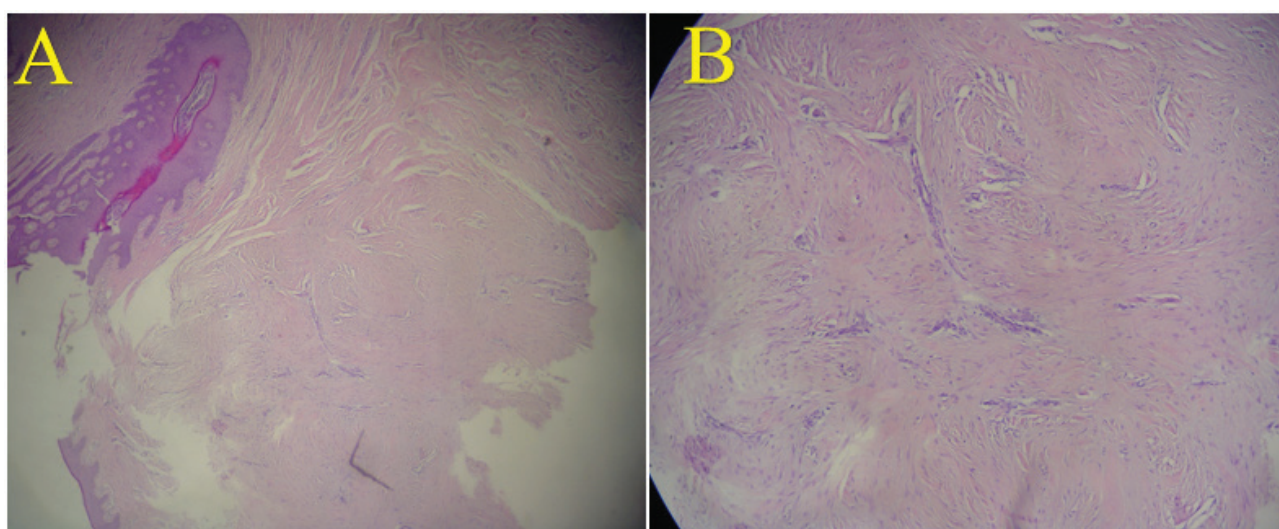
## CASE REPORT

A 7-year-old white boy was admitted to our clinic with a swollen stiff mass on the foreskin six months after the circumcision procedure. The parents reported that no complication occurred in the early postoperative period and then a penile lesion gradually became prominent at the circumcision site. The patient had no personal or family history of abnormal wound healing. Physical examination revealed a white-colored stiff mass measuring approximately 2×1.5 cm in size along the penile ventral surface at the coronal sulcus level.

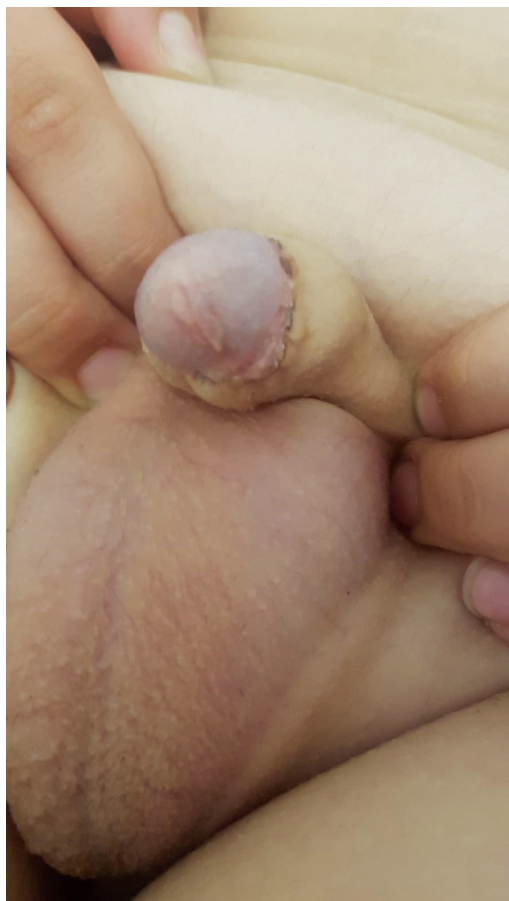Additionally, the penis was buried in the peripenile fat pad (Fig. 1A). Based on these findings, the patient was diagnosed as having a penile keloid mass. Intralesional injection of 0.5 ml of triamcinolone acetonide (1 ml/40 mg of triamcinolone acetonide with hydrochloride 0.6 ml 2% lidocaine injection 0.1 ml per injection site once a week) was administered for 12 weeks. Following this therapy, further enlargement of the keloid mass was prevented and the mass became softer and compressible. At the ninth postoperative month after circumcision, the keloid tissue was resected (Fig. 1B) and the coronal skin was closed primarily. Care was taken to avoid tension at the suturing site. Histopathological examination confirmed the diagnosis of keloid mass (Fig. 2). Beginning from the first postoperative week, a silicone gel sheet and topical steroid application were administered for 8 weeks. At a 1-year follow-up, the penis had a satisfactory appearance (Fig. 3).



**Figure 1.** A: Typical penile keloid appearance, especially on the penile ventral surface; B: Resected keloid tissue.



**Figure 2.** Analysis of tissue sections indicated morphological changes suggestive of a keloid mass characterized by mildly elevated eosinophilia, hypocellularity, and swelling that extended from the lower layer of normal epidermis at the penile ventral surface to the supportive collagen tissue (A: Hematoxylin and Eosin; H&E, 10×10, B: H&E 4×10)



**Figure 3.** Appearance at a 1-year follow-up after keloid excision.

## DISCUSSION

Keloid formation in the genital region is extremely rare despite the high frequency of surgical operations performed in this region. To our knowledge, the literature about keloid formation after circumcision is limited to a few case reports.<sup>3,4</sup> Accordingly, the exact pathogenesis of keloid formation characterized by abnormal scar formation in the penis after circumcision remains unknown. As a matter of fact, the circumcision procedures performed by traditional circumcisers under unhygienic conditions in some regions around the world remain a serious risk factor for keloid formation following circumcision.<sup>4</sup> Moreover, some plant leaves and plant products applied to circumcision wounds are considered to be associated with infection and collagen deposition.

To date, various methods including intralesional therapies (corticosteroids, 5-fluorouracil, interferon, bleomycin injection, intralesional brachytherapy, intralesional botox), surgical excision, topical corticosteroid injection, radiation therapy (external beam radiotherapy; EBRT and brachytherapy), silicone gel therapies, compression therapy, and laser therapies have been trialled for the treatment of keloids.<sup>5-8</sup> Of these, intralesional corticosteroid injection,

topical corticosteroid injection, surgical excision, and silicone gel therapies were reported to be successful for the treatment of penile keloids.

Silicone gel sheeting is a simple noninvasive technique. Although its exact mechanism remains unknown, the silicone layer formed through this technique is considered to exert its effect by increasing the temperature and hydrating the tissue.<sup>9</sup> Nevertheless, this technique is difficult to implement in children as it requires several weeks of administration.

On the other hand, although there is no standard method for the treatment of penile keloids occurring after surgical procedures, combined therapies of steroid injection and surgical excision are the most commonly preferred approaches. A previous study indicated that the administration of surgical excision alone resulted in local recurrence in 100% of the patients, and also led to further enlargement of the lesion and that this rate was reduced to almost 50% in combination with steroids.<sup>10</sup> Intralesional steroid injection reduces intralesional inflammation, thereby leading to increased vasoconstriction and inhibition of fibroblast proliferation, ultimately resulting in lesion shrinkage and resolution of symptoms such as pruritus. On the other hand, although there is no standard dosing schedule and protocol for steroid injection for the treatment of penile keloids, administering steroid injection both before and after surgery is considered a more effective approach. Additionally, initial administration of surgical excision prior to steroid injection is recommended for excessively large keloid masses. In the case presented, a combined therapy (preoperative intralesional steroid injection + surgical excision + postoperative topical steroid + silicone gel sheeting) was administered and no recurrence was observed during short-term follow-up.

## CONCLUSION

In conclusion, keloid formation after circumcision is a rare, troublesome complication with a high risk of recurrence and no standard treatment. In clinical practice, the combined therapy of intralesional steroid injection and surgical excision is the mainstay treatment. Additionally, initial administration of surgical excision prior to steroid injection is recommended in cases with excessively large keloid masses. Postoperative topical steroid injection and the administration of silicone gel sheeting, in suitable children, may be beneficial for the prevention of recurrence. Further experimental and clinical studies are needed to investigate the establishment of a standard multimodal approach.

**Key-messages:** Initial administration of surgical excision prior to steroid injection is recommended in cases of excessively large keloid. Postoperative topical steroid injection and the administration of silicone gel sheeting may be beneficial for the prevention of recurrence, in suitable children.

## REFERENCES

1. Yuan T, Fitzpatrick T, Ko NY, et al. Circumcision to prevent HIV and other sexually transmitted infections in men who have sex with men: a systematic review and meta-analysis of global data. *Lancet Glob Health* 2019;7:e436–e47.
2. Douglawi A, Masterson TA. Penile cancer epidemiology and risk factors: a contemporary review. *Curr Opin Urol* 2019;29:145–9.
3. Alyami F, Fernandez N, Koyle MA, et al. Keloid formation after pediatric male genital surgeries: an uncommon and difficult problem to manage. *J Pediatr Urol* 2019;15:e1–48.e8.
4. Cappuyns LSM, Kumiponjera D, Mungazi SG. A rare presentation of penile keloids after traditional circumcision: Case report. *Int J Surg Case Rep* 2019;60:261–4.
5. Siotos C, Uzozike AC, Hong H, et al. Keloid excision and adjuvant treatments: a network meta-analysis. *Ann Plast Surg* 2019;83:154–62.
6. Bi M, Sun P, Li D, et al. Intralesional injection of botulinum toxin type a compared with intralesional injection of corticosteroid for the treatment of hypertrophic scar and keloid: a systematic review and meta-analysis. *Med Sci Monit* 2019; 25:2950–8.
7. Mankowski P, Kanevsky J, Tomlinson J, et al. Optimizing radiotherapy for keloids: A meta-analysis systematic review comparing recurrence rates between different radiation modalities. *Ann Plast Surg* 2017; 78:403–11.
8. Shin J, Cho JT, Park SI, et al. Combination therapy using non-ablative fractional laser and intralesional triamcinolone injection for hypertrophic scars and keloids treatment. *Int Wound J* 2019;16(6):1450–6.
9. Mustoe TA. Evolution of silicone therapy and mechanism of action in scar management. *Aesth Plast Surg* 2008;32:82–92.
10. Xie LH, Li SK, Li Q. Combined treatment of penile keloids: a troublesome complication after circumcision, *Asian J Androl* 2013;15:575–6.

## Келоидная формация после обрезания: клинический случай и обзор современной литературы

Явуз Гюлер<sup>1</sup>, Акиф Ербин<sup>2</sup>, Гокхун Озмердивен<sup>3</sup>

<sup>1</sup> Частная больница Сафа, Стамбул, Турция

<sup>2</sup> Отделение урологии, Учебно-исследовательская больница Хасеки, Стамбул, Турция

<sup>3</sup> Медицинский факультет, Стамбульский университет Айдын, Стамбул, Турция

**Адрес для корреспонденции:** Акиф Ербин, Отделение урологии, Учебно-исследовательская больница Хасеки, Султан Хасеки, 34096 Фатих Стамбул, Турция; E-mail: akiferbin@hotmail.com

**Дата получения:** 23 декабря 2019 ♦ **Дата приемки:** 9 апреля 2020 ♦ **Дата публикации:** 30 сентября 2020

**Образец цитирования:** Guler Y, Erbin A, Ozmerdiven G. Keloid formation after circumcision: A case report and current literature review. *Folia Med (Plovdiv)* 2020;62(3):601-4. doi: 10.3897/folmed.62.e49619.

### Резюме

Хотя келоидное образование полового члена можно наблюдать после крупной операции на половом члене, об этом редко сообщают после обрезания, и не существует стандартного метода лечения этого осложнения. Мы представляем пациента с коллоидной массой полового члена, появившейся после операции обрезания, и обсуждаем лечение, которое мы предприняли, в свете обзора современной литературы. Семилетний мальчик поступил в нашу клинику с опухшей твёрдой массой крайней плоти через шесть месяцев после обрезания. Родители сообщили, что в раннем послеоперационном периоде осложнений не было. Физикальное исследование показало твёрдую массу белого цвета размером примерно 2 × 1,5 см на вентральной поверхности полового члена. Интралезиональная инъекция триамцинолона ацетонида была назначена на 12 недель. На девятом месяце после обрезания келоидная ткань была удалена. С первой послеоперационной недели назначали силиконовый лист и местный стероид в течение 8 недель. При последующем осмотре после первого года половой член имел удовлетворительный внешний вид.

### Ключевые слова

обрезание, крупный келоид, келоид полового члена