

Complications Due to Ultrasound Transthoracic Cutting Biopsy of Peripheral Pulmonary Lesions and Lesions in the Chest Wall and Mediastinum

Dimcho Argirov^{1,4}, Boyko Yavorov^{2,4}, Vladimir Aleksiev^{2,4}, Anastas Chapkunov^{1,4}, Filip Shterev^{3,4}, Stanislav Kartev^{3,4}, Petar Uchikov^{1,5}, Zaprin Vazhev^{2,4}

¹ Department of Special Surgery, Medical University of Plovdiv, Plovdiv, Bulgaria

² Department of Cardiovascular Surgery, Medical University of Plovdiv, Plovdiv, Bulgaria

³ First Department of Internal Diseases, Section of Pneumology and Phthisiatrics, Medical University of Plovdiv, Plovdiv, Bulgaria

⁴ Thoracic Surgery CLINIC, Kaspela University Hospital, Plovdiv, Bulgaria

⁵ Second Surgical Clinic, St George University Hospital, Plovdiv, Bulgaria

Corresponding author: Dimcho Argirov, Department of Special Surgery, Medical University of Plovdiv, Plovdiv, Bulgaria; Email: d_r_argirov@abv.bg

Received: 11 Oct 2023 ♦ **Accepted:** 9 Feb 2024 ♦ **Published:** 30 Apr 2024

Citation: Argirov D, Yavorov B, Aleksiev V, Chapkunov A, Shterev F, Kartev S, Uchikov P, Vazhev Z. Complications due to ultrasound transthoracic cutting biopsy of peripheral pulmonary lesions and lesions in the chest wall and mediastinum. *Folia Med (Plovdiv)* 2024;66(2):179-187. doi: 10.3897/foimed.66.e114030.

Abstract

Introduction: Evaluation of patients with peripheral lung lesions and lesions of the chest wall and mediastinum is challenging. The nature of the lesion identified by imaging studies can be determined by histological evaluation of biopsies. An important place in this direction is the ever-increasing popularity among thoracic surgeons of the transthoracic biopsy with a cutting needle under ultrasound control (US-TTCNB).

Aim: This article aims to outline potential complications that may arise from transthoracic incisional biopsy performed under ultrasound guidance, along with a percentage reduction algorithm and treatment approaches.

Materials and methods: The present study is based on 264 patients with CT-detected peripheral lesions of the lung, chest wall, and the mediastinum performed in the Department of Thoracic Surgery of Kaspela University Hospital in Plovdiv over a period of 2 years (January 2020 – December 2021).

Results: Complications were found in 11 (4.17%) patients.

Conclusion: Our established biopsy technique achieves a sufficient amount of biopsy material with a low rate of post-biopsy complications.

Keywords

CT, pulmonary lesions, ultrasound-guided transthoracic incisional biopsy, ultrasound

INTRODUCTION

Worldwide, lung carcinoma is the most common cause of death from malignancy in both men and women. In most cases, early diagnosis is difficult and requires the use of a

number of diagnostic methods with varying degrees of invasiveness. Currently, both smaller and larger tumor masses can be detected due to improvements in scanning resolution^[1,2], and lung cancer screening with CT is gaining in popularity. Histological verification is essential for correct

diagnostic determination of the pathology of these masses, as the distinction between malignant and benign is essential for treatment planning.^[3,4]

Thoracic surgeons have become increasingly interested in US-guided transthoracic biopsy in recent years because of its advantages, which include being available at the patient's bedside, requiring no radiation, being low cost, providing precise real-time control, and allowing targeted percutaneously guided biopsy.^[5-13] The technique is relatively safe with a very low risk of complications (below 0.5%)^[6] and is preferable, especially if the alternative is diagnostic surgery. In the hands of a thoracic surgeon, the ultrasound-guided transthoracic cutting needle biopsy of peripherally located tumor masses of the chest wall, lung, and mediastinum is a sufficiently reliable invasive procedure allowing the collection of sufficient material for histologic verification.^[6,14]

AIM

This article aims to outline potential complications that may arise from transthoracic incisional biopsy performed under ultrasound guidance, along with a percentage reduction algorithm and treatment approaches.

MATERIALS AND METHODS

Between January 2020 and December 2021, 281 patients were referred to us for verification of one or more peripheral lung lesions. Such lesions are defined as lesions that not only

border the pleura but also have an accessible ultrasound window. 264 of these patients underwent US-TTCNB according to the criteria for inclusion in the study. In the remaining 17 patients, it was not performed either because of small, insufficient contact of the formation with the chest wall and related to this insufficient window for transthoracic biopsy or because of general contraindications.

The inclusion criteria were: a) peripheral lung masses that rest on the pleural surface; b) pleural mass or diffuse pleural thickening; c) patients with a mediastinal tumor anteriorly, posteriorly, or in a location that touches the chest wall; e) tumor masses on the chest wall, ribs and vertebrae; f) acoustic window for penetration of the ultrasound beam; and g) patients with normal coagulation status or achieving such during the hospital stay.

Exclusion criteria: a) patients who do not meet the inclusion criteria; b) hemodynamic instability; c) arteriovenous malformation or aneurysm; d) unstable bronchial asthma, severe impairment of lung function; and e) patients with uncontrolled convulsions.

Ultrasound control was carried out using a HITACHI ALOKA f37 device, equipped with a convex biopsy transducer with a side attachment for biopsy with two angles of projection with a frequency in the range of 3.0-5.0 MHz and with the possibility of Doppler ultrasound examination (Fig. 1).

We used GEOTEK Maxicor 16G × 20 cm cutting needles (Fig. 2).

All patients were followed-up after the manipulation for the presence of a complication, and adequate measures were taken in the event of such a complication. Results, discussion, and primary conclusions are based on 264

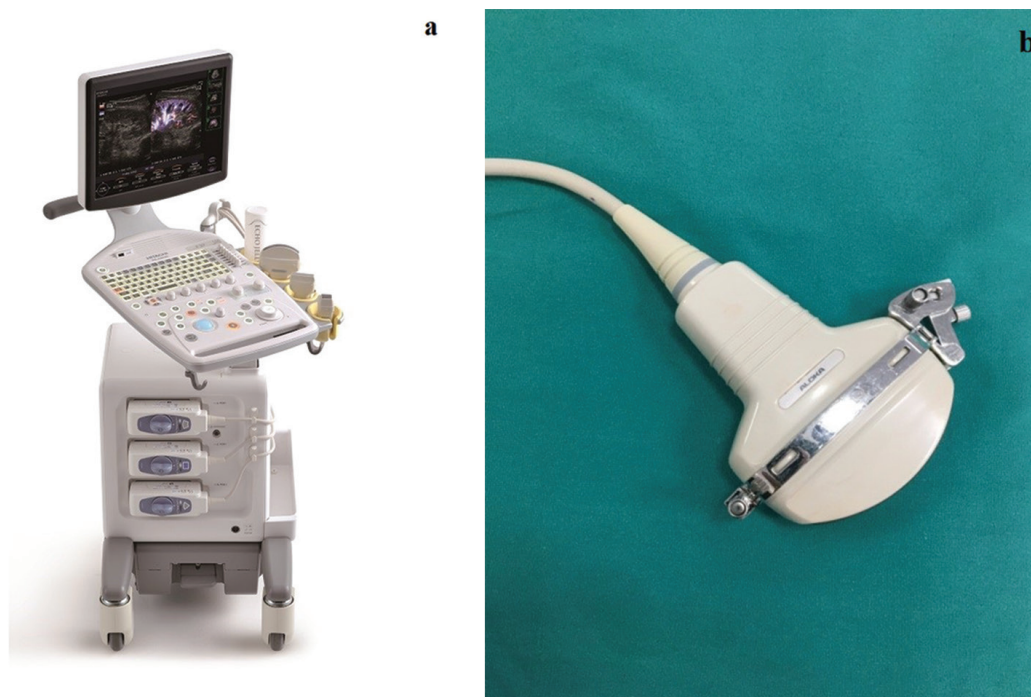


Figure 1. a) Ultrasound device HITACHI ALOKA f37; b) convex transducer with biopsy attachment.

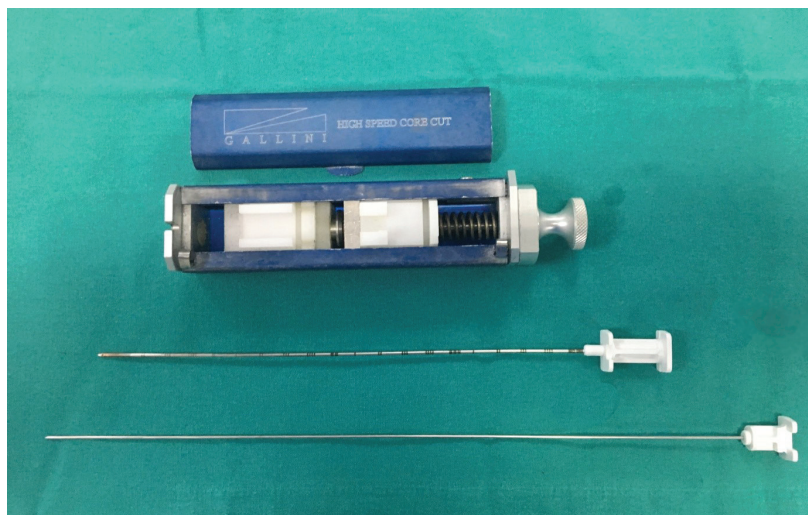


Figure 2. Segmented biopsy needle 16G x 20 cm and a semi-automatic cutting biopsy gun.

patients. In 9 of the cases, it was necessary to repeat the invasive manipulation due to unsatisfactory quality and/or quantity of the initially taken material.

Of the 264 patients included in the study, 188 were men and 76 were women (Fig. 3). The age of the examined patients varied from 13 to 90 years.

The distribution of patients according to the size of peripherally located formations in the chest shows the highest relative share of patients with formations larger than 5 cm, constituting 54.20% (n=143) of the studied group. The difference with the other two categories was statistically significant ($p=0.001$). One hundred and four (39.40%) patients were categorized with formations between 2 cm and 5 cm. This size formations significantly prevailed ($p<0.001$) compared to formations smaller than 2 cm, which were found in 17 patients (6.40%) (Fig. 4). The mean value of the tangent to the chest wall was 2.25 ± 0.69 cm, with a median of 2 cm and a range between 1 cm and 3 cm.

As to the location of tumors, we found 67 (29.70%) tumors in the upper right, 62 (27.40%) in the lower right, 57

(25.20%) in the upper left, and 40 (17.70) in the lower left. The total number amounted to 226 and exceeded the total number of lung neoplasias (n=200) because in some of the cases two locations were found (Fig. 5).

Fig. 6a illustrates the relative proportion of patients with carcinoma in the chest wall and mediastinum. Fig. 6b shows the relative proportion of patients with carcinoma in the chest wall. The relative proportion of patients with carcinoma in the mediastinum is illustrated in Fig. 6c.

RESULTS

Complications were found in 11 (4.17%) out of a total of 264 patients who underwent US-TTCNB. Seven cases of pneumothorax (2.66%), hemoptysis in two (0.76%), hemorrhage in one (0.38%), and vasovagal attack in one (0.38%) were recorded (Table 1).

Because pain at the biopsy site was reported by 49 patients (18.50% of the study group), we examined this sub-

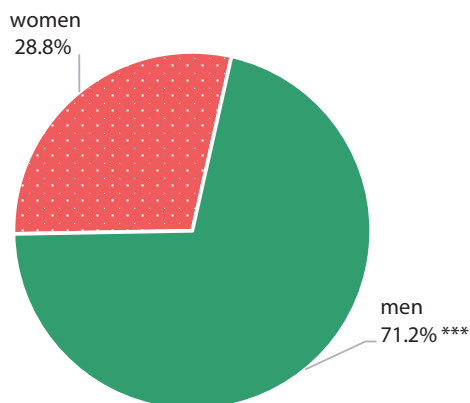


Figure 3. Distribution of patients by sex. All patients underwent a preliminary computed tomography diagnosis.

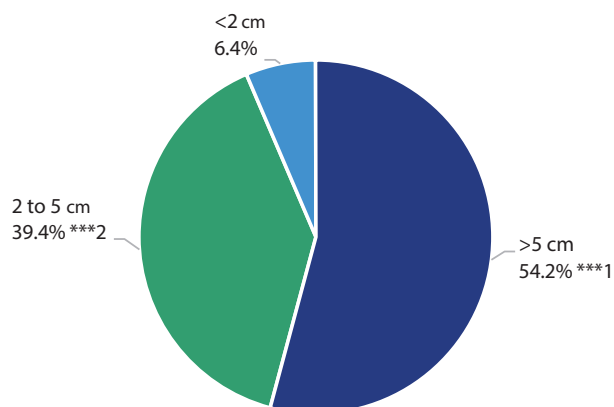


Figure 4. Distribution by size of the peripherally located formation in the chest. ***1 – Significantly higher relative share compared to other sizes ($p=0.001$); ***2 – Significantly higher relative proportion to tumors smaller than 2 cm ($p<0.001$).

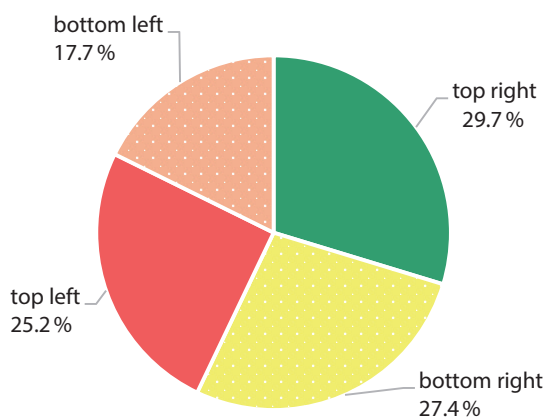


Figure 5. Distribution of tumors by location.

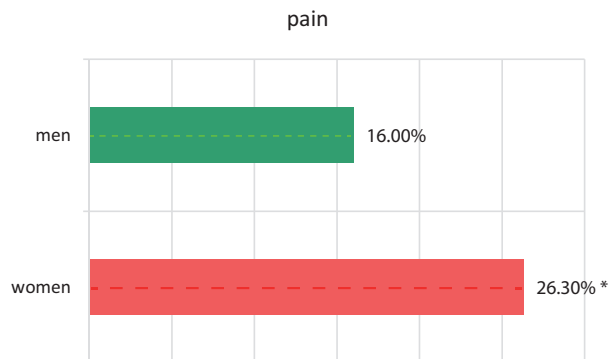


Figure 7. Marginally significant difference between female and male patients regarding pain complaints at the biopsy site after US-TTCNB. * - Marginally significant difference at $p=0.05$.

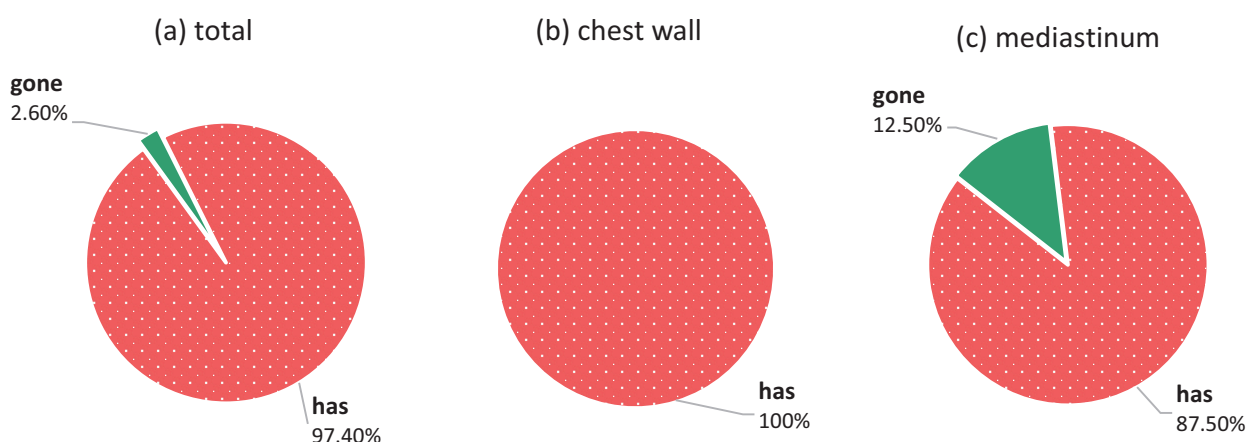


Figure 6. Relative proportion of patients with carcinoma in the chest wall and mediastinum (a); Relative proportion of patients with carcinoma in the chest wall (b); Proportion of patients with mediastinal carcinoma (c).

Table 1. Complications

Complications	Number	Percentage
Pneumothorax	7	2.66%
Hemoptysis	2	0.76%
Hemorrhage	1	0.38%
Vasovagal attack	1	0.38%
Total	11	4.17%

jective factor in our study and correlated it with the patients' sex. A marginally significant difference was found between male and female patients. In particular, 26.30% of the female patients complained of pain at the biopsy site, compared to 16% of the male patients ($p=0.05$) (Fig. 7). No relationship was found between the presence of pain and the size of the tangent to the chest ($p=0.870$).

We also analyzed the relationship between the age of patients and the incidence of complications. For this purpose, age was coded into three categories: up to 50 years ($n=16$), from 50 to 65 years ($n=105$), and over 66 years ($n=143$).

Results showed no significant association between age groups and complication rates (Table 2).

Pneumothorax was the most common complication, but it did not occur in the youngest age group, appearing in 2.90% of the 50-to-65-year-old group and 2.80% of the over-65-year-old group, with no significant difference ($p=0.793$).

Hemoptysis was observed in two patients, one in the age group from 50 to 65 years (1.0%) and the other in the group over 65 years (0.70%).

Hemorrhage in the pleural cavity was found in one patient in the age group of 50-65 years (1.0%, significantly small).

Overall, patients without any complications constituted the highest relative proportion of the youngest group (100%) followed by the 50-to-65-year group (95.23%) and had the lowest relative proportion in the over 66 group (96.5%), but the differences did not reach statistical significance ($p=0.106$).

Table 2. Complications versus age groups

Complications	<50 yrs (n=16)	50 to 65 yrs (n=105)	>65 yrs (n=143)	<i>p</i>
Pneumothorax	0 (0.0%)	3 (2.90%)	4 (2.80%)	0.793 *
Hemoptysis	0 (0.0%)	1 (1.0%)	1 (0.70%)	0.913 *
Hemorrhage	0 (0.0%)	1 (1.00%)	0 (0.0%)	0.468 *
Vasovagal attack	0 (0.0%)	0 (0.0%)	1 (0.70%)	0.654 *
Total				
No complications	16 (100%)	100 (95.23%)	138 (96.5%)	

* The chi-square test was used

We also checked for a potential relationship between the size of the tumor mass and the incidence of complications using the total number of all complications (**Table 3**).

Table 3. Complications vs. size of tumor mass

Complications	<2 cm (n=13)	2-5 cm (n=102)	>5 cm (n=149)
Pneumothorax	1 (7.69%)	3 (2.94%)	3 (2.01%)
Hemoptysis	1 (7.69%)	0 (0.0%)	1 (0.67%)
Hemorrhage	0 (0.0%)	0 (0.0%)	1 (0.67%)
Vasovagal attack	0 (0.0%)	0 (0.0%)	1 (0.67%)
Total			
Complications	2 (15.38%)	3 (2.94%)	6 (4.02%)

Pain at the biopsy site, as a subjective factor, was observed in 6.30% of the patients under 50 years of age, in 18.10% of patients aged 50 to 65 years, and in 21% of patients over 66 years of age.

The percentage difference is small and does not reach statistical significance ($p=0.347$).

DISCUSSION

Based on 264 patients in our study, iatrogenic complications were found in 11 patients (4.17%).

Pneumothorax

Pneumothorax is the most common complication, with a reported frequency ranging from 0 to 61%, with an average of about twenty percent.^[15-23] In our study, it is 2.66% (n=7). Previous research on this relationship has identified factors that contribute to the complication's high frequency rate. The size of the needle is important, as is the researcher's judgment and familiarity with this technique. Older patients (>70 years)^[24,25] are more likely to have COPD and/or emphysema^[26,27], which increases their risk of complications during biopsy. The same is true for people suffering from pulmonary bullous changes. In patients who

underwent surgery of the lung on the same side, the frequency of pneumothorax is significantly lower due to the presence of pleural adhesions occurring after the surgery. Fibrous changes and pleural adhesions "fix" the lung parenchyma and help self-limit the pneumothorax. The patient's lifestyle, age, and comorbidities, the experience of the examiners and the institution in which they work should be considered before resorting to ultrasound-guided biopsy.

If a pneumothorax develops after the surgery, there are a few things that need to be done. Physical observation, vital sign monitoring, appropriate radiographic management, and oxygen administration as needed can all help manage a small, partial pneumothorax (decreased saturation below 90%). The pneumothorax can be manually aspirated^[28] after the intervention with an aspiration system, if it is partial and does not grow (the procedure was performed in one patient). It is also recommended that the patient be placed biopsy-side down and receive oxygen with a nasal catheter. Pneumothorax unchanged after 4 hours under X-ray control are unlikely to grow.^[16,17,22,29] A large pneumothorax with signs of shortness of breath require urgent intervention – the placement of a thin thoracolumbar tube and switching to active aspiration. A tension pneumothorax is a medical emergency: it is a condition that should be treated immediately with needle decompression followed by pleural drainage without waiting for further X-ray and other investigations.

In our study, the pneumothorax in 2 cases (28.57%) was partial, without pronounced clinical and physiological manifestations, which is why it did not require the placement of a thoracic drain. The patients recovered quickly, without the occurrence of new additional complications. In 5 patients (71.42%), the pneumothorax was more significantly manifested with shortness of breath, which is why it was necessary to insert a thin thoracic drain and switch to active aspiration. Our analysis of patients with pneumothorax found that the frequency of this complication is the greatest when attacking changed areas with a small area of stenosis to the parietal pleura, especially those that have no adhesion to it and are mobile during breathing. With area-specific stenting, we have not observed these complications in any case. The presence of bullous changes and emphysematous lung structure increases the risk of pneu-

mothorax. Fibrous changes and pleural adhesions limit the size of the pneumothorax. Forced cessation of respiratory excursions of the lung may sometimes be a reasonable factor in reducing the complication.^[23] The occurrence of pneumothorax is considered risky when the biopsy needle passes through the pleural groove. Biopsied foci with cavitation are also risky due to possible communication of the latter with a bronchus.

Hemorrhage and hemoptysis

Hemorrhage in the pleural cavity after US-TTCNB has an average frequency of 11% according to literature.^[16,17,19,28] In our interventions, we observed hemorrhage in only one patient (0.38%), but it was an insignificant and clinically undetermined hemorrhage. The same one established at video-assisted thoracoscopic surgery was necessary in order to perform an atypical resection of the tumor mass assessed histologically with immunohistochemical examination from the material of the previously performed ultrasound-guided biopsy as a metastasis from colon carcinoma. Bleeding into the lung parenchyma can be seen in approximately 5% to 15% of lung biopsies. Pulmonary parenchymal bleeding after transthoracic biopsies can be diagnosed by lung ultrasound and may present as hemoptysis (seen in 1%-5%)

We observed hemoptysis in two (0.76%) of our patients. It appeared immediately after the intervention, already on the operating table, accompanied by a cough. In one of the patients, it continued over the next 24 hours with decreasing intensity against the background of hemostatic therapy.

Hemorrhages and hemoptyses are considered self-limiting and usually do not require intervention. However, patients should be placed biopsy-side down to prevent aspiration of blood into the contralateral lung.^[30] It is imperative to initiate hemostatic therapy. Massive hemorrhages are very rare but may require anesthesia consultation for intubation with a double-lumen endotracheal tube.^[21] Of course, patients who are taking anticoagulants or have a bleeding diathesis are contraindicated for the intervention until their coagulation status is normalized.

These complications can be prevented by using color Doppler to avoid taking material from areas of the lesion with a rich blood supply and/or suspicion of necrotic changes, as well as a proper assessment of the coagulation status.

We did not observe a hematoma in the area of the chest wall at the biopsy site in our study. We believe that in compliance with the algorithm of behavior when performing the procedure, the risk of hematoma is negligibly small and does not require significant therapeutic measures. The biopsy site should be pressed for a certain time and subsequently treated with an anticoagulant cream.

Vasovagal attack

Vasovagal attack is a rare complication: we observed it in one of our patients (0.38%). It started immediately during

the procedure, after the second biopsy, and continued the next day. It manifested with cyanosis of the face and extremities, hypotension to collapse, tachypnea, and dyspnea. The ECG showed no significant deviations, except for tachycardia. The emergency echocardiography (due to suspicion of a pericardial lesion – the target area was in the immediate vicinity, located in the upper lobe on the left) showed no deviations from the norm. Saturation dropped by 10 units from baseline. After resuscitation, sedatives, and nasal oxygen 3 l/h, the condition was controlled by the next day.

We did not observe hematoma and tumor implantation at the biopsy site as well as air embolism described in the available literature as complications after the procedure.

Pain at the biopsy site

Pain at the biopsy site as a subjective factor during and after US-TTCNB is relevant and, therefore, we analyzed it as well (n=49; 18.50%). Some patients reported pain during the biopsy, which was associated with insufficient analgesia or insufficient waiting time to start the procedure when the anesthetic had not worked. In general, the pain is transient, appears after the analgesia wears off at the intervention site, rarely during the biopsy and very rarely the next day (according to literature data 3.1%). Biopsy is relatively well tolerated by patients and is easily controlled with the administration of analgesics. The difference in the percentages of the data reported in the literature and our study is most likely due to the criteria of the pain reports and whether they occur during the intervention or because of it, after the end of the effect of the infiltrative anesthesia, which, with good infiltration, is negligibly small and can be coped with.

CONCLUSION

Data analysis shows that transthoracic ultrasound biopsy is a method proven to be safe, effective, easy, affordable, real-time traceable and highly accurate for biopsy diagnosis. During the intervention, the actual progress of the needle is monitored. A real assessment of its position relative to the target lesion is made in the different phases of breathing when there is no adhesion with the parietal pleura. This is of great importance in small and/or hard-to-reach outbreaks. Reliable images made by CT within a month, with good resolution and the image reconstruction programs used, allow us to estimate with great accuracy the location of the target lesion and is a first step in conducting the study. Important in our practice regarding the size of the lesion is not its actual size, but the area of stenting. The results show that small lesions under 1.5 cm, with overlying bone structures, regardless of the obtained ultrasound image, are difficult to biopsy due to the impossibility of directing the cutting needle, regardless of a change in trajectory angle. Patient positioning and breathing management, if possible, greatly facilitate the accuracy of the procedure. Precisely planned manipulation in advance reduces the risk of complications

and taking material from an area with necrotic changes. For physically active and fit patients, the time for correct positioning is not missed time. Adherence to the principles of asepsis reduces the occurrence of inflammatory changes in the biopsy area to zero.

Potential errors when performing US-TTCNB can be grouped into several groups:

a) Patient-related factors

The lack of cooperation on his part, as well as some physiological needs, spontaneous coughing, sneezing, occurring at the time of the intervention can prevent its successful implementation and even lead to unwanted complications, especially if the pathological focus is located next to vitally important structures – pericardium, vena cava, aorta, etc.

b) Factors related to the performance technique

It depends largely on the experience of the surgical team performing the intervention. Accurate knowledge of the topographical anatomy of the underlying structures, as well as mastery of the echographic image, ensures the avoidance of these errors. In our case, the use of a 2-cm-launched cutting needle at the time of biopsy should be considered when marking the biopsy trajectory.

c) Factors related to the characteristics of the focus and the surrounding parenchyma

Needle control and positioning in small lesions and hidden under overlying bony structures (ribs, scapula, clavicle) often make ultrasound-guided biopsy difficult and can lead to potential errors. We mentioned that this problem is largely solvable with appropriate positioning of the patient, adjustment of breathing phases, and adjustment of the projection angle of the biopsy attachment.

The performance of US-TTCNB by a surgical team with an acquired thoracic specialty with sufficient experience is essential and a guarantee for successful management of any complications that may arise at the time of the biopsy. The main disadvantage of the intervention is its strong dependence on the experience and qualification of the operator.

Based on our analysis of patients with biopsy-related complications, we recommend the following treatment-diagnostic algorithm:

- Correct and in-depth assessment of the patients undergoing US-TTCNB regarding the specificities of the target lesion, the general and local status, the images from the X-ray examinations and the mental behavior.
- Appropriate positioning of the patient and correctly selected angle and trajectory of the biopsy course.
- Strict laboratory and hematological control and measures for its correction within the hospital stay before the diagnostic manipulation or in home conditions when the intervention is implemented as an outpatient procedure.

Acknowledgements

The authors have no support to report.

Funding

The authors have no funding to report.

Competing Interests

The authors have declared that no competing interests exist.

REFERENCES

1. Benjamin MS, Drucker EA, McCloud TC, et al. Small pulmonary nodules: detection at chest CT and outcome. *Radiology* 2003; 226:489–93.
2. Costello P, Anderson W, Blume D. Pulmonary nodule: evaluation with spiral volumetric CT. *Radiology* 1991; 179:875–6.
3. Mohamed MF, Laz NI, Kamel KM, et al. The role of ultrasound-guided transthoracic Tru-Cut core biopsy in the diagnosis of peripheral thorax lesion. *Egypt J Bronchol* 2021; 15(1):1–2.
4. Rivera MP, Dettlerbeck F, Mehta AC. Diagnosis of lung cancer: the guidelines. *Chest* 2003; 123(1):129S–136S. doi: 10.1378/chest.123.1_suppl.129S
5. Cao BS, Wu JH, Li XL, et al. Sonographically guided transthoracic biopsy of peripheral lung and mediastinal lesions: role of contrast-enhanced sonography. *J Ultrasound Med* 2011; 30:1479–90.
6. Christiansen IS, Clementsen PF, Bodtger U, et al. Transthoracic ultrasound-guided biopsy in the hands of chest physicians – a stepwise approach. *Eur Clin Respir J* 2019; 6:1579632. doi: 10.1080/20018525.2019.1579632
7. Diacon AH, Schuurmans MM, Theron J, et al. Safety and yield of ultrasound-assisted transthoracic biopsy performed by pulmonologists. *Respiration* 2004; 71:519–22.
8. Guo YQ, Liao XH, Li ZX, et al. Ultrasound-guided percutaneous needle biopsy for peripheral pulmonary lesions: diagnostic accuracy and influencing factors. *Ultrasound Med Biol* 2018; 44:1003–11. doi: 10.1016/j.ultrasmedbio.2018.01.016
9. Halifax RJ, Corcoran JP, Ahmed A, et al. Physician-based ultrasound-guided biopsy for diagnosing pleural disease. *Chest* 2014; 146:1001–6.
10. Hussain M, Ashraf M, Chima KK. Diagnostic yield of ultrasound-guided Tru-Cut biopsies of peripheral lesions by the pulmonologist. *Ann Pak Inst Med Sci* 2015; 11(4):215–7.
11. Morvay Z, Szabó E, Tiszlavicz L. Thoracic core needle biopsy using ultrasound guidance. *Ultrasound Q* 2001; 17:113–21.
12. Muhammad H, Muhammad A, Kamran K. Diagnostic yield of ultrasound-guided Tru-Cut biopsies of peripheral lesions by the pulmonologist. *Ann Pak Inst Med Sci* 2015; 11:215–17.
13. Tekin AF, Turgut B, Öncü F. Should we perform transthoracic trucut lung biopsies of pleural-based lung masses under ultrasound guidance or computed tomography guidance? *Ultrasound Quarterly* 2020; 36(1):49–53.
14. Capalbo E, Peli M, Lovisatti M, et al. Trans-thoracic biopsy of lung lesions: FNAB or CNB? Our experience and review of the literature. *Radiol Med* 2014; 119:572–94. doi: 10.1007/s11547-013-0360-1
15. Petkov R. Ultrasound-guided transthoracic cutting needle biopsy in thoracic formations [dissertation]. Sofia: Medical University; 2011.
16. Chockalingam A, Hong K. Transthoracic needle aspiration: the past, present and future. *J Thorac Dis* 2015; 7(Suppl 4):S292–S299. doi:

- 10.3978/j.issn.2072-1439.2015.12.01
17. Birchard KR. Transthoracic needle biopsy. *Semin Intervent Radiol* 2011; 28:87–97.
 18. Husain LF, Hagopian L, Wayman D, et al. Sonographic diagnosis of pneumothorax. *J Emerg Trauma Shock* 2012; 5:76–81
 19. Klein JS, Zarka MA. Transthoracic needle biopsy. *Radiol Clin North Am* 2000; 38(2):235–66.
 20. Lee KH, Lim KY, Suh YJ, et al. Nondiagnostic percutaneous transthoracic needle biopsy of lung lesions: a multicenter study of malignancy risk. *Radiology* 2019; 290:814–23.
 21. Wu CC, Maher MM, Shepard JA. Complications of CT-guided percutaneous needle biopsy of the chest: prevention and management. *Am J Roentgenol* 2011; 196:W678–82.
 22. Zaetta JM, Licht MO, Fisher JS, et al., Bio-Seal Study Group. A lung biopsy tract plug for reduction of postbiopsy pneumothorax and other complications: results of a prospective, multicenter, randomized, controlled clinical study. *J Vasc Interv Radiol* 2010; 21(8):1235–43.
 23. Zhang H, Guang Y, He W, et al. Ultrasound-guided percutaneous needle biopsy skill for peripheral lung lesions and complications prevention. *J Thorac Dis* 2020; 12:3697–705. doi: 10.21037/jtd-2019-abc-03
 24. Hwang HS, Chung MJ, Lee JW, et al. C-arm cone-beam CT-guided percutaneous transthoracic lung biopsy: usefulness in evaluation of small pulmonary nodules. *AJR Am J Roentgenol* 2010; 195:W400–7.
 25. Wiener RS, Schwartz LM, Woloshin S, et al. Population-based risk for complications after transthoracic needle lung biopsy of a pulmonary nodule: an analysis of discharge records. *Ann Intern Med* 2011; 155:137–44.
 26. Cox JE, Chiles C, McManus CM, et al. Transthoracic needle aspiration biopsy: variables that affect risk of pneumothorax. *Radiology* 1999; 212:165–8.
 27. Floridi C, Muollo A, Fontana F, et al. C-arm cone-beam computed tomography needle path overlay for percutaneous biopsy of pulmonary nodules. *Radiol Med* 2014; 119:820–7.
 28. Grasso RF, Cazzato RL, Luppi G, et al. Percutaneous lung biopsies: performance of an optical CT-based navigation system with a low-dose protocol. *Eur Radiol* 2013; 23:3071–6.
 29. Choi CM, Um SW, Yoo CG, et al. Incidence and risk factors of delayed pneumothorax after transthoracic needle biopsy of the lung. *Chest* 2004; 126:1516–21.
 30. Sato M, Omasa M, Chen F, et al. Use of virtual assisted lung mapping (VAL-MAP), a bronchoscopic multispot dye-marking technique using virtual images, for precise navigation of thoracoscopic sublobar lung resection. *J Thorac Cardiovasc Surg* 2014; 147:1813–9.

Осложнения вследствие ультразвуковой трансторакальной режущей биопсии периферических поражений лёгких и поражений грудной стенки и средостения

Димчо Аргиров^{1,4}, Бойко Яворов^{2,4}, Владимир Алексиев^{2,4}, Анастас Чапканов^{1,4}, Филип Щерев^{3,4}, Станислав Картев^{3,4}, Петар Учиков^{1,5}, Заприн Важев^{2,4}

¹ Кафедра специализированной хирургии, Медицинский университет – Пловдив, Пловдив, Болгария

² Кафедра сердечно-сосудистой хирургии, Медицинский университет – Пловдив, Пловдив, Болгария

³ Первая кафедра внутренних болезней, Секция пневмологии и фтизиатрии, Медицинский университет – Пловдив, Пловдив, Болгария

⁴ Клиника грудной хирургии УМБАЛ „Каспела“, Пловдив, Болгария

⁵ Вторая хирургическая клиника, УМБАЛ „Св. Георги“, Пловдив, Болгария

Адрес для корреспонденции: Димчо Аргиров, Кафедра специализированной хирургии, Медицинский университет – Пловдив, Пловдив, Болгария; Email: d_r_argirov@abv.bg

Дата получения: 11 октября 2023 ♦ **Дата приемки:** 9 февраля 2024 ♦ **Дата публикации:** 30 апреля 2024

Образец цитирования: Argirov D, Yavorov B, Aleksiev V, Chapkunov A, Shterev F, Kartev S, Uchikov P, Vazhev Z. Complications due to ultrasound transthoracic cutting biopsy of peripheral pulmonary lesions and lesions in the chest wall and mediastinum. Folia Med (Plovdiv) 2024;66(2):179-187. doi: 10.3897/folmed.66.e114030.

Резюме

Введение: Оценка пациентов с периферическими поражениями лёгких, грудной стенки и средостения является сложной задачей. Природу поражения, выявленного при визуализационных исследованиях, можно определить с помощью гистологической оценки биопсий. Важное место в этом направлении занимает всё возрастающая популярность среди торакальных хирургов трансторакальной биопсии режущей иглой под контролем УЗИ (US-TTCNB).

Цель: Целью данной статьи является описание потенциальных осложнений, которые могут возникнуть при трансторакальной инцизионной биопсии, выполняемой под ультразвуковым контролем, а также алгоритм процентного снижения и подходы к лечению.

Материалы и методы: Настоящее исследование основано на данных 264 пациентов с периферическими поражениями лёгких, грудной стенки и средостения, выявленных с помощью КТ, выполненной в отделении торакальной хирургии Университетской больницы „Каспела“ в Пловдиве в течение 2 лет (январь 2020 г. – декабрь 2021 г.).

Результаты: Осложнения выявлены у 11 (4.17%) пациентов.

Заключение: Наша общепринятая методика биопсии позволяет получить достаточное количество биопсийного материала при низкой частоте постбиопсионных осложнений.

Ключевые слова

КТ, поражения лёгких, трансторакальная инцизионная биопсия под контролем УЗИ, УЗИ