



# Intrathoracic Non-Tuberculous Mycobacteriosis with Endobronchial Lesion in a Child Aged 11 with HIV Infection Diagnosed by Bronchoscopic Biopsy, EBUS-TBNA, and Confocal Laser Endomicroscopy

Igor Vasilev<sup>1</sup>, Igor Mamenko<sup>1</sup>, Roman Simonov<sup>1</sup>, Tatiana Novitskaya<sup>1,2</sup>, Viacheslav Zhuravlev<sup>1</sup>, Petr Yablonskiy<sup>1,2</sup>

<sup>1</sup> Saint Petersburg State Research Institute of Phthisiopulmonology, Saint Petersburg, Russian Federation

<sup>2</sup> Medical Faculty, Saint Petersburg State University, Saint Petersburg, Russian Federation

**Corresponding author:** Igor Mamenko, Saint Petersburg Research Institute of Phthisiopulmonology, 2-4 Ligovsky Ave, Saint-Petersburg, 193232, Russian Federation; Email: dr.mamenko.is@gmail.com; Tel.: +79217790109

**Received:** 9 July 2023 ♦ **Accepted:** 24 Aug 2023 ♦ **Published:** 30 Apr 2024

**Citation:** Vasilev I, Mamenko I, Simonov R, Novitskaya T, Zhuravlev V, Yablonskiy P. Intrathoracic non-tuberculous mycobacteriosis with endobronchial lesion in a child aged 11 with HIV infection diagnosed by bronchoscopic biopsy, EBUS-TBNA and confocal laser endomicroscopy. *Folia Med (Plovdiv)* 2024;66(2):282-286. doi: 10.3897/folmed.66.e109225.

## Abstract

The diagnosis of intrathoracic non-tuberculous mycobacteriosis (NTM) is challenging. We report a case of a pediatric pulmonary NTM with endobronchial lesion and lymphadenitis in a child with HIV infection diagnosed by bronchoscopic biopsy, EBUS-TBNA and probe-based confocal laser endomicroscopy (pCLE). The pCLE showed a large number of highly fluorescent cells and zones of density and disorganized elastin fibers at alveolar areas. A combination of diagnostic endoscopic procedures is required to establish the diagnosis of NTM.

## Keywords

biopsy, bronchoscopy, child, confocal laser endomicroscopy, EBUS-TBNA, endobronchial, HIV-infection, non-tuberculous mycobacteriosis, optical biopsy

## INTRODUCTION

Non-tuberculous mycobacteria (NTM) are ubiquitous in the environment, both in soil, fresh and salt-water sources.<sup>[1]</sup> Pulmonary NTM infection is probably caused by inhalation of aerosol from municipal or private water systems.<sup>[2]</sup> Furthermore, there is the *Mycobacterium avium* complex (MAC) detected in the shower biofilms that is also known to cause NTM infection.<sup>[3]</sup>

NTM infections in children usually present with cervical lymphadenitis. The annual incidence of NTM has been

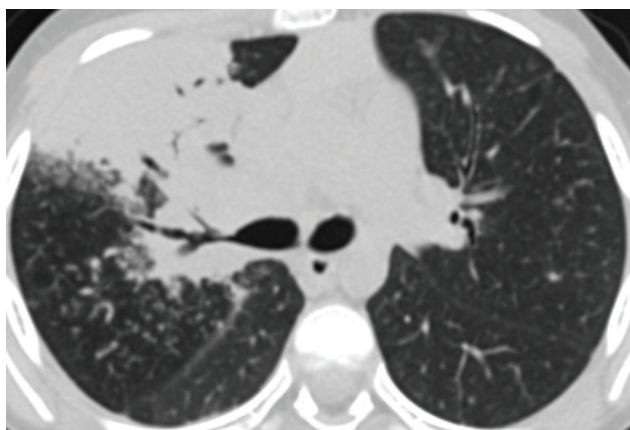
estimated to be 0.84 NTM infections per 100 000 children.<sup>[2]</sup> Pediatric pulmonary NTM infection is a rare condition which is usually seen in immunocompromised patients, such as those with cystic fibrosis, hematologic malignancy, congenital immunodeficiency, or acquired immunodeficiency syndrome caused by HIV infection.<sup>[4,5]</sup> The diagnosis of intrathoracic NTM is challenging and often needs a variety of bronchoscopic methods to obtain respiratory samples for microbiological analysis.<sup>[2,3]</sup> We report here a case of pediatric thoracic non-tuberculous mycobacteriosis with endobronchial lesion and lymphadenitis diagnosed

by bronchoscopic biopsy, EBUS-TBNA and confocal laser endomicroscopy.

## CASE REPORT

An 11-year-old girl was admitted to our clinic with a history of dry cough, fever (up to 38.9°C), weakness, loss of appetite, and night sweats. A diagnosis of HIV infection with severe immunosuppression (CD4 count of 6 cells, viral load 2,700,000 copies/ml) was established in June 2022, when the child was hospitalized due to severe bronchitis and started on antiretroviral therapy. A year ago, when HIV infection was detected in the mother, the child was not examined then. From July 2022 to October 2022, she was treated in several hospitals with a diagnosis of an approved new coronavirus infection (COVID-19). The MSCT scans made in October 2022 revealed a small infiltrate with a cavity in six segments of the right lung and severe intrathoracic lymphadenopathy. Tuberculosis was suspected, but the T-SPOT and multiple sputum tests for mycobacteria were negative. After negative nasopharyngeal swabs in November 2022, the child was transferred to the differential diagnosis department in our clinic. The control MSCT scans showed increase of lymphadenopathy and infiltrates in both lungs, predominantly in the right upper lobe (Fig. 1).

We decided to do a bronchoscopy with transbronchial lung biopsy and endobronchial ultrasound transbronchial needle aspiration of the lymph nodes. We used also the bronchoscopic probe-based confocal laser endomicroscopy (pCLE) method to examine in vivo the airways and alveoli at microscopic level.<sup>[6]</sup> The bronchoscopy was performed under general anesthesia using a laryngeal mask. It showed many grey contact bleeding granulations in the area of the intermediate bronchus and the carina of the upper lobe bronchus, which narrowed the lumen by half to two thirds of its diameter (Fig. 2). The mucosa of the upper lobe and the 1, 2, and 3 segmental bronchi was edematous and thickened, and the lumen of the bronchi was narrowed by three-fourth of the diameter with



**Figure 1.** Infiltrative lesion of the upper lobe of the right lung and increase of paratracheal (2R up to 18×20 mm), and bifurcation (7 to 13×12 mm) lymph nodes.

the flow of viscous secret from the lumen. The probe-based confocal laser endomicroscopy was performed using the Cellvizio system and 1.4-mm Alveoflex probe (Mauna Kea Technologies). The probe was inserted through the instrumental channel of the bronchoscope to 7, 4, 5, 1, 2, and 3 segmental bronchi. At all alveolar areas, a large number of highly fluorescent cells 20–30 µm in diameter were noted, and in the upper segments, zones of density and disorganized elastin fibers were revealed (Figs 3A, 3B, 3C).

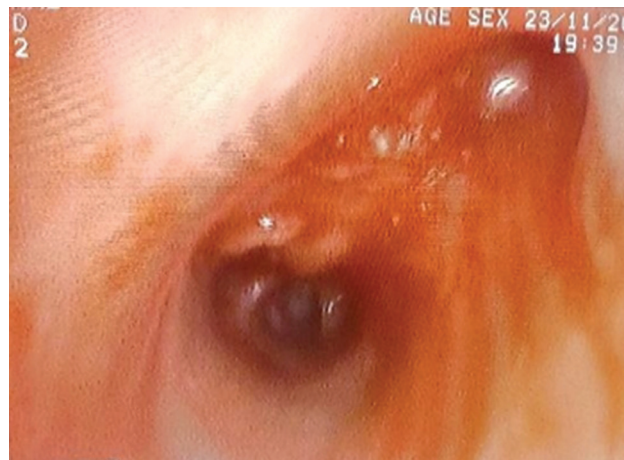
We performed an endobronchial biopsy of the granulations in the upper lobe bronchus and a transbronchial biopsy of segments 1, 2, and 3. We also obtained bronchial washings. Then EBUS-TBNA of the lymph nodes in the region of interlobar carina was performed. Large lymphatic nodules with signs of necrosis were found in an ultrasound study. Samples for histological, PCR examination and culture were taken.

The bronchial washings yielded no useful results. Histological examination of endobronchial biopsy samples revealed fragments of the bronchial wall with granulation tissue and areas of necrosis, mild lymphoid infiltration, and two epithelioid-cell granulomas with giant Langhans cells and one acid-fast bacillus (Fig. 4A). Pathomorphological examination of the transbronchial biopsy samples showed fragments of lung tissue with focal mild fibrosis, granulation tissue, hemorrhage, the presence of fibrin, and areas of necrosis in a part of the alveoli, and no acid-fast bacilli (Fig. 4B). A histological examination of the TBNA samples of lymphatic nodules revealed fragments of lymph node tissue and coagulation necrosis with focal leukocyte infiltration with no acid-fast bacilli (Fig. 4C).

But the PCR examination and culture (BACTEC) from lymph node samples detected NTM of *Mycobacterium avium* complex. The patient was started on a treatment for the MAC infection.

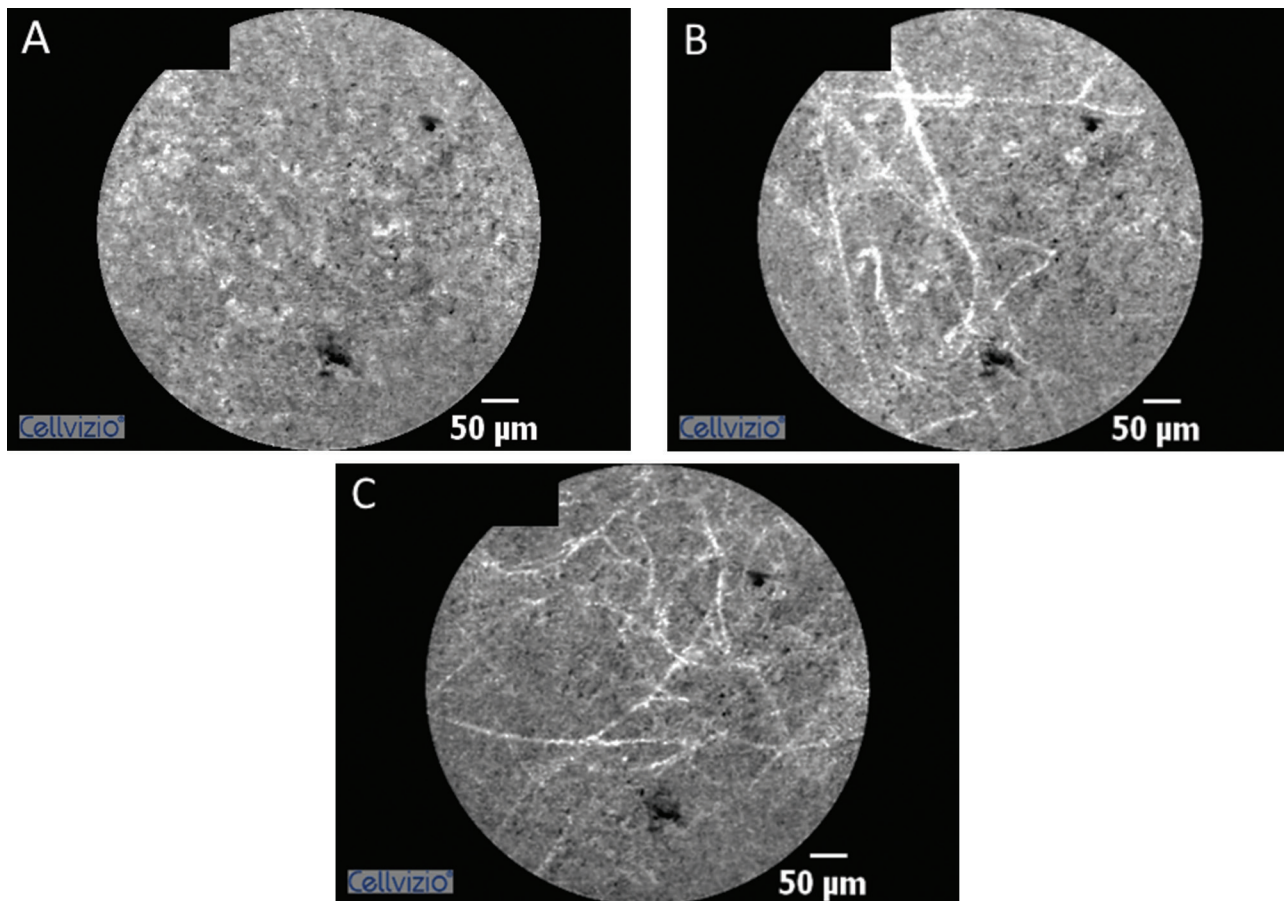
## DISCUSSION

Thoracic non-tuberculous mycobacteriosis is a rare disease in children, usually seen in immunodeficient pa-

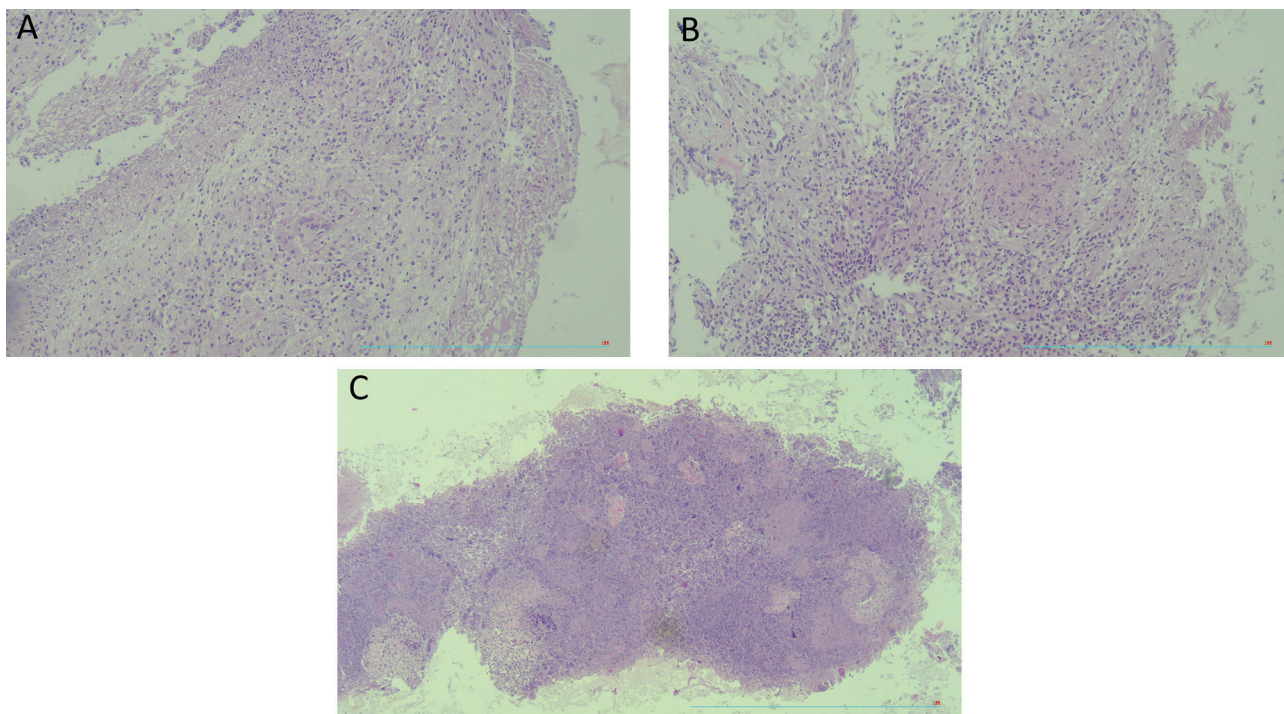


**Figure 2.** A large number of actively bleeding granulations in the region of interlobar carina at bronchoscopy.





**Figure 3.** pCLE images in the alveolar areas of right upper lobe segments. **A.** A large number of highly fluorescent cells; **B.** A zone of disorganized alveolar fibers and fluorescent cells; **C.** A zone of density of alveolar elastin fibers.



**Figure 4.** Histological examination of biopsy samples. **A.** Granulation tissue, epithelioid cell granuloma with Langhans cells on the bronchial wall (hematoxylin and eosin,  $\times 100$ ); **B.** Epithelioid cell granulomas in the area of granulation tissue in the lung (hematoxylin and eosin,  $\times 100$ ); **C.** Fragments of coagulative necrosis with focal leukocyte infiltration, nuclear detritus in lymphoid tissue (hematoxylin and eosin,  $\times 40$ ).

tients with HIV infection but could occur in healthy subjects as well.<sup>[2,4,5]</sup>

An endobronchial lesion of NTM infection is even rarer, requiring a differential diagnosis with tuberculosis and malignancy.<sup>[1,3,4]</sup> It is believed that the endobronchial granuloma is the result of the reaction to the penetration of the bronchial wall by material from adjacent lymphadenitis.<sup>[1]</sup> The key to the diagnosis of intrathoracic non-tuberculous mycobacteriosis is identification of NTM. Positive cultures of sputum are difficult to obtain in the pediatric patient. Therefore, endoscopic techniques for obtaining material for culture are important. We found no data on the sensitivity and specificity of the bronchoscopic techniques in NTM as non-tuberculous mycobacteriosis of the lungs in children is a rather rare pathology. EBUS-TBNA is considered a safe and highly effective (diagnostic yield is about 98%) tool for diagnosing lymphadenopathy in children.<sup>[7]</sup> Since NTM in culture grows for a long time, the PCR analysis is also important for faster identification of the infection.<sup>[2]</sup>

In this case, we used three types of sampling - endobronchial, transbronchial lung, and transbronchial needle biopsy of lymph nodes. And only the EBUS-TBNA allowed us to identify the NTM by PCR and culture examination. This demonstrates that we should use all available tools to diagnose such a complex disease as intrathoracic NTM infection.

We also used in this case the so-called 'optical biopsy' - the probe-based confocal laser endomicroscopy. Using pCLE to diagnose lung diseases in children is reported only in a few publications.<sup>[8,9]</sup> To the best of our knowledge, we present here the first pCLE pictures of a child with pulmonary NTM infection in the scientific literature. Earlier, our group published an article about the comparison of pCLE pictures between adult patients with tuberculosis and NTM infection. The key differences were the existence of fluorescent alveolar cells in tuberculosis patients and their absence in NTM.<sup>[10]</sup> But in the present case, we can see in a child with NTM a large number of fluorescent cells in all investigated segments. This feature requires additional investigation; however, we believe that the presence of fluorescent cells in alveoli may be connected with severe cellular and necrotic inflammation in lung tissue or/and the patient's positive HIV status.

## CONCLUSIONS

Children's intrathoracic non-tuberculous mycobacteriosis is a challenging condition to diagnose, necessitating the use of a range of tools such as endobronchial, transbronchial, and EBUS-TBNA biopsies. Confocal laser endomicroscopy is a promising diagnostic tool that needs more research in children with varied clinical disorders.

## Acknowledgements

The authors have no support to report.

## Funding

The authors have no funding to report.

## Competing Interests

The authors have declared that no competing interests exist.

## Author contributions

I.V.: study conception, data analysis and interpretation, writing of the manuscript; I.M.: study conception and design, data collection, analysis and interpretation, critical revision with the introduction of valuable intellectual content, writing of the manuscript, R.S.: study conception, data analysis and interpretation, critical revision with the introduction of valuable intellectual content; T.A.N.: data collection, analysis and interpretation, drafting of the manuscript, critical revision with the introduction of valuable intellectual content; V.Z.: data collection, analysis and interpretation, drafting of the manuscript, critical revision with the introduction of valuable intellectual content; P.Y.: research supervision, critical revision with the introduction of valuable intellectual content, approval of the final version of the manuscript for publication.

## REFERENCES

1. Lind CS, Bennet R, Papatziarnos G. Endobronchial Mycobacterium avium infection in an immunocompetent child. *Int J Pediatr Otorhinolaryngol Extra* 2017; 18:5–8.
2. López-Varela E, García-Basteiro AL, Santiago B, et al. Non-tuberculous mycobacteria in children: muddying the waters of tuberculosis diagnosis. *Lancet Respir Med* 2015; 3(3):244–56. doi: 10.1016/S2213-2600(15)00062-4
3. Litman DA, Shah UK, Pawel BR. Isolated endobronchial atypical mycobacterium in a child: a case report and review of the literature. *Int J Pediatr Otorhinolaryngol* 2000; 55:65–8.
4. Kavookjian H, Jones JW, Shah S, et al. Endobronchial non-tuberculosis mycobacterium infection presenting in a healthy child. *Ann Otol Rhinol Laryngol* 2018; 127(10):726–30. doi: 10.1177/0003489418784970
5. Hoyt L, Oleske J, Holland B, et al. Non-tuberculous mycobacteria in children with acquired immunodeficiency syndrome. *Pediatr Infect Dis J* 1992; 11(5):354–60.
6. Mamenko I, Vasilev I, Tabanakova I, et al. In vivo confocal laser endomicroscopy in diagnosis of disseminated lung diseases (review and own data). *Medical Alliance* 2018; 2:61–8 [Russian].
7. Madan K, Iyer H, Madan NK, et al. Efficacy and safety of EBUS-TBNA and EUS-B-FNA in children: A systematic review and meta-analysis. *Pediatr Pulmonol* 2021; 56(1):23–33. doi: 10.1002/ppul.25124
8. Shavrov AA, Kharitonova AY, Shavrov Jr AA, et al. Confocal laser endomicroscopy of the respiratory tract in children. *Russian Pediatric Journal* 2014; 5:27-30 [Russian].

9. McHendry C, Towe C, Moore S, et al. The feasibility of probe-based confocal endomicroscopy (pCLE) in children. *Am J Respir Crit Care Med* 2016; 193:A4766.
10. Mamenko I, Vasilev I, Tabanakova I, et al. Comparison of probe-based confocal laser endomicroscopy images in patients with pulmonary TB and non-tuberculous mycobacteriosis: Preliminary report. *Eur Respirat J* 2019; 54:PA3401; doi: 10.1183/13993003.congress-2019.PA3401

## Внутригрудной нетуберкулёзный микобактериоз с эндобронхиальным поражением у ребёнка 11 лет с ВИЧ-инфекцией, диагностированной с помощью бронхоскопической биопсии, EBUS-TBNA и конфокальной лазерной эндомикроскопии

Игорь Васильев<sup>1</sup>, Игорь Маменко<sup>1</sup>, Роман Симонов<sup>1</sup>, Татьяна Новицкая<sup>1,2</sup>, Вячеслав Журавлёв<sup>1</sup>, Пётр Яблонский<sup>1,2</sup>

<sup>1</sup> Санкт-Петербургский государственный научно-исследовательский институт фтизиопульмонологии, Санкт-Петербург, Российская Федерация

<sup>2</sup> Медицинский факультет, Санкт-Петербургский государственный университет, Санкт-Петербург, Российская Федерация

**Адрес для корреспонденции:** Игорь Маменко, Санкт-Петербургский государственный научно-исследовательский институт фтизиопульмонологии, Санкт-Петербург, Лиговский проспект №2-4, 193232 Российская Федерация; Email: dr.mamenko.is@gmail.com; тел.: +79217790109

---

**Дата получения:** 9 июля 2023 ♦ **Дата приемки:** 24 августа 2023 ♦ **Дата публикации:** 30 апреля 2024

---

**Образец цитирования:** Vasilev I, Mamenko I, Simonov R, Novitskaya T, Zhuravlev V, Yablonskiy P. Intrathoracic non-tuberculous mycobacteriosis with endobronchial lesion in a child aged 11 with HIV infection diagnosed by bronchoscopic biopsy, EBUS-TBNA and confocal laser endomicroscopy. *Folia Med (Plovdiv)* 2024;66(2):282-286. doi: 10.3897/folmed.66.e109225.

---

### Резюме

Диагностика внутригрудного нетуберкулёзного микобактериоза (НТМБ) является сложной задачей. Мы сообщаем о случае детского лёгочного НТМБ с эндобронхиальным поражением и лимфаденитом у ребёнка с ВИЧ-инфекцией, диагностированной с помощью бронхоскопической биопсии, EBUS-TBNA и зондовой конфокальной лазерной эндомикроскопии (pCLE). pCLE показал большое количество высоко флуоресцентных клеток и зоны плотности и дезорганизованных волокон эластина в альвеолярных областях. Для установления диагноза НТМБ необходима комбинация диагностических эндоскопических процедур.

### Ключевые слова

биопсия, бронхоскопия, ребёнок, конфокальная лазерная эндомикроскопия, EBUS-TBNA, эндобронхиальная, ВИЧ-инфекция, нетуберкулёзный микобактериоз, оптическая биопсия

---