



Comparative Analysis of Root Dentin Loss when Using Modern Mechanical Cleaning Instruments in Immature Permanent Teeth

Krasimir Hristov¹, Natalia Gateva¹, Pavel Stanimirov², Nikolay Ishkitiev³, Liliya Doitchinova¹

¹ Department of Pediatric Dentistry, Faculty of Dental Medicine, Medical University of Sofia, Sofia, Bulgaria

² Department of Oral and Maxillofacial Surgery, Faculty of Dental Medicine, Medical University of Sofia, Sofia, Bulgaria

³ Department of Chemistry and Biochemistry, Faculty of Medicine, Medical University of Sofia, Sofia, Bulgaria

Corresponding author: Krasimir Hristov, Department of Pediatric Dentistry, Faculty of Dental Medicine, Medical University of Sofia, 1 St Georgi Sofiyski St., 1431 Sofia, Bulgaria; E-mail: khristov87@gmail.com.

Received: 28 Aug 2019 ♦ **Accepted:** 24 Nov 2019 ♦ **Published:** 30 June 2020

Citation: Hristov K, Gateva N, Stanimirov P, Ishkitiev N, Doitchinova L. Comparative analysis of the loss of root dentin when using modern mechanical cleaning instruments in immature permanent teeth. *Folia Med (Plovdiv)* 2020;62(2):352-7. doi: 10.3897/folmed.62.e39515.

Abstract

Introduction: Full decontamination and disinfection of the root canal system is essential for the success of regenerative endodontic procedures. The relevant literature has little information on the mechanical cleaning of immature teeth with modern endodontic instruments.

Aim: To compare the thickness and volume of the dentin removed from the roots of immature teeth after endodontic preparation using XP-endo Finishers, Gentlefile Brushes and a standard H-file scraping technique through micro-computed tomography.

Materials and methods: The study included 51 immature permanent molars. Endodontic access was prepared and without performing preliminary pulp extirpation, the teeth were divided into three groups. The teeth in the Group 1 were instrumented for two minutes with an XP-endo finisher, Group 2 teeth – for two minutes with a Gentlefile Brush; in Group 3, the root canal walls were scraped with a No. 40 H-file. The thickness and the volume of the removed dentin was assessed using micro-CT imaging before and after the use of the instruments.

Results: There was no statistically significant difference in the mean thickness of dentin removed between the teeth prepared with the XP-endo finisher and the Gentlefile Brush. When comparing the mean values of volume of dentin removed between the separate groups, a statistically significant difference was found for every compared pair with the highest volume of removed dentin in the group prepared with a hand instrument.

Conclusion: When the endodontic systems we tested are used to scrape the root canal in immature permanent teeth the amount of hard dental tissue is significantly less than that obtained using a hand file.

Keywords

immature permanent teeth, Gentlefile Brush, XP-endo finisher, regenerative endodontics

INTRODUCTION

Complete decontamination and disinfection of the root canal system is essential for the success of regenerative endodontic procedures.^{1,2} According to some authors, this includes only irrigating the root canal in immature permanent teeth with sodium hypochlorite and chlorhexidine.³⁻⁵ Revitalization protocols without mechanical instrumentation of the root canal allow the preservation of vital stem cells and reduce the risk of additional weakening of already the thin root canal walls.⁶⁻⁸ Other researchers insist that minimal mechanical instrumentation of dentin walls is also necessary, but the current literature does not accentuate on this.³ The authors³ implementing such mechanical instrumentation only describe it as careful instrumentation of the root canal using K-files⁹ and minimal instrumentation without dentin removal.¹⁰⁻¹²

The proposed thinning of the walls in immature permanent teeth is valid when using classic endodontic instruments which shape a predominantly round final form of the preparation, regardless of the canal's initial shape.¹³ The progress in the field of engineering science and the creation of new endodontic instruments allowing for three-dimensional and at the same time minimal hard dental structures removal is not taken into account. Such instruments include XP-endo Finisher (FKG Dentaire SA, Switzerland) and Gentlefile Brush (MedicNRG Ltd., Israel).

XP-endo Finisher shows an improvement of the cleaning capabilities of currently known nickel-titanium reciprocating or rotational instruments. They are made from a special alloy, NiTi MaxWire® (martensite-austenite-electropolished-fleX). This material has a different behavior in different temperatures and is very flexible. The files "remember" their shape. They are straight in their M-phase at room temperature and when they enter the canal, they warm up to body temperature, they change their shape thanks to the molecular memory in their A-phase. The shape of the file in its A-phase allows the access to and cleaning of spaces otherwise inaccessible with standard instruments.¹⁴ The files can be manually straightened after cooling (M-phase). Made from this exceptionally flexible alloy and thanks to the special shape they take, the XP-endo Finisher files follow the contour of the canal's wall with an extended range of 3 mm in diameter or more than any other standard instrument of the same size. The XP-endo Finisher files are capable of instrumenting canals with complex morphology – from the narrowest to the widest.¹⁴⁻¹⁷ The XP-endo Finisher, as an irrigation agitation technique, may help to remove biofilm from hard-to-reach areas in the root canal system.¹⁸

Gentlefile is a new root canal instrumentation system that in the manufacturer's opinion allows for preservation of more tooth structures, cleaning of a larger surface of the canal's wall and possibility of irrigation up to the dental apex. This system allows for optimal control of the usual nickel-titanium instruments winding to the apex. The instruments are extremely flexible and are adapted to any ca-

nal shape. Coronary access widening is not necessary. Gentlefile preserves the original shape of the canal, ensuring symmetrical reduction of dentine layer from the canal walls. It ensures high-energy activation of the irrigation solutions over the entire length of the canal. This enables the effective instrumentation of canals with complex morphology.¹⁹ The file's multiple layer structure provides unique flexibility over its entire length.¹⁹ Gentlefile uses a new approach for instrumentation of the canals which leads to removal of an even layer of very fine debris, described as dentine "dust". This system also includes one instrument just for activation of the irrigants in the canals – Gentlefile Brush. It activates the sodium hypochlorite at a speed of 6500 rpm, removing the rest of the debris located primarily in the apical third. It destroys the residual biofilm attached to the canal's wall using its outspread brush-like end during the file's movement by the endomotor. The centrifugal movement creates a vortex and activates the solution. At the handpiece's high speed the brush is outspread and fills the entire diameter of the canal. That way the debris cleaning is achieved and the contact of the disinfecting solution with its entire dentine surface is ensured.²⁰

The purpose of this study was using an X-ray microtomograph and a 3D image reconstruction to compare the thickness and volume of the dentin removed after endodontic preparation using these two modern systems and a standard H-file scraping technique. The hypothesis tested is that the removed thickness and volume of root dentin after endodontic preparation of immature permanent teeth with the new types of files are less than those achieved by standard H-file scraping technique.

MATERIALS AND METHODS

The study included 51 permanent third molars extracted for orthodontic reasons from patients aged 15 – 19 years. A signed informed consent was obtained by the patients/parents for their inclusion in the study. The teeth were at a stage with developed root walls, close to the final length or developed root walls with non-developed apex. After extraction, the gingival and periodontal tissues were removed by scraping the root with a scalpel and a No. 15 blade. The teeth were cleaned using gauze soaked in hydrogen peroxide solution and were stored in a 10% formaldehyde solution for two weeks. A silicone key was prepared for each tooth (HD Elite Putty, Zhermack, Germany), which covers part of the tooth's crown and has the purpose of properly placing the specimen before and after scanning. SkyScan 1272 (Bruker, United States), X-ray tube voltage 100 kV and current amperage 100 μ A, and a 0.55 mm copper filter was applied. The beam was conical in shape and the size of a single voxel (3D pixel) varied between 10 and 12 μ m depending on the tooth's size.

After that an endodontic access was prepared, during which using a round diamond No. 16 (314 801 016, Axis Dental, Switzerland) bur and a turbine handpiece, a part

of the occlusal enamel was removed, following the contour of the classical endodontic access. A carbide cylindrical bur (Endo Z bur, Dentsply Sirona, Ballaigues, Switzerland) with an inactive tip mounted on a turbine handpiece was used for final shaping of the endodontic access. Working length was determined by inserting a size 15 file into the root canal until the tip of the file was just visible at the apical foramen: the working length was set 0.5 mm short of the apical foramen. One investigator with experience performed cleaning and shaping of the canals. Without performing preliminary extirpation of the pulp from the root canal, the teeth were divided into three groups:

1. The teeth in group 1 were instrumented for two minutes with XP-endo Finisher at a speed of 800 rpm and a torque of 1 N.cm⁻¹. We opted for this duration of the procedure in order to simulate a clinical protocol in which the file is used for one minute with sodium hypochlorite and one minute with EDTA;

2. Group 2 teeth were instrumented for two minutes with Gentlefile Brush by using the manufacturer proposed handpiece with fixed work settings;

3. Group 3 had their root canal walls scraped with a No. 40 H-file (H-file Readysteel, Dentsply Maillefer, Switzerland) using circumferential filing.

The teeth were returned in the prepared silicone keys and a second scan was performed using the same settings of the instrument. After that a 3D image reconstruction was performed using commercial software, InstaRecon, provided with the SkyScan 1272 tomograph and the quantity data were extracted using the company Bruker's CTan software.

For the difference before and after the root's instrumentation the structure thickness and its distribution were calculated. The structure thickness is determined by a software method of the distribution of spheres covering entirely a given object and are entirely inscribed into it. The interpretation of structure thickness depends on the shape of the object for which it is calculated. In this case the part removed from the teeth has the shape of a surface with determined thickness and the structure thickness has the meaning of mean thickness of the material removed from the tooth.

Statistical analysis

Statistical analysis of the results obtained was done using SPSS-19. A parametrical test was used (t-test) for the differ-

ence in main values at a 95% level of significance. $P < 0.05$ indicated statistically significant differences.

RESULTS

The mean values of the dentin thickness removed after preparation with Gentlefile Brush (group 1), XP-endo Finisher (group 2) and H-file (group 3) are provided in **Fig. 1**.

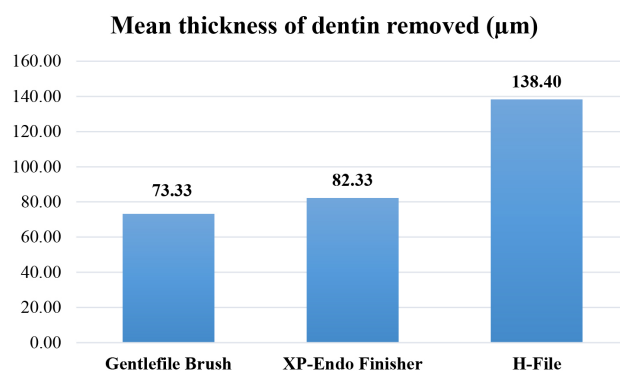


Figure 1. Mean values of the dentin thickness removed after preparation with Gentlefile Brush, XP-Endo Finisher and H-file.

The registered mean values of dentin thickness removed were mutually compared and are shown in **Table 1**.

When comparing the mean values of thickness of dentin removed, no statistically significant difference between group 1 and group 2 was found (Gentlefile Brush – XP-endo Finisher, $p > 0.05$, **Table 1**). A statistically significant difference in the mean values of thickness of dentin removed was found between Groups 1 and 3 (Gentlefile Brush – H-file) and Groups 2 and 3 (XP-endo – H-file) ($p < 0.05$, **Table 1**).

The mean values of volume of dentin removed after preparation with Gentlefile Brush, XP-endo Finisher and H-file are shown in **Fig. 2**.

A comparative review was also performed between the registered mean values of volume of dentin removed between the separate groups and it is shown in **Table 2**.

When comparing the mean values of volume of dentin removed between the separate groups, a statistically significant difference was found for every compared pair ($p < 0.05$), i.e. there is a statistically significant difference between the three studied groups.

Table 1. Comparison of mean removed dentin thickness in the different groups

	Mean±SD	Min	Max
Group 1 - Gentlefile	73.333±15.235	47.00	96.00
Group 2 - XP-Endo Finisher	82.333±21.752	66.00	106.00
Group 3 - H-file	138.395±31.841	114.00	203.00
	$t_{1,2} = 1.438$	$t_{1,3} = 7.82$	$t_{2,3} = 6.168$
	$p_{1,2} = 0.161$	$p_{1,3} = 0.000$	$p_{2,3} = 0.000$

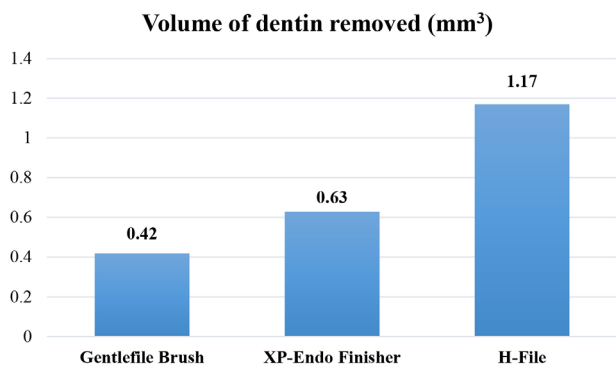


Figure 2. Mean values of volume of dentin removed after preparation with Gentlefile Brush, XP-Endo Finisher and H-file.

Table 2. Comparison of mean dentin volume removed in the different groups

	Mean±SD	Min	Max
Group 1: Gentlefile	0.418±0.205	0.15	0.73
Group 2: XP-Endo Finisher	0.648±0.260	0.18	0.99
Group 3: H-file	1.13±0.683	0.59	2.55
	$t_{1,2} = 2.946$	$t_{1,3} = 4.235$	$t_{2,3} = 2.797$
	$P_{1,2} = 0.006$	$P_{1,3} = 0.000$	$P_{2,3} = 0.008$

Fig. 3 shows a reconstructed image of the quantity of dental structures removed according to the three protocols for root canal instrumentation.

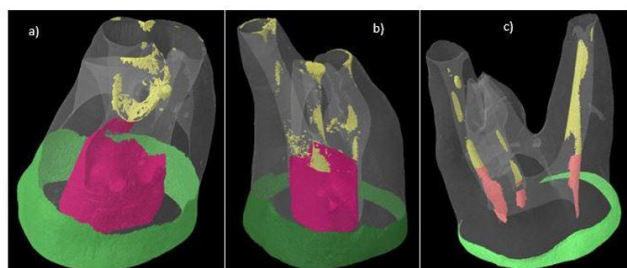


Figure 3. Reconstruction of instrumentations and therefore structures thickness in: a) Gentlefile Brush, b) XP-Endo Finisher, c) H-file. (colour coded are green – enamel, purple – dentin removed from the pulp chamber, and yellow – dentin removed from the root canals).

DISCUSSION

An important task in treating immature permanent teeth with necrotic pulp is the elimination of bacteria and debris from the root canal but without removing or with removing as little dentin as possible. The endodontic instrumentation aiming at the removal of debris from the root canal of such teeth can be compared to instrumentation of a very large and oval root canal – a problem researched by modern endodontics.^{14,21}

Although there are a wide variety of endodontic files with different qualities of the alloy they are made from, they shape primarily a round end shape of the preparation regardless of the canal’s initial shape. The clinician’s ability is to remove the biofilm from the walls of the canal using files with round shape by creating a round preparation is severely limited.¹³

The perfect case is for the oval canal’s preparation to correspond to the canal’s original shape, to be symmetrical and not to lead to dentin walls thinning.¹⁴

This study compares the impact of two contemporary endodontic systems on the geometry of the root canal and the quantity loss of dentin. These systems have been cre-

ated particularly for reaching larger widening and functioning better in anatomically complex canals compared to conventional instruments.^{14,19}

In our study we established that the thickness of dentin removed when using XP-endo Finisher and Gentlefile Brush is less when compared to the debris from the canal using a file (**Fig. 1**). At the same time the least amount of dentin removed occurs when using the Gentlefile Brush, followed by XP-endo Finisher and the most is when using a hand file (**Fig. 2**). This confirmed hypothesis tested by us that the systems investigated lead to removal of different amount of root dentin with comparable thickness. Currently several studies examine the XP-endo Finisher instruments and their ability to remove debris, microorganisms and calcium hydroxide in teeth with complete root development and they demonstrate their increased efficacy compared to conventional techniques.^{16,22,23} At the same time, the additional activation of irrigants with the Gentlefile Brush significantly removes the pulp leftovers from the root canal in teeth with complete root development.²⁰ In the specialized literature available to us we did not find similar studies in immature permanent teeth which made it difficult for us to compare the results obtained by us.

The accuracy and reproducibility of the micro-X-ray study have been proven before^{24,25} and it is thought to be an important scientific method for analyzing the different preparation techniques.^{26,27} Multiple micro-X-ray studies show the presence of uninstrumented regions after using practically all available instruments and techniques with

following conclusions for possible retention of bacterial biofilm and tissue leftovers from the pulp on the walls not instrumented.^{28,29} Additional studies are needed to assess the XP-endo Finisher and Gentlefile Brush's ability to effectively remove the necrotic pulp and biofilm from the root system of immature permanent teeth, so that they can be recommended when applying regenerative endodontic procedures.

CONCLUSION

The endodontic systems we tested when used in immature permanent teeth remove significantly less quantity of hard dental structures compared to using a hand file for scraping the root canal. This is extremely important in the endodontic instrumentation of immature teeth with necrotic pulp when continuation of root development and apex closure is aimed.

Acknowledgements

This study was supported by the National Science Fund at the Ministry of Education and Science of the Republic of Bulgaria [Grant No DFNI B02/15, 12.12.2014].

REFERENCES

1. Verma P, Nosrat A, Kim J, et al. Effect of residual bacteria on the outcome of pulp regeneration in vivo. *J Dent Res* 2017; 96(1):100-6.
2. Fouad AF. The microbial challenge to pulp regeneration. *Adv Dent Res* 2011; 23(3):285-9.
3. Albuquerque M, Nagata J. Pulp revascularization: an alternative treatment to the apexification. *RGO - Revista Gaúcha de Odontologia* 2014; 62(4):401-10.
4. Banchs F, Trope M. Revascularization of immature permanent teeth with apical periodontitis: new treatment protocol? *J Endod* 2004; 30:196-200.
5. Silva L, Nelson-Filho P, Flores D, et al. Revascularization and periapical repair after endodontic treatment using apical negative pressure irrigation versus conventional irrigation plus triantibioticintra canal dressing in dogs' teeth with apical periodontitis. *Oral Surg Oral Med Oral Pathol Oral Radiol Endod* 2010; 109(5):779-87.
6. Trope M. Regenerative potential of dental pulp. *J Endod* 2008; 34(7):S13-S17.
7. Reynolds K, Johnson JD, Cohenca N. Pulp revascularization of necrotic bilateral bicuspid using a modified novel technique to eliminate potential coronal discoloration: a case report. *Int Endod J* 2009; 42(1):84-92.
8. Gonçalves SB, Dong Z, Bramante CM, et al. Tooth slice-based models for the study of human dental pulp angiogenesis. *J Endod* 2007; 33(7):811-814.
9. Soares S, Lins F, Nagata J, et al. Pulp revascularization after root canal decontamination with calcium hydroxide and 2% chlorhexidine gel. *J Endod* 2013; 39(3):417-20.
10. Kalaskar R, Kalaskar A. Maturation of non-vital immature permanent teeth. *Contemp Clin Dent* 2013; 4(2):268-70.
11. Shimizu E, Jong J, Partridge N, et al. Histologic observation of a human immature permanent tooth with irreversible pulpitis after revascularization/regeneration procedure. *J Endod* 2012; 38(9):1293-7.
12. Chen M, Chen K, Chen C, et al. Responses of immature permanent teeth with infected necrotic pulp tissue and apical periodontitis/abscess to revascularization procedures. *Int Endod J* 2012; 45(2):294-305.
13. Trope M, Debelian G. XP-3D Finisher™ file - the next step in restorative endodontics. *Endodontic Practice US* 2015; 8(5):14-16.
14. Trope M, Debelian G.) Cleaning the third dimension. *Endodontic Practice US* 2015; 8(6):22-24.
15. Živković J, Nešković M, Jovanović-Medojević M. XP-endo finisher: A new solution for smear layer removal. *Serbian Dental Journal* 2015; 62(3):122-129.
16. Leoni GB, Versiani MA, Silva-Sousa YT, et al. Ex vivo evaluation of four final irrigation protocols on the removal of hard-tissue debris from the mesial root canal system of mandibular first molars. *Int Endod J* 2017; 50(4):398-406.
17. Azim A, Aksel H, Zhuang T, et al. Efficacy of 4 irrigation protocols in killing bacteria colonized in dentinal tubules examined by a novel confocal laser scanning microscope analysis. *J Endod* 2016; 42(6):928-34.
18. Bao P, Shen Y, Lin J, Haapasalo M. In vitro efficacy of XP-endo finisher with 2 different protocols on biofilm removal from apical root canals. *J Endod* 2017; 43(2):321-5.
19. Moreinos D, Dakar A, Stone NJ. Evaluation of time to fracture and vertical forces applied by a novel gentlefile system for root canal preparation in simulated root canals. *J Endod* 2016; 42(3):505-8.
20. Neelakantan P, Khan K, Li KY, et al. Effectiveness of supplementary irrigant agitation with the Finisher Gentlefile Brush on the debridement of oval root canals instrumented with the Gentlefile or nickel titanium rotary instruments. *Int Endod J* 2018; 51(7):800-7.
21. Mohammadi Z, Shalavi S, Jafarzadeh H. The oval shaped, root canal: A clinical review. *South African Dental Journal* 2015; 70:200-4.
22. Alves FR, Merceliano-Alves MF, Sousa JC, et al. Removal of root canal fillings in curved canals using either reciprocating single- or rotary multi-instrument systems and a supplementary step with the XP-Endo Finisher. *J Endod* 2016; 42:1114-9.
23. Keskin C, Sariyilmaz E, Sariyilmaz O. Efficacy of XP-endo finisher file in removing calcium hydroxide from simulated internal resorption cavity. *J Endod* 2017; 43:126-30.
24. Bergmans L, Van Cleynenbreugel J, Wevers M, et al. A methodology for quantitative evaluation of root canal instrumentation using micro-computed tomography. *Int Endod J* 2001; 34(5):390-8.
25. Peters OA, Laib A, Rügsegger P, et al. Three-dimensional analysis of root canal geometry by high-resolution computed tomography. *Journal of Dental Research* 2000; 79(6):1405-9.
26. Versiani MA, Pécora JD, de Sousa-Neto MD. Flat-oval root canal preparation with self-adjusting file instrument: a micro-computed tomography study. *J Endod* 2011; 37(7):1002-7.
27. Paqué F, Peters OA. Micro-computed tomography evaluation of the preparation of long oval root canals in mandibular molars with the self-adjusting file. *J Endod* 2011; 37(4):517-21.
28. Zhao D, Shen Y, Peng B, et al. Root canal preparation of mandibular molars with 3 nickel-titanium rotary instruments: a micro-computed tomographic study. *J Endod* 2014; 40:1860-4.
29. Siqueira JE, Alves FR, Versiani MA, et al. Correlative bacteriologic and micro-computed tomographic analysis of mandibular molar mesial canals prepared by self-adjusting file, reciproc, and twisted file systems. *J Endod* 2013; 39(8):1044-50.

Сравнительный анализ потери корневого дентина при использовании современных механических инструментов для чистки незрелых постоянных зубов

Красимир Христов¹, Наталия Гатева¹, Павел Станимиров², Николай Ишкитиев³,
Лилия Дойчинова¹

¹ Кафедра детской дентальной медицины, Факультет дентальной медицины, Медицинский университет – София, София, Болгария

² Кафедра хирургической стоматологии и челюстно-лицевой хирургии, Факультет дентальной медицины, Медицинский университет – София, София, Болгария

³ Кафедра химии и биохимии, Медицинский университет – София, София, Болгария

Автор для корреспонденции: Красимир Христов, Кафедра детской дентальной медицины, Факультет дентальной медицины, Медицинский университет – София, ул. „Св. Георги Софийски“ 1, 1431 София, Болгария; E-mail: khristov87@gmail.com.

Дата получения: 28 августа 2019 ♦ **Дата приемки:** 24 ноября 2019 ♦ **Дата публикации:** 30 июня 2020

Образец цитирования: Hristov K, Gateva N, Stanimirov P, Ishkitiev N, Doitchinova L. Comparative analysis of the loss of root dentin when using modern mechanical cleaning instruments in immature permanent teeth. Folia Med (Plovdiv) 2020;62(2):352-7. doi: 10.3897/folmed.62.e39515.

Резюме

Введение: Полная деконтаминация и дезинфекция системы корневых каналов имеет важное значение для успеха регенеративных эндодонтических процедур. В соответствующей литературе содержится мало информации о механической чистке незрелых зубов современными эндодонтическими инструментами.

Цель: Сравнить толщину и объём дентина, удалённого из корней незрелых зубов после эндодонтического препарирования с использованием XP-endo finisher, Gentlefile Brushes и стандартной H-file техники удаления с помощью микрокомпьютерной томографии.

Материалы и методы: В исследование включены 51 незрелый постоянный моляр. Эндодонтический доступ был обеспечен, и без предварительного удаления пульпы зубы были разделены на три группы. Зубы в группе 1 обрабатывали инструментами в течение двух минут с помощью XP-endo finisher, в группе 2 – в течение двух минут с помощью Gentlefile Brush; в группе 3 корневые каналы были очищены при помощи No. 40 H-file. Толщину и объём удалённого дентина оценивали с помощью микроКТ до и после использования инструментов.

Результаты: Не было статистически значимой разницы в средней толщине удалённого дентина между зубами, обработанными с помощью XP-endo finisher и Gentlefile Brush. При сравнении средних значений объёма удалённого дентина между различными группами была обнаружена статистически значимая разница между каждой сравниваемой парой, и наибольший объём удалённого дентина был в группе, обработанной с помощью ручного инструмента.

Заключение: Когда эндодонтические системы, которые мы тестировали, использовались для очистки корневых каналов незрелых постоянных зубов, количество твёрдой зубной ткани было значительно меньше, чем количество, удалённое с помощью ручного инструмента.

Ключевые слова

Gentlefile Brush, незрелые постоянные зубы, регенеративная эндодонтия, XP-endo finisher