



Regenerative Endodontic Treatment of Immature Permanent Teeth after Mechanical Instrumentation with XP-Endo Finisher

Krasimir Hristov¹, Liliya Doitchinova¹, Natalia Gateva¹

¹ Department of Pediatric Dentistry, Faculty of Dental Medicine, Medical University of Sofia, Sofia, Bulgaria

Corresponding author: Krasimir Hristov, Department of Pediatric Dentistry, Faculty of Dental Medicine, Medical University of Sofia, Sofia, Bulgaria; Email: khristov87@gmail.com

Received: 3 Jan 2022 ♦ **Accepted:** 18 Feb 2022 ♦ **Published:** 30 June 2023

Citation: Hristov K, Doitchinova L, Gateva N. Regenerative endodontic treatment of immature permanent teeth after mechanical instrumentation with XP-Endo Finisher. *Folia Med (Plovdiv)* 2023;65(3):460-467. doi: 10.3897/folmed.65.e80063.

Abstract

Introduction: The traditional treatment of immature permanent teeth with necrotic pulp involves creating an apical barrier by using calcium hydroxide or an MTA plug for an extended period of time. A novel therapeutic approach called regenerative endodontic procedures (REP) is used to allow root development to continue.

Aim: To investigate the response of immature permanent teeth and necrotic pulp to REP using a modified clinical protocol involving minimal mechanical instrumentation and irrigation with 10% citric acid.

Materials and methods: We treated 30 immature permanent teeth with necrotic pulp in 28 patients aged 7-14 years using a modified protocol for regenerative endodontics. The protocol included mechanical instrumentation of the root canal with the appropriate file for 2 minutes in total and irrigation with 10% citric acid.

Results: The root walls increased their thickness in 28 (93%) of the treated cases. In 16 (53%) cases, we found radiographic signs of continued root development; in six (20%), there was thickening of the canal walls and closure of the apex but no elongation; in four (13%), there was obliteration of the root canal; in two (7%), there was healing of the periapical lesion without any change in the length of the root walls or closure of the apex; and only two cases (7%) showed no signs of healing, but the teeth remained asymptomatic.

Conclusions: The use of mechanical instrumentation with the appropriate files in REP shortens the clinical protocol, which is advantageous when treating children's dental issues.

Keywords

immature teeth, mechanical instrumentation, regenerative endodontics, revitalization, XP-Endo Finisher

INTRODUCTION

Traditionally, the treatment of permanent teeth with incomplete root development and irreversible pulpitis or necrotic pulp involves the creation of an apical barrier through prolonged use of calcium hydroxide or an MTA plug before filling the root canal.^[1] Apexification with calcium hydroxide takes several appointments over extended

periods of time, which can lead to an increased risk of root fracture due to the prolonged action of the dressing.^[2] The clinical results in the use of the classical technique and the creation of an artificial plug with MTA are similar.^[3] It is not possible to restore the vitality of the pulp and to stimulate root maturation with these techniques. This shortcoming is overcome by the use of regenerative endodontic

procedures (REP), which are a novel therapeutic approach that allows achievement of root maturation.^[4,5]

AIM

The aim of the present study was to investigate the response of immature permanent teeth and necrotic pulp to REP using a modified clinical protocol involving minimal mechanical instrumentation and irrigation with 10% citric acid.

MATERIALS AND METHODS

This clinical study included 30 permanent teeth with incomplete root development diagnosed with apical periodontitis in 28 patients aged 7-14 years. The distribution

of patients by age, sex, symptoms, pulp condition, and periapical tissues of affected teeth are presented in **Table 1**. Informed consent was obtained from patients' parents by filling out written forms informing them about the treatment, its benefits, and possible risks and complications. The study was approved by the Research Ethics Committee of the Medical University of Sofia, Bulgaria.

There was no response from the teeth to cold or electric pulp test. Nine teeth had a draining sinus tract. There was evidence of periapical osteolytic lesions radiographically. The treated tooth was isolated with a clamp and rubber dam without using local anesthesia. The operating field was disinfected with a swab with povidone iodine solution (Braunol, B Braun, Melsungen, Germany). Access to the pulp chamber was made through the crown according to the accepted guidelines.^[6] The walls of the access cavity were smoothed with carbide bur with inactive tip

Table 1. Distribution of patients by demographic characteristics, symptoms, pulpal and periapical condition

Case	Age years	Sex	Etiology	Tooth	Symptoms	Pulpal condition	Periapical lesion
1	8	f	Caries	36	Sinus track	Necrotic	Yes
2	7	m	Trauma	11	Sinus track	Necrotic	Yes
3	8	m	Trauma	41	-	Necrotic	Yes
4	10	m	Trauma	11	Submucosal abscess	Necrotic	Yes
5,6	8	f	Trauma	11, 21	-	Necrotic	Yes
7	11	m	Caries	36	-	Necrotic	Yes
8	7	m	Caries	46	Sinus track	Necrotic	Yes
9	12	m	Caries	47	-	Necrotic	Yes
10	7	f	Trauma	11	-	Necrotic	Yes
11	8	m	Trauma	12	Submucosal abscess	Necrotic	Yes
12,13	7	f	Trauma	11,21	-	Necrotic	Yes
14	8	m	Caries	46	Sinus track	Necrotic	Yes
15	9	m	Trauma	11	-	Necrotic	Yes
16	9	f	Trauma	21	-	Necrotic	Yes
17	10	m	Caries	46	-	Necrotic	Yes
18	10	f	Trauma	11	-	Necrotic	Yes
19	11	f	Caries	46	-	Necrotic	Yes
20	9	m	Caries	36	Sinus track	Necrotic	Yes
21	7	m	Trauma	21	Sinus track	Necrotic	Yes
22	7	f	Trauma	11	Submucosal abscess	Necrotic	Yes
23	9	f	Caries	46	Sinus track	Necrotic	Yes
24	10	m	Trauma	11	-	Necrotic	Yes
25	8	m	Trauma	21	Submucosal abscess	Necrotic	Yes
26	7	f	Trauma	21	Sinus track	Necrotic	Yes
27	7	f	Trauma	11	-	Necrotic	Yes
28	9	m	Caries	36	Sinus track	Necrotic	Yes
29	14	f	Caries	46	-	Necrotic	Yes
30	7	m	Trauma	12	Submucosal abscess	Necrotic	Yes

(Endo Z bur, Dentsply Sirona, York, Pennsylvania, United States).

The pulp chamber was irrigated with 5.25% sodium hypochlorite solution (Chloraxid, Cerkamed, Poland) in a syringe with an irrigating needle with side opening (Endo Top Irrigation Needles, Cerkamed, Poland). The working length was determined with an apex locator (Raypex 6, VDW, Munich, Germany) and confirmed radiographically. The root canal was prepared for 1 min with XP-Endo Finisher (FKG Dentaire, La Chaux-de-Fonds, Switzerland) and irrigated with 1.5% NaOCl. The canal was dried with sterile paper points. Triple antibiotic paste of clindamycin, metronidazole, and ciprofloxacin in macrogol vehicle was applied as intracanal dressing. Sterile cotton pellet was placed in the pulp chamber and the cavity was sealed with GIC (GC Fuji IX GP, GC Corporation, Tokyo, Japan).

During the second appointment if the clinical symptoms persisted, the treatment protocol was repeated. After resolution of the symptoms, under local anesthesia with solution without epinephrine, the tooth was isolated with rubber dam and the access cavity was re-entered. The triple antibiotic paste was gently flushed out of the canal with 1.5% NaOCl. The canal was irrigated with 10% citric acid and prepared for 1 min with XP-Endo Finisher. Final irrigation with saline was performed and the canal was dried with sterile paper points. Under a dental operating microscope (Smart Optics, Selig Microscopes, Łódź, Poland), bleeding was induced by irritating the periapical tissues using sterile needle (19 mm/27G) (dipsoFINE, Zarys, Poland). Blood clot was formed and a small piece of hemostatic sponge was placed over the clot (Surgispon, Aegis Lifesciences, India). MTA was condensed over the sponge and the cavity was sealed with temporary filling.

One week later, the cavity was re-entered, and the MTA was tested with a probe to ensure its hardness. After that, the tooth was restored with a resin composite. The teeth were clinically and radiographically followed up at 6, 12, 18, and 24 months.

RESULTS

The results of the regenerative endodontic procedure in 30 teeth with incomplete root development and necrotic pulp are presented in **Fig. 1**.

In 28 (93%) of the treated cases, there was an increase in the thickness of the root walls. Sixteen (53%) of the treated cases showed radiographic signs of continued root development (**Fig. 2**). In six of the cases (20%), there was no elongation of the root walls, but there was thickening and closure of the apex (**Fig. 3**). In four of the treated cases (13%) obliteration of the root canal was observed (**Fig. 4**), and in two (7%) - healing of the periapical lesion without changes in the length of the root walls or closure of the apex (**Fig. 5**). Two of the cases (7%) showed no signs of healing process, although the teeth remained asymptomatic (**Fig. 6**).

The first radiographically visible signs of a healing process were observed 6 months after the start of treatment with the disappearance of periapical radiolucency. There was an increase in the thickness and/or length of the root walls after 12 months.

DISCUSSION

There is currently no agreement on which protocol for regenerative endodontic procedures can be advised, despite the fact that many of them have been linked to positive clinical outcomes.

There are some necessary conditions for the clinical success of REP^[7,8]:

- young patients;
- necrotic pulp and immature root;
- minimal or no mechanical treatment of the root canal;
- application of intracanal dressing;
- formation of a blood clot or protein scaffold in the canal;

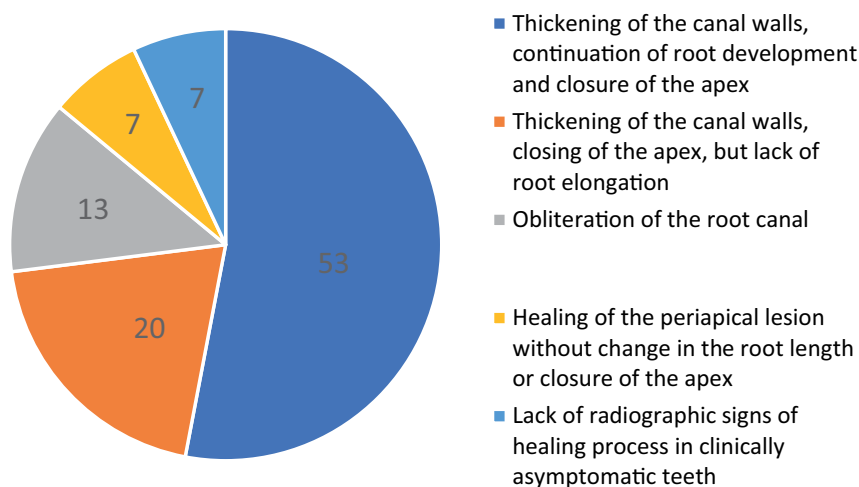


Figure 1. Results of regenerative endodontic procedures in the treatment of immature permanent teeth with necrotic pulp.

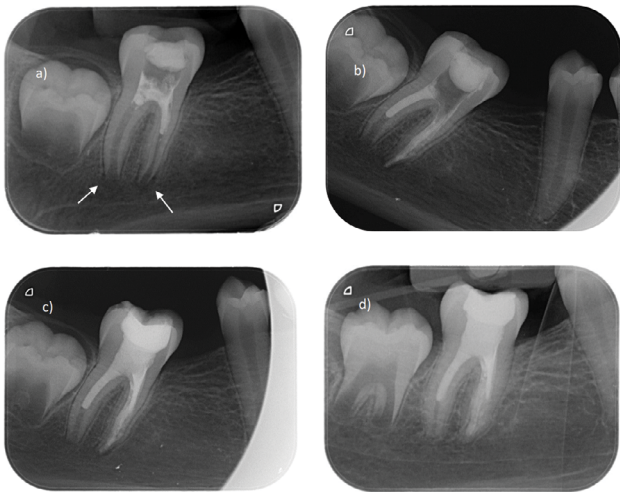


Figure 2. Thickening of the canal walls, continuation of root development and closure of the apical opening. **a)** Initial condition with osteolytic lesion (arrows). The patient was referred after emergency treatment and application of calcium hydroxide; **b)** Radiography immediately after revascularization; **c)** Control after 6 months; **d)** Follow-up after 18 months, showing thickening of the canal walls, continued root development, closure of the apex in the distal root, and healing of the periapical lesion around the mesial root.

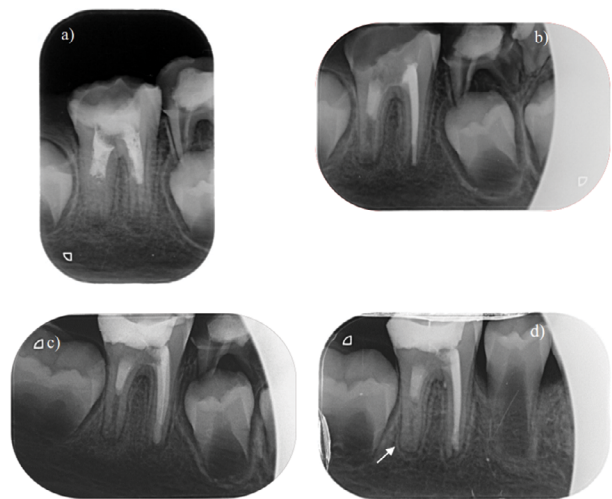


Figure 4. Calcification of the root canal. **a)** Initial X-ray after calcium hydroxide application. The patient was referred after emergency treatment and application of calcium hydroxide for one week; **b)** Follow-up after REP of the distal root and confirmation of the working length for the mesial canals; **c)** Follow-up after 12 months; **d)** Follow-up after 24 months - almost complete obliteration of the distal root and increase in the length of the mesial root has occurred.

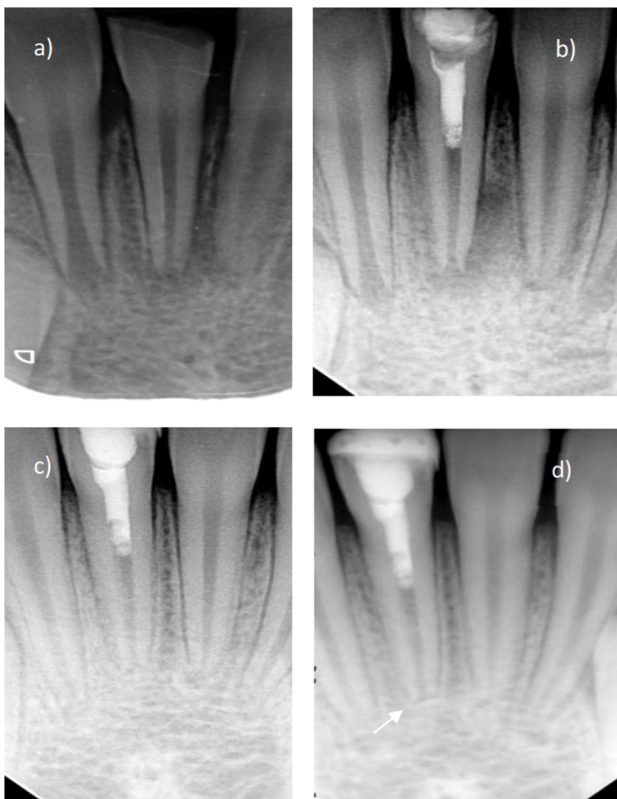


Figure 3. Thickening of the canal walls, closure of the apex, but no elongation of the root. **a)** Initial state; **b)** Radiography immediately after revascularization; **c)** Follow-up after 6 months; **d)** Follow-up after 18 months with thickening of the canal walls and closure of the apex (arrow).

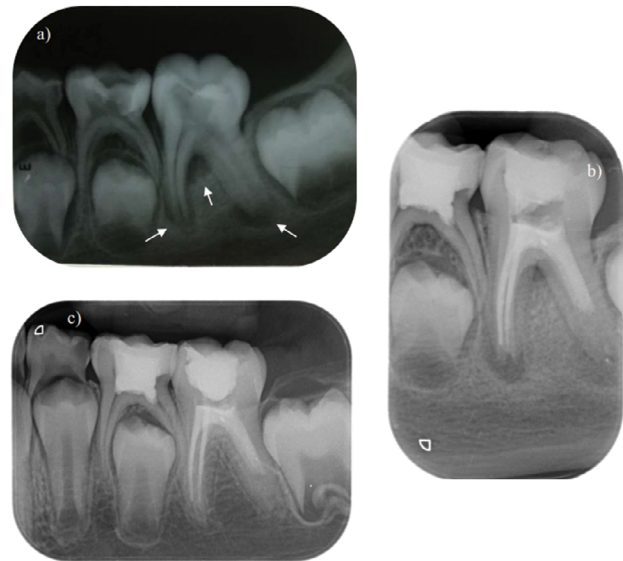


Figure 5. Healing of the periapical lesion without changes in the length of the root or closure of the apex. **a)** Initial X-ray with periapical lesions around both roots, as well as radiolucency in the interradiolar space (arrow); **b)** Follow-up after REP of the distal root and filling of the mesial canals; **c)** Follow-up after 24 months.

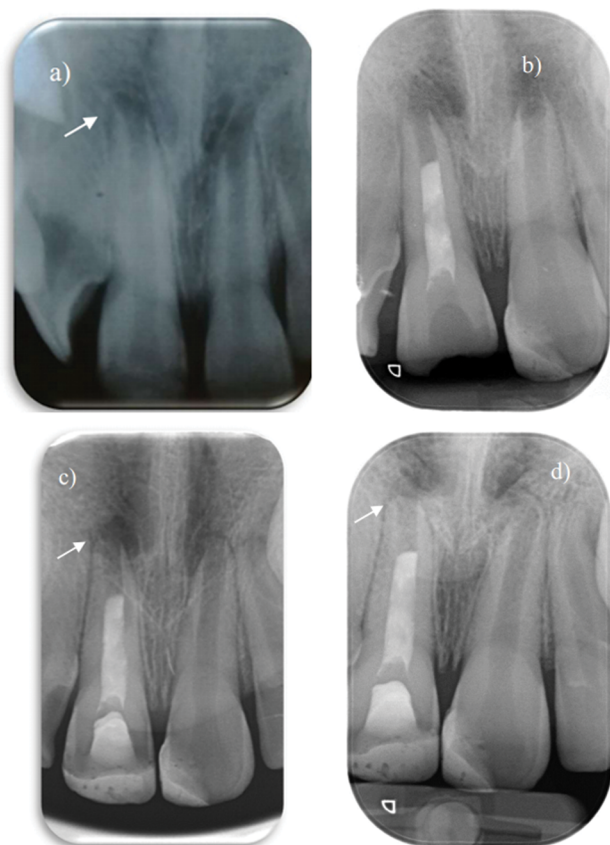


Figure 6. Lack of radiographic signs of healing process. **a)** Initial X-ray; **b)** Follow-up after revascularization; **c)** Follow-up after 6 months; **d)** Follow-up after 18 months.

- effective coronal sealing.

Three important factors have been identified: disinfection of the root canal, placement of a scaffold in the canal to guide the cell proliferation and differentiation, and hermetic sealing of the endodontic access.^[9]

In the present clinical study, 28 of 30 teeth achieved the primary and secondary goals of regenerative endodontics – radiographical and clinical healing of the lesion and increasing the thickness and/or length of the root walls (**Figs 2-5**). Radiographic thickening and elongation of the canal walls with root maturation should not be considered regeneration of the pulp-dentin complex without histological confirmation. If the primary goal of regenerative endodontics is achieved - complete disappearance of all clinical symptoms and healing of apical periodontitis, the lack of replacement of damaged tissue with histologically identical should not be considered a clinical failure.^[8,10]

The clinical success of regenerative endodontics is determined by the achievement of the following three goals^[11]: first and foremost - the disappearance of clinical symptoms and radiographic evidence of bone healing; secondary goal (desirable but not essential) - increasing the root walls thickness and/or length; tertiary goal - restoration of pulp vitality.^[12] While the first goal is common to all endodontic treatments, the second is valid only for permanent teeth with incomplete root development.

Chen et al. describe 5 possible types of response in immature permanent teeth treated with regenerative endodontics: type 1 - thickening of the root walls and continued root maturation; type 2 - no significant elongation of the root walls, the apex of the tooth is closed; type 3 - there is an elongation of the root walls, the apex of the tooth remains open; type 4 - there is significant calcification of the canal space; and type 5 - there is a formed hard-tissue barrier in the canal between the coronally placed plug of MTA and the root.^[13] In all of the 20 teeth examined, there were radiographic signs of healing and thickening of the root dentin. In our study, this was achieved in 93.3% of cases. The results obtained show that the degree of root maturation is variable.

The incidence of revascularization-related intracanal obliteration can reach 62.1% of cases and this condition is progressive over time.^[14] Obliteration of the root canal is usually a finding after acute dental trauma and it is more common in immature permanent teeth than in those with completely formed roots.^[15] This is a phenomenon in vital teeth, which is believed to be due to compromise of the vascular bundle leading to a change in its function. Regenerative endodontic therapy, in turn, is applied in teeth with necrotic pulp and aims to create a 'new' pulp-dentin complex.^[16] Root canal calcification as a result of REP is more common in cases with induced bleeding (69.6%) than in those without bleeding (33.4%). In addition, this obliteration occurs more often when calcium hydroxide is used (76.9%) than when antibiotic paste is used (46.2%). It means that this response is not only associated with calcium hydroxide, but is most likely a complex effect of a number of contributing factors.^[14] In all teeth treated in the present study, bleeding was provoked and triple antibiotic paste was used for medication. Revascularization-related intracanal calcification was observed in 13% of cases.

Two cases in the present study failed to achieve the primary goal of regenerative endodontic therapy - radiographic data for bone healing. The main cause of pulpal and periapical inflammation is bacterial invasion and colonization of the root canal system.^[17] In order to achieve regeneration, canal walls must be well disinfected, and the degree of necessary decontamination and disinfection of the root canal is even higher than in traditional endodontic therapy.^[18] In unsuccessful cases of regenerative endodontics, the long-term persistence of the periapical lesion, the cytotoxic effect of irrigants, the early stages of root development, and improper control of intracanal infection are considered to be the most important factors for the negative result.^[19,20] The greatest importance is given to persistent or reintroduced microorganisms.^[21] Bacteria inside the canal can be resistant to chemical and mechanical preparation and survive in isolated and hard-to-reach areas of the canal system.^[22,23] According to microbiological and histological observations, bacteria can survive despite the use of intracanal dressings.^[22,24] Similar to conventional endodontic therapy, the biofilm can remain in the canal system after disinfection without mechanical instrumentation during

a regenerative endodontic procedure. The high bacterial colonization of the canal walls and, consequently, the treatment failure are believed to be primarily caused by a lack of mechanical instrumentation, according to histological observations of failed revascularization cases. Most of the bacteria are located in the apical, not in the coronary part of the canal, forming a biofilm and penetrating the dentinal tubules.^[19] The biofilm microorganisms are firmly attached to the canal walls and their removal requires mechanical instrumentation in combination with the use of irrigants. Although mechanical instrumentation significantly reduces the number of microorganisms, it is usually not recommended for regenerative endodontic procedures.^[11,25] Disinfection in these cases should be achieved through the use of irrigation solutions and intracanal medication with minimal or no mechanical cleaning.^[8] Mechanical cleaning can weaken already thin root walls or remove remnants of vital tissue in the apical part of the canal.^[26] However, modern protocols for regenerative endodontics without instrumentation leave much doubt as to whether it is possible to achieve adequate disinfection of the root canals of infected immature permanent teeth. The inability to achieve this leads to treatment failure.^[19,27,28]

In the present clinical study, the changes made in the classical protocol affect the part with decontamination and disinfection of the canal space. The efforts are focused on finding a method for appropriate activation of the solutions so that they are effective against microorganisms, but without increasing their cytotoxicity to stem cells from apical papilla, as well as for removing the biofilm from the root canal walls with minimal loss of hard dental structures. The results obtained in the experimental conditions gave us the basis for clinical use of XP-Endo Finisher in the treatment of immature permanent teeth and necrotic pulp.^[29] The mechanical instrumentation with this instrument removes a minimal amount of infected dentin and shows the best results in reducing the amount of intracanal microorganisms, comparable to the proposed treatment protocol from American Association of Endodontists, but in a significantly shorter time.^[30]

CONCLUSIONS

The optimized clinical protocol for regenerative endodontic treatment of immature permanent teeth with necrotic pulp, which includes minimal mechanical instrumentation and irrigation with citric acid, allows the achievement of the primary and secondary goals of regenerative endodontics. The inclusion of mechanical instrumentation with appropriate files reduces the duration of the clinical protocol, which is useful in the dental treatment of children.

REFERENCES

- Nicoloso GF, Goldenfum GM, Pizzol T, et al. Pulp revascularization or apexification for the treatment of immature necrotic permanent teeth: systematic review and meta-analysis. *J Clin Pediatr Dent* 2019; 43(5):305–13.
- Rafter M. Apexification: a review. *Dent Traumatol* 2005;21(1):1–8.
- Guerrero F, Mendoza A, Ribas D, et al. Apexification: a systematic review. *J Conserv Dent* 2018; 21(5):462–5.
- Duggal M, Tong HJ, Al-Ansary M, et al. Interventions for the endodontic management of non-vital traumatised immature permanent anterior teeth in children and adolescents: a systematic review of the evidence and guidelines of the European Academy of Paediatric Dentistry. *Eur Arch Paediatr Dent* 2017; 18(3):139–51.
- Galler KM. Clinical procedures for revitalization: current knowledge and considerations. *Int Endod J* 2016; 49(10):926–36.
- Johnson BR. Endodontic access. *Gen Dent* 2009; 57(6):570–7; quiz 8-9, 95, 679.
- Hargreaves KM, Giesler T, Henry M, et al. Regeneration potential of the young permanent tooth: what does the future hold? *J Endod* 2008; 34(7 Suppl):S51–6.
- Law AS. Considerations for regeneration procedures. *J Endod* 2013; 39:44–6.
- Windley W, Teixeira F, Levin L, et al. Disinfection of immature teeth with a triple antibiotic paste. *J Endod* 2005; 31(6):439–43.
- Torabinejad M, Faras H. A clinical and histological report of a tooth with an open apex treated with regenerative endodontics using platelet-rich plasma. *J Endod* 2012; 38(6):864–8.
- American Association of Endodontists. AAE Clinical Considerations for a Regenerative Procedure [Internet]. Available from: https://www.aae.org/uploadedfiles/publications_and_research/research/current-regenerativeendodonticconsiderations.pdf.
- Geisler T. Clinical considerations for regenerative endodontic procedures. *Dent Clin North Am* 2012; 56(3):603–26.
- Chen MY, Chen KL, Chen CA, et al. Responses of immature permanent teeth with infected necrotic pulp tissue and apical periodontitis/abscess to revascularization procedures. *Int Endod J* 2012; 45(2):294–305.
- Song M, Cao Y, Shin SJ, et al. Revascularization-associated intracanal calcification: assessment of prevalence and contributing factors. *J Endod* 2017; 43(12):2025–33.
- Andreasen FM, Kahler B. Pulpal response after acute dental injury in the permanent dentition: clinical implications - a review. *J Endod* 2015; 41(3):299–308.
- Hameed MH, Gul M, Ghafoor R, et al. Management of immature necrotic permanent teeth with regenerative endodontic procedures - a review of literature. *J Pak Med Assoc* 2019; 69(10):1514–20.
- Kakehashi S, Stanley HR, Fitzgerald RJ. The effects of surgical exposures of dental pulps in germfree and conventional laboratory rats. *J South Calif Dent Assoc* 1966; 34(9):449–51.
- Fouad AF. Contemporary microbial and antimicrobial considerations in regenerative endodontic therapy. *J Endod* 2020; 46(9s):S105–14.
- Lin LM, Shimizu E, Gibbs JL, et al. Histologic and histobacteriologic observations of failed revascularization/revitalization therapy: a case report. *J Endod* 2014; 40(2):291–5.
- Almutairi W, Yassen GH, Aminoshariae A, et al. Regenerative endodontics: a systematic analysis of the failed cases. *J Endod* 2019;

- 45(5):567–77.
21. Nair PN, Henry S, Cano V, et al. Microbial status of apical root canal system of human mandibular first molars with primary apical periodontitis after 'one-visit' endodontic treatment. *Oral Surg Oral Med Oral Pathol Oral Radiol Endod* 2005; 99(2):231–52.
 22. Ricucci D, Siqueira Jr JF. Apical actinomycosis as a continuum of intraradicular and extraradicular infection: case report and critical review on its involvement with treatment failure. *J Endod* 2008; 34(9):1124–9.
 23. Yoo YJ, Perinpanayagam H, Choi Y, et al. Characterization of histopathology and microbiota in contemporary regenerative endodontic procedures: still coming up short. *J Endod* 2021; 47(8):1285–93.e1.
 24. Waltimo T, Trope M, Haapasalo M, et al. Clinical efficacy of treatment procedures in endodontic infection control and one year follow-up of periapical healing. *J Endod* 2005; 31(12):863–6.
 25. Bystrom A, Sundqvist G. Bacteriologic evaluation of the efficacy of mechanical root canal instrumentation in endodontic therapy. *Scand J Dent Res* 1981; 89(4):321–8.
 26. Iwaya S, Ikawa M, Kubota M. Revascularization of an immature permanent tooth with periradicular abscess after luxation. *Dent Traumatol* 2011; 27(1):55–8.
 27. Dhaimy S, Dhoun S, Amarir H, et al. Pulpo-periodontal regeneration: management of partial failure revascularization. *Case Rep Dent* 2017; 2017:8302039.
 28. Bukhari S, Kohli MR, Setzer F, et al. Outcome of revascularization procedure: a retrospective case series. *J Endod* 2016; 42(12):1752–9.
 29. Hristov K, Gateva N, Stanimirov P, et al. Comparative analysis of root dentin loss when using modern mechanical cleaning instruments in immature permanent teeth. *Folia Med (Plovdiv)* 2020; 62(2):352–7.
 30. Hristov K, Gateva N. Effectiveness of different root canal irrigation protocols in treatment of immature permanent teeth. *MedInform* 2019; 6(2):1043–52.

Регенеративное эндодонтическое лечение несформированных постоянных зубов после механической обработки с помощью XP-Endo Finisher

Красимир Христов¹, Лилия Дойчинова¹, Наталия Гатева¹

¹ Кафедра детской дентальной медицина, Факультет дентальной медицины, Медицинский университет – София, София, Болгария

Адрес для корреспонденции: Красимир Христов, Кафедра детской дентальной медицина, Факультет дентальной медицины, Медицинский университет – София, София, Болгария; E-mail: khristov87@gmail.com

Дата получения: 3 января 2022 ♦ Дата приемки: 18 февраля 2022 ♦ Дата публикации: 30 июня 2023

Образец цитирования: Hristov K, Doitchinova L, Gateva N. Regenerative endodontic treatment of immature permanent teeth after mechanical instrumentation with XP-Endo Finisher. Folia Med (Plovdiv) 2023;65(3):460-467. doi: 10.3897/folmed.65.e80063.

Резюме

Введение: Традиционное лечение несформированных постоянных зубов с некротизированной пульпой включает создание апикального барьера с использованием гидроксида кальция или МТА-пробки на длительный период времени. Новый терапевтический подход, называемый регенеративными эндодонтическими процедурами (REP), используется для продолжения развития корня.

Цель: Исследовать реакцию несформированных постоянных зубов и некротизированной пульпы на REP с использованием модифицированного клинического протокола, включающего минимальное механическое вмешательство и орошение 10% лимонной кислотой.

Материалы и методы: Пролечено 30 несформированных постоянных зубов с некротизированной пульпой у 28 пациентов в возрасте 7-14 лет по модифицированному протоколу регенеративной эндодонтии. Протокол включал механическую обработку корневого канала соответствующей иглой в течение 2 минут и орошение 10% лимонной кислотой.

Результаты: Стенки корней увеличились в толщину в 28 (93%) пролеченных случаях. В 16 (53%) случаях мы обнаружили рентгенологические признаки продолжающегося развития корня; у шести (20%) было утолщение стенок канала и закрытие апекса, но не удлинение; у четырёх (13%) была облитерация корневого канала; у двух (7%) произошло заживление периапикального поражения без изменения длины стенок корня или закрытия апекса; и только в двух случаях (7%) не было признаков заживления, но зубы оставались бессимптомными.

Заключение: Использование механического инструментария с соответствующими иглами в REP сокращает клинический протокол, что является преимуществом при лечении детских стоматологических проблем.

Ключевые слова

несформированные зубы, механическая обработка, регенеративная эндодонтия, ревитализация, XP-Endo Finisher
