

THE “MONSTER AORTA” AND HOW TO DEAL WITH IT

G. Manchev, S. Kazakov, A. Keltchev

Department of Cardiac Surgery, Acibadem City Clinic “Vitosha” Hospital – Sofia

АОРТА „ЧУДОВИЩЕ“ И КАК ДА СЕ СПРАВИМ С НЕЯ

Г. Манчев, С. Казаков, А. Келчев

Отделение по кардиохирургия, Аджикадем Сити Клиник УМБАЛ “Витоша” – София

Abstract.

Introduction: The term “monster aorta” is a non-formal colloquial expression of advanced aortic disease. Features of the monster aorta phenotype include large aneurysm (> 6 cm), multisegmented involvement, hostile atheroma, chronic dissection, redo surgery, and emergency conditions. Although the literature commonly refers to these cases as “complex aortic pathology”, we propose the descriptive term “Monster Aorta” to emphasize the extraordinary anatomical complexity and technical challenges associated with such procedures. These operations frequently require multi-segment aortic reconstruction and demand management by a dedicated high-volume surgical team experienced in advanced perfusion techniques and cerebral protection strategies. The phrase “monster aorta” appears only rarely in the literature and generally in an informal descriptive context rather than as a formally defined clinical entity, illustrating the use of the term as a descriptive characterization of extreme aortic pathology rather than an established diagnostic designation.

Objectives: The aim of the study is to establish the definition of monster aorta for clinical purposes and to offer best-practice recommendations. **Materials and Methods:** This is a single-center retrospective observational study of patients who underwent thoracic aortic surgery with monster aorta phenotype. Eight consecutive cases were described individually with respect to cannulation strategies, cerebral protection, frozen elephant trunk (FET) deployment, spinal cord protection, as well as various safeguards and pitfalls. Primary outcome measures were survival and neurologic complications. **Results:** No hospital mortality occurred and all patient were neurologically intact on discharge. All patients are alive to date. **Discussion and Conclusion:** This article demonstrates the strategies applied in the surgical treatment of monster aorta pathology in the Department of Cardiac Surgery, Acibadem City Clinic Vitosha Hospital. Based on the favorable postoperative results these surgical strategies seem to be effective and reproducible. The concept of monster aorta is useful in patient’s referral to high-volume centers specialized in thoracic aortic surgery.

Key words:

monster aorta, cannulation, cerebral protection, frozen elephant trunk

Address

Georgi Manchev, MD; e-mail: Georgi.Manchev@acibademcityclinic.bg; Assen Keltchev, MD, PhD;

for correspondence:

e-mail: assen.keltchev@gmail.com

Резюме.

Въведение: Понятието аорта „чудовище“ е неформален разговорен израз на напреднала аортна патология. Фенотипните белези на аортата чудовище са голяма аневризма (> 6 cm), мултисегментно засягане, агресивна атеросклероза, реоперация и спешни състояния. Въпреки че в научната литература тези случаи най-често се обозначават като „комплексна аортна патология“, ние предлагаме описателния термин „monster aorta“ (аорта чудовище), за да подчертаем изключителната анатомична сложност и техническите предизвикателства, свързани с подобни хирургични интервенции. Тези операции често изискват реконструкция на множество сегменти на аортата и предполагат лечение от високоспециализиран хирургичен екип с голям обем дейност, притежаващ опит в съвременните перфузионни техники и стратегиите за церебрална протекция. Изразът „monster aorta“ се среща изключително рядко в литературата и обикновено се използва в неформален, описателен контекст, а не като формално дефинирана клинична единица. Това илюстрира употребата на термина като описателна характеристика на екстремна аортна патология, а не като утвърдено диагностично обозначение. **Цел.** Целта на проучването е да затвърди дефиницията на аортата чудовище с клинични цели и да предложи препоръки за успешно поведение. **Материал и методи:** Това е едноцентрово ретроспективно наблюдателно изследване при пациенти, които са претърпели хирургична намеса на торакалната аорта във фенотипна аорта чудовище.

Осем индивидуални случая са описани поотделно по отношение на канюлационни стратегии, мозъчна протекция, имплантация на хибридна протеза тип frozen elephant trunk, протекция на гръбначния мозък, както и различни съвети за успешен изход. Основните пунктове за краен резултат са смъртност и неврологични усложнения. **Резултати:** Сред описаните пациенти няма болнична смъртност и всички са дехоспитализирани без неврологични усложнения. Всички пациенти са живи към настоящия момент. **Обсъждане и заключение:** Това проучване демонстрира стратегиите, които се използват при хирургичното лечение на аортата чудовище в Отделението по кардиохирургия на Аджибадем Сити Клиник УМБАЛ „Витоша“. Имайки предвид благоприятните резултати, тези техники изглеждат ефективни и възпроизводими. Понятието „аорта чудовище“ може да е полезно при насочването на такива пациенти към специализирани центрове с голям обем на дейност в торакалната аортна хирургия.

Ключови думи: аорта „чудовище“, канюлация, мозъчна протекция, frozen elephant trunk

Адрес д-р Георги Манчев, дм; e-mail: Georgi.Manchev@acibademcityclinic.bg; д-р Асен Келчев дм;

за кореспонденция: e-mail: assen.keltchev@gmail.com

INTRODUCTION

Extensive thoracic aortic disease in the form of aneurysm, dissection, and diffuse atherosclerosis presents significant challenges to the cardiothoracic surgeon. Such cases demand highest level of surgical planning and execution to achieve success and durable long-term outcome. Although the literature commonly refers to these cases as “complex aortic pathology”, we propose the descriptive term “Monster Aorta” to emphasize the extraordinary anatomical complexity and technical challenges associated with such procedures. These operations frequently require multi-segment aortic reconstruction and demand management by a dedicated high-volume surgical team experienced in advanced perfusion techniques and cerebral protection strategies. It is a non-formal colloquial term used to describe advanced aortic pathology such as extreme diameter, wide-spread calcification, tortuosity, hostile atheroma, dissection or a combination of the aforementioned. This anatomy could be aggravated in the setting of emergency, aortic root pathology, and presence of adhesions, bypass grafts, and prosthetic materials in redo settings.

An important feature of the monster aorta is the multi-segment character of the disease often necessitating staged repair. The conventional elephant trunk procedure introduced by Borst creates a proximal landing trunk during arch replacement to facilitate later reconstruction of the descending aorta [1]. The technique was further developed into the frozen elephant trunk procedure in which a stented vascular graft is deployed into the descending aorta during aortic arch replacement [2]. The stent graft enables distal stabilization of dissected or aneurysmal aorta with false lumen or peri-prosthetic thrombosis, and provides a secure landing zone for future endovascular repair of the descending aorta. The Vascular Domain of the European Association of Cardiothoracic Surgery (EACTS) established

indications and safety considerations for the implementation of FET [3].

Thoracic aortic surgery remains a high-risk undertaking in terms of neurological consequences. Stroke, transient neurological dysfunction and spinal cord injury are well recognized complications demanding tough precautions such as hypothermic circulatory arrest and antegrade cerebral perfusion. Stroke rates vary from 4.5% for ascending aortic aneurysm surgery to 12.3% in the setting of acute aortic dissection (AAD), and may reach more than 17% in arch surgery [4], [5]. Furthermore, the stented graft of FET requires careful sizing and distal deployment level to mitigate the risk of spinal cord ischemia [6]. The monster aorta phenotype adds to the overall risk of thoracic aortic surgery as it introduces anatomic traits which require complex operative planning to achieve satisfactory results.

OBJECTIVE

The aim of this article is to refine and establish the definition of “monster aorta” for clinical purposes and comparing outcomes of scientific studies on the basis of the experience in the Department of Cardiac Surgery, Acibadem City Clinic Vitosha Hospital. Best-practice recommendations for surgical approaches will be described.

METHODS

Design

This is a retrospective, single-center observational study of patients who underwent open surgical treatment of thoracic aortic disease defined as monster aorta at Acibadem City Clinic Vitosha Hospital, Sofia, Bulgaria, between 1 September 2025 and 31 December 2025.

Definition of monster aorta

Certain features of the aortic disease must be present in order to qualify for monster aorta. Multisegment thoracic aortic disease involving at least two contiguous segments must be present making isolated ascending or descending repair insufficient to qualify. Also, there are additional factors that increase the complexity of the case and modify the surgical strategy. Mega-aortic syndrome (MAS) is used to describe aneurysmal dilatation of more than 6 cm involving multiple aortic segments or the entire aorta [7]. Severe atherosclerosis (“shaggy aorta”) or heavy calcification heighten the risk of intraoperative embolic phenomena, complicate the creation of secure suture lines, and increase mortality [8]. Acute aortic dissection (AAD) bears an inherent risk of aortic rupture and frequently presents with organ malperfusion. Redo cases offer special challenges to the surgeon who must deal with dense pericardial adhesions, patent bypass grafts, previously implanted vascular or valve prostheses. Aortic pathology is often accompanied by aortic root or valve pathology requiring whole root replacement or a valve-sparing strategy. The presence of urgency in the condition due to hemodynamic instability, tamponade, contained aortic rupture, or organ malperfusion adds to the elevated perioperative risk.

Inclusion and exclusion criteria

Adult patients (age > 18 years) meeting the above definition of monster aorta who underwent open surgical repair are included in the study. Purely endovascular procedures or isolated ascending aortic replacement in patients not meeting the monster aorta definition are excluded.

Surgical strategy

The surgical objective is complete correction of thoracic aortic pathology including any aortic root/valve disease during a single operation. In cases of aneurysmal or chronically dissected descending aorta a FET was implanted to ensure antegrade disease control. The stented vascular graft provides exclusion of aneurysms, true-lumen expansion in aortic dissection, and serves as a landing zone for future downstream endovascular interventions.

Cannulation for cardiopulmonary bypass (CPB). Monster aorta cases nearly always necessitate peripheral arterial cannulation. This is due to the risk of aortic injury during sternal reentry, rupture of dissected aorta, dislodgment of embolic material during aortic manipulation. Our preference for peripheral arterial cannulation is the axillary artery. It is close to the surgical field and is rarely affected by dissection or atherosclerosis. Axillary cannulation provides antegrade inflow and facilitates subsequent antegrade cerebral perfusion

during circulatory arrest. The right-sided artery is more often used and is accessed through the deltopectoral groove. Cannulation is direct through a purse-string suture via the Seldinger technique with a 17 Fr arterial cannula, which can provide up to 5L/min blood flow. Side-graft technique was deemed unnecessary in our practice. The groin is always prepared for rapid femoral cannulation in case of emergency. The venous outflow is typically central via the right atrium through a single dual-stage cannula in a redo setting the femoral vein cannulation is preferred strategy.

Cerebral protection. Monster aorta cases usually require a period of suspended circulation in order to deal with the aortic arch. Protection of the central nervous system is paramount. Our preference for brain protection during circulatory arrest is moderate hypothermia at 25°C complemented by unilateral brain perfusion via the axillary artery cannula if the DHCA time is <30 min and cannulation of the three cerebral vessels in complex cases or if NIRS monitoring shows abnormal difference. Then a second balloon-tipped cannula coming off a side arm of the arterial cannula is inserted into the left carotid artery to achieve bilateral cerebral perfusion. The left subclavian artery is occluded to prevent steal phenomenon or perfused as well. The brain is perfused at the arrest temperature with 10 ml/kg/min flow rate. Monitoring of cerebral oxygen saturation by near-infrared spectroscopy (NIRS) is always present.

FET deployment. The distal anastomosis of the collar around the stent graft is usually done to zone 2 or 3 of the aortic arch. The debranched arch vessels are then reattached to the side branches of the hybrid prosthesis. In cases of deep left subclavian artery, it may be oversewn and perfusion restored through a subclavian-carotid bypass. Another option is maneuvering a side branch of the hybrid graft from the surgical field into the left pleura and through the first intercostal space out of the thorax where it is connected to the subclavian artery. In aneurysm cases the stent graft is oversized to 10-20% of actual aortic size at the respective segment. In dissection cases oversizing is minimal to avoid new intimal damage and also ensuring complete seal of the false lumen. The length of the stent graft is chosen based on the anticipated zone of the distal suture line and patient anatomy so that its distal end stays superior to the origin of the artery of Adamkiewicz (usually T9-T12 level).

Spinal cord protection. Protection of the spinal cord against ischemia is no less important than brain protection. Cerebral perfusion pressure and flow during hypothermic circulatory arrest affect spinal cord perfusion through collateral blood supply. Lower body ischemia can be limited by immediate reperfusion following graft deployment and completion of the distal anastomosis which is facilitated by

cannulation of a side branch of the prosthesis. Excessive length of the stent graft is avoided so that the origin of the great anterior radiculomedullary artery (Adamkiewicz) stays unobstructed as stated above. Our strategy for extensive aortic pathology is based on staged repair with future endovascular completion rather than single-setting coverage of the entire descending thoracic aorta.

Outcome measures

The primary endpoints were operative mortality defined as in-hospital or 30-day mortality and neurologic injury. Permanent neurologic dysfunction (stroke) is defined as a new persistent focal or global neurologic deficit lasting more than 24 hours with residual symptoms at discharge or leading to patient's death. Stroke is diagnosed clinically and must have a radiologic correlate. Spinal cord ischemia (SCI) is a new paraplegia/paraparesis postoperatively, which is transient or permanent. The secondary endpoints comprise any complications stemming from the operative procedure. Renal failure is defined as acute renal dysfunction requiring renal replacement therapy. Imperfect correction necessitating additional endovascular intervention is also considered. Other measures of outcome include reexploration for bleeding, intensive care unit (ICU) length of stay and duration of mechanical ventilation, signs of heart failure with prolonged inotropic support (> 72 hours), sepsis defined as positive blood cultures along with clinical and laboratory findings suggestive of sepsis, overall hospital stay.

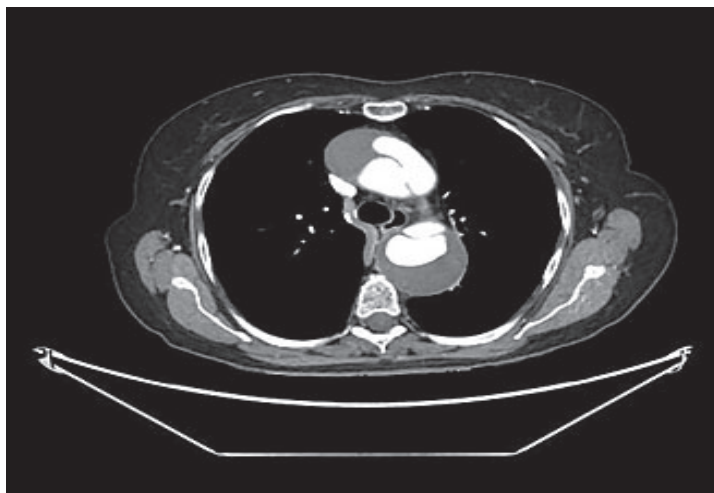

Fig. 1. Wide entry in the aortic arch

MATERIALS

The study encompasses a heterogeneous population of consecutive patients bound together by the monster aorta pathology. The clinical cases below portray how certain situations could be dealt with.

Case #1. This was a patient with chronic aortic dissection type I with intact proximal portion of the ascending aorta and a wide entry in the arch (Fig.1). The aorta was aneurysmal in its ascending and arch portions. Both iliac arteries were involved with dissection and intimal exit in the right external iliac artery. Also, the patient presented with arteria lusoria (Fig.2). In order to secure the right subclavian artery a prior subclavian-to-carotid bypass was performed the day before (Fig. 3). Arterial return was accomplished by splitting the arterial line and simultaneously perfusing the subclavian-carotid bypass prosthesis and the intact portion of the ascending aorta so as to avoid brain hyperflow. During aortic cross-clamping further surgical dissection was done of the aortic arch in preparation for debranching. Antegrade brain perfusion was established by the main arterial cannula in the right subclavian bypass graft and a second balloon-tipped cannula inserted into the left carotid artery. The left subclavian and lusorian arteries were transected and oversewn by an EndoGraft device. The distal anastomosis was done in zone 2 with complete exclusion of the intimal entry. Guidewire that had been previously inserted in the left femoral artery was used for stent graft deployment. Finally, a branch of the hybrid prosthesis was routed through the first intercostal space on the left side to be anastomosed to the subclavian artery. Figure 4 and 5 demonstrate the anatomic result on follow-up CT.

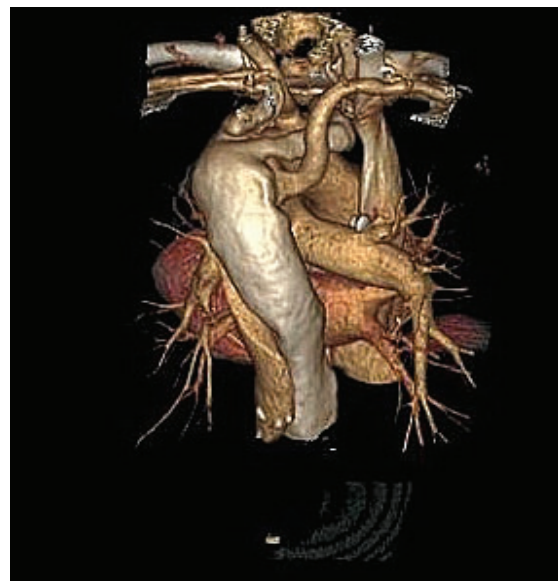

Fig. 2. Lusorian artery coming off the true lumen (posterior view)

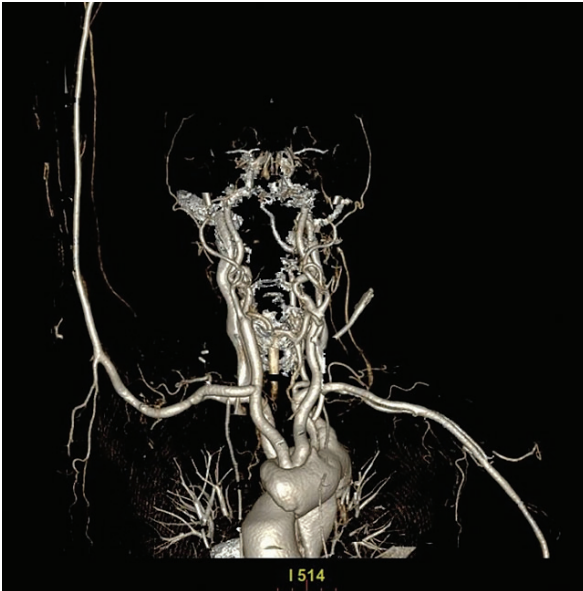


Fig. 3. Right subclavian-carotid bypass

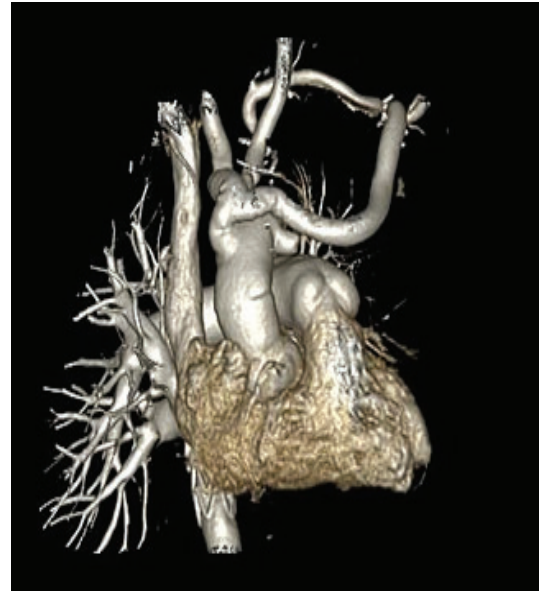

Fig. 4. Anterior reconstruction view on follow-up CT scan

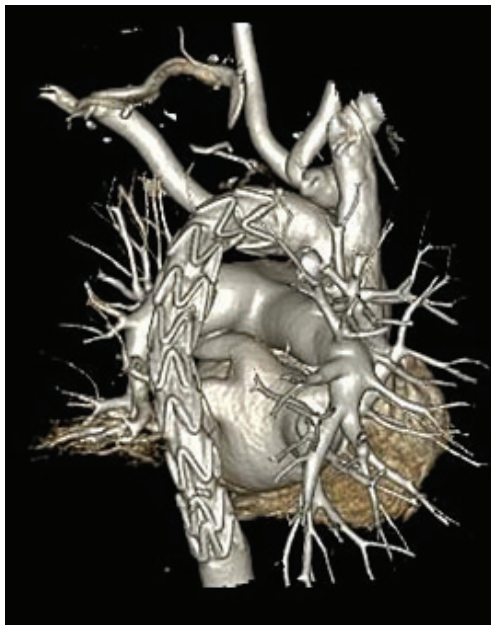


Fig. 5. Posterior reconstruction view on follow-up CT scan

Case #2. This was a patient who had suffered acute type A aortic dissection and had undergone aortic valve and ascending aortic replacement 7 years ago. He presented with large, dissected root aneurysm (> 80 mm) as well as arch and proximal descending thoracic aneurysms with persistent dissection down to the level of the aortic bifurcation (Fig. 6 and Fig. 7). The right axillary artery had already been utilized during the index surgery. Thus, the right common carotid artery was exposed, 8 mm vascular prostheses was sutured, and the latter cannulated for arterial return. In addition, the right femoral vessels were exposed and cannulat-

ed. The aortic graft was adherent to the undersurface of the sternum (Fig. 8). Due to the high risk of injury CPB was initiated and the aorta was dissected off the sternum via an endoscopic right minithoracotomy approach. Then the sternum was safely opened. Pericardial adhesions were freed by a ultrasonic (Harmonic) scalpel. In this patient the distal anastomosis of the FET prosthesis was done at zone 0 due to size discrepancy at the proximal descending aorta (> 80 mm with a small perfused true lumen). The arch branches were reimplemented to the arms of the hybrid graft. Figures 9 and 10 show the anatomic reconstruction on follow-up CT three months later.

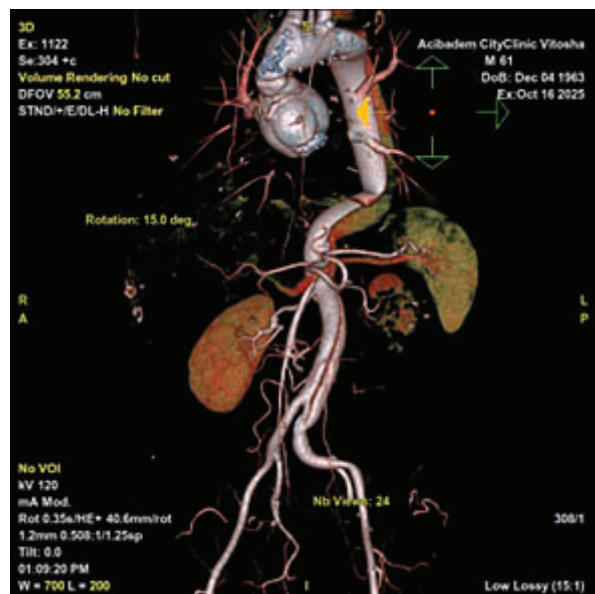


Fig. 6. A large, dissected root aneurysm

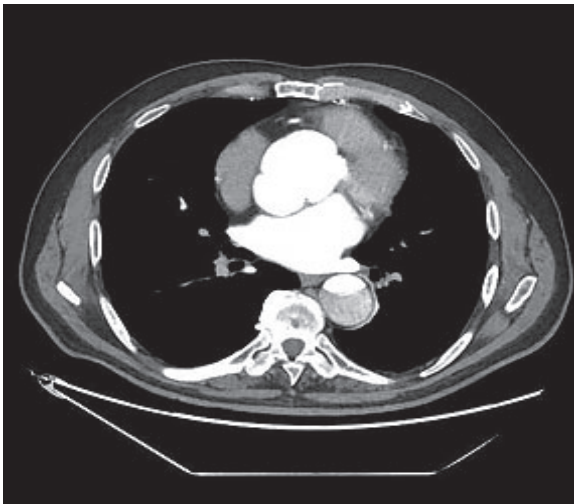


Fig. 7. Persistent dissection with patent false lumen

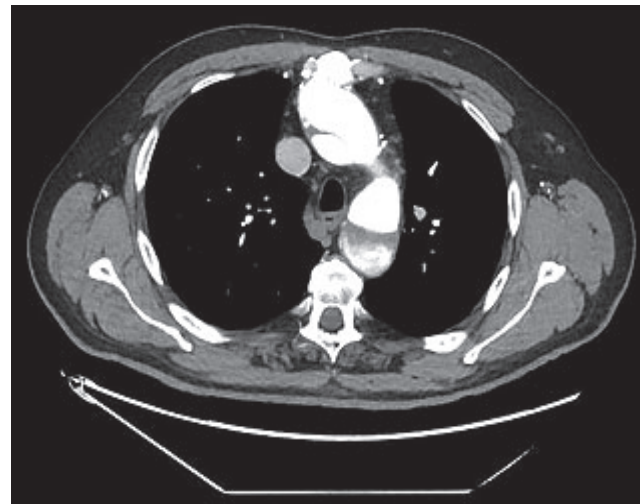


Fig. 8. Tight adherence of the aorta to the sternum

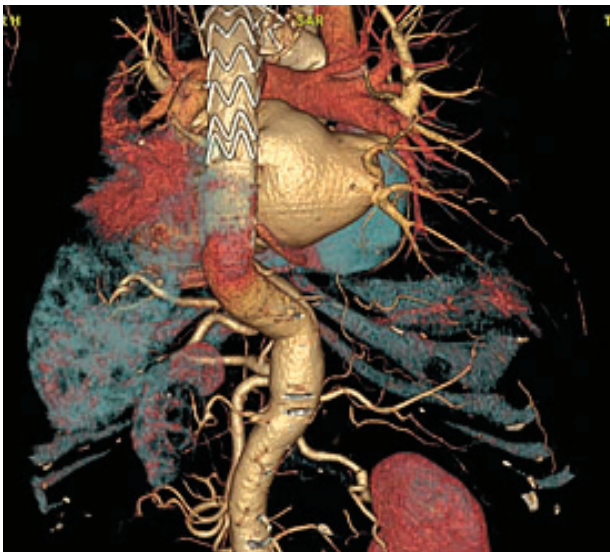

Fig. 9. Posterior view of the stent-graft in the descending aorta

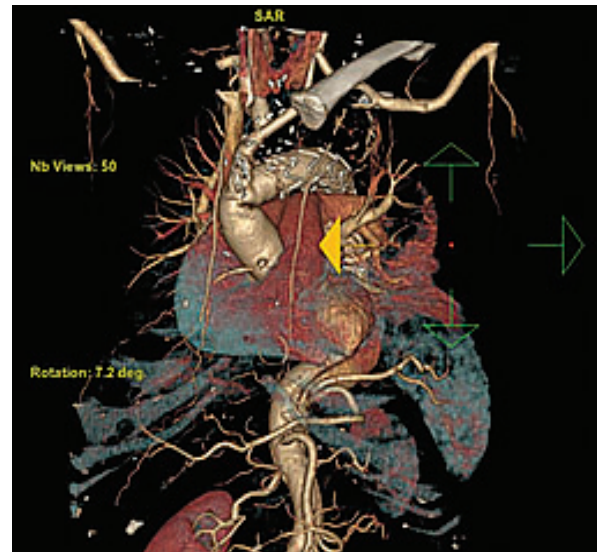


Fig. 10. Anterior view of the reconstruction

Case #3. This was a patient who presents with thoracic aortic aneurysm starting from the sinotubular junction to the mid descending aorta following isolated aortic valve replacement due to bicuspid aortic valve stenosis (Fig. 11). As there was no close contact between the sternum and heart structures re sternotomy was straightforward. Cardiopulmonary bypass was initiated via the axillary artery and femoral vein. Bilateral antegrade cerebral perfusion was initiated during circulatory arrest. A FET was implanted as the distal aortic anastomosis was done at zone 2. Fig. 12 demonstrates correction of the aneurysm on follow-up CT scan.

Case #4. This patient presented with a giant degenerative aneurysm of the ascending aorta up to the mid-arch measuring > 8 cm with aggressive mobile ath-

eromas inside (Fig. 13 and Fig. 14). CPB was initiated by the right axillary artery and right atrium. Due to high embolic risk the patient was cooled to 25 degrees and deep hypothermic circulatory arrest was started with unilateral cerebral perfusion via the right axillary artery. Then the aorta was opened and heart protected. FET prosthesis was implanted with the distal aortic anastomosis done in zone 2. The left subclavian artery had been pushed backward by the large aneurysm and had to be extended by a vascular prosthesis. Fig. 15 shows the stent-graft reaching the mid-descending aorta on follow-up.

Case #5. This was a 29-year-old patient who has undergone aortic valve reimplantation procedure and now presents with high-grade aortic regurgitation and an extensive periaortic hematoma with clear commu-

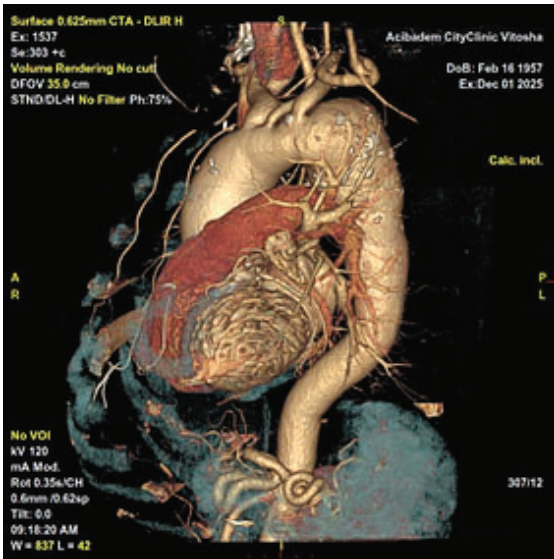


Fig. 11. Thoracic aortic "monster"

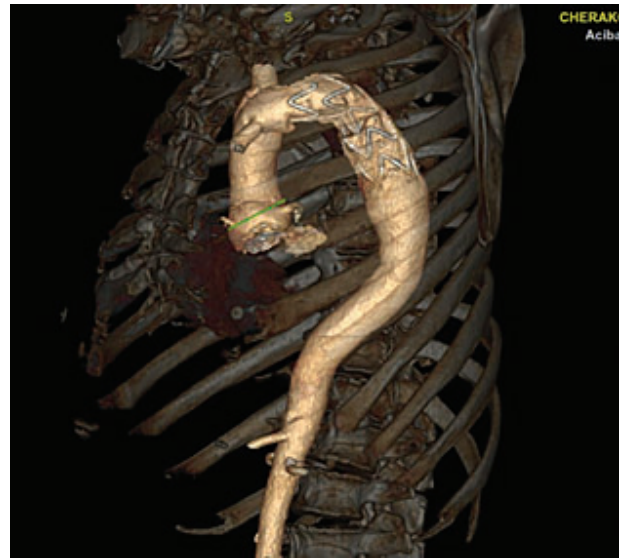

Fig. 12. The stent-graft stabilizing the thoracic "monster"

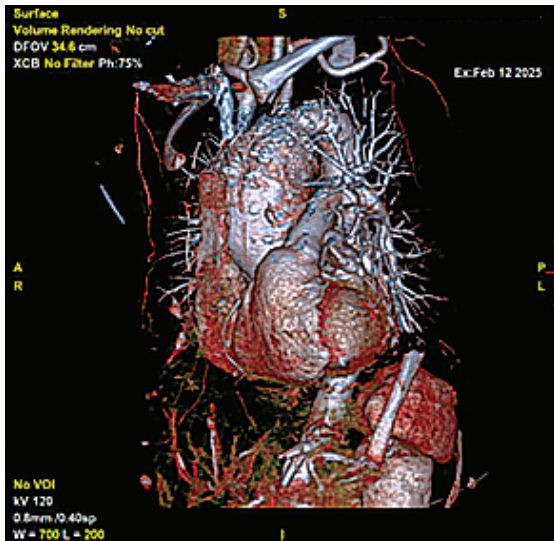

Fig. 13. A large degenerative ascending aortic and arch aneurysm

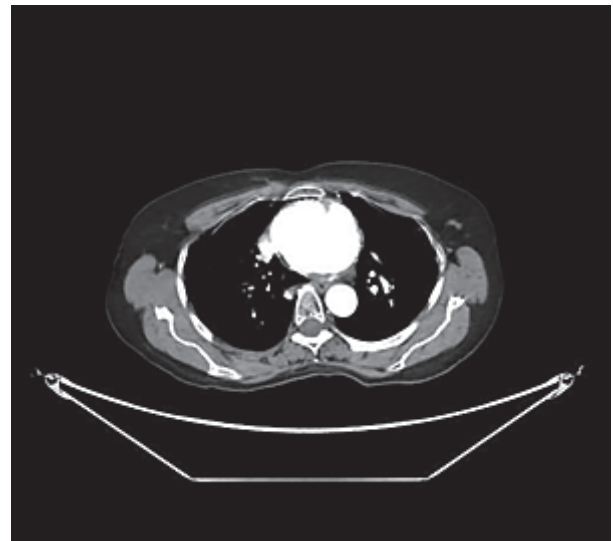


Fig. 14. Mobile atheromas inside

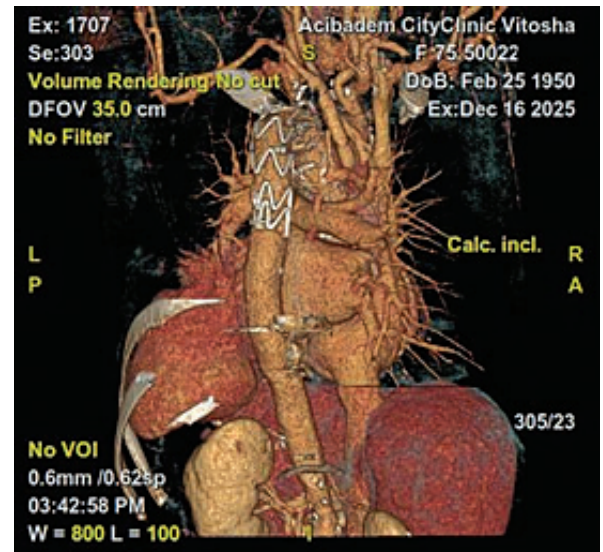


Fig. 15. The stent-graft in the descending aorta on a follow-up CT scan

nication with the left ventricle on computed tomography (CT) scanning (Fig. 16 and Fig. 17). As the risk of entering the hematoma during pericardial dissection with subsequent exsanguination was real, the patient was placed on peripheral cardiopulmonary bypass and cooling was initiated to 25°C target temperature. Following sternotomy, extreme caution was exerted during dissection of the distal aorta to free space for the aortic cross-clamp and prepare the arch vessels in case circulatory arrest is needed. Dissection of the right-sided pericardium was done to place a vent through the pulmonary vein. As the target temperature was reached the aorta was cross-clamped and the hematoma was safely opened along with the aortic prosthesis. Then the proximal repair was completed.

Case #6. This patient presented with an acute type I aortic dissection following coronary artery bypass grafting (CABG) surgery 10 years ago (Fig. 18). All grafts were fully patent and had to be spared inasmuch as the left main coronary artery was totally occluded. The patient was prepared for peripheral bypass and re sternotomy performed. Near-complete dissection of the pericardium was done before CPB was initiated. Before the aortic cross-clamp a balloon catheter placed in the LIMA graft just prior to operation in the cathlab was inflated in order to optimize myocardial protection. At 25°C the circulation was stopped, the aorta opened and selective unilateral brain perfusion contemplated. Then repair procedures were performed with reimplantation of the venous grafts into the aortic prosthesis (Fig. 19).

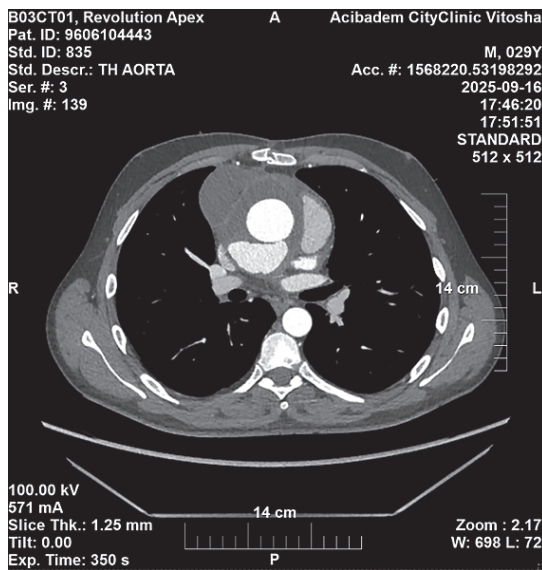


Fig. 16. Periaortic hematoma is actively enhanced by the contrast posteriorly

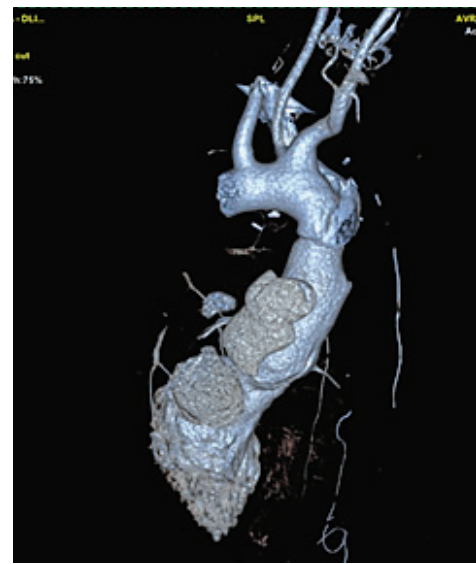

Fig. 17. The hematoma has a narrow communication with the left ventricle beneath the aortic valve

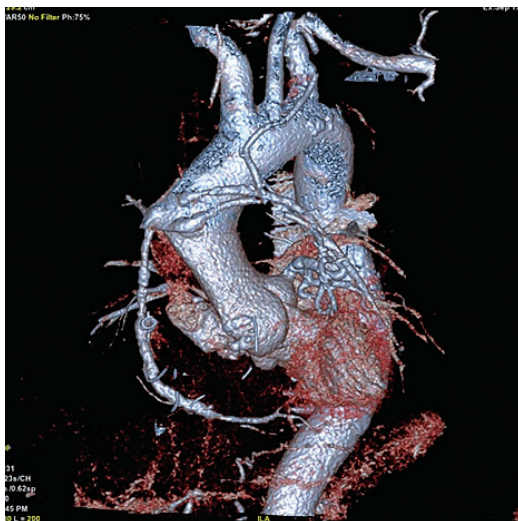


Fig. 18. Ascending aortic dissection with patent venous grafts

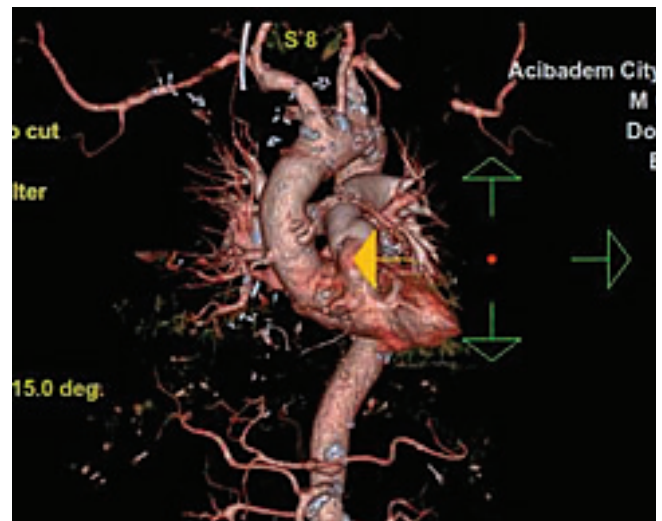


Fig. 19. CT reconstruction on follow-up

Case #7. This patient was similar to the previous case in that he presented with type II AAD following CABG surgery several years ago (Fig. 20). An important difference was the close proximity of the dissected aorta and bypass grafts to the sternal plate which necessitated initiation of peripheral CPB prior to sternotomy. The other strategies with regard to myocardial and cerebral protection were similar to the aforementioned case. An important decision had to be made about the left main coronary artery which although patent and stenosed was severely injured by the dissection. It could not be reconstructed so it was suture ligated. No additional myocardial injury was sustained postoperatively.

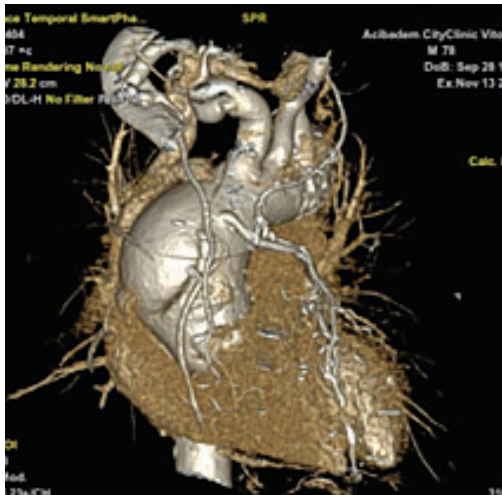

Fig. 20. Dissection flap and patent grafts seen in the ascending aorta

Case #8. This patient presented with contained rupture of the ascending aorta (Fig. 21). He underwent aortic valve replacement 5 years ago due to bicuspid aortic valve regurgitation. However, his dilated aorta had not been addressed then. Peripheral femoro-femoral bypass was started prior to sternotomy. The patient was actively cooled during pericardial dissection. A place for the cross-clamp was prepared and the hematoma left undisturbed. Following cross-clamp the aorta was opened, hematoma cleared, and Bentall procedure performed. The left coronary artery had to be extended with a vein graft to reach the neoroot.

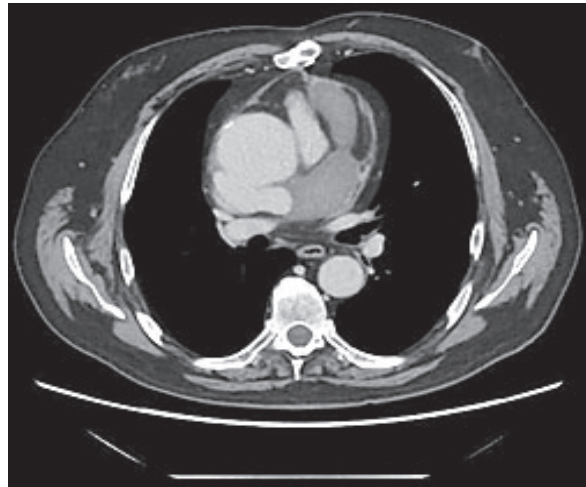


Fig. 21. Contained rupture of the posterior ascending aorta extending around the pulmonary trunk

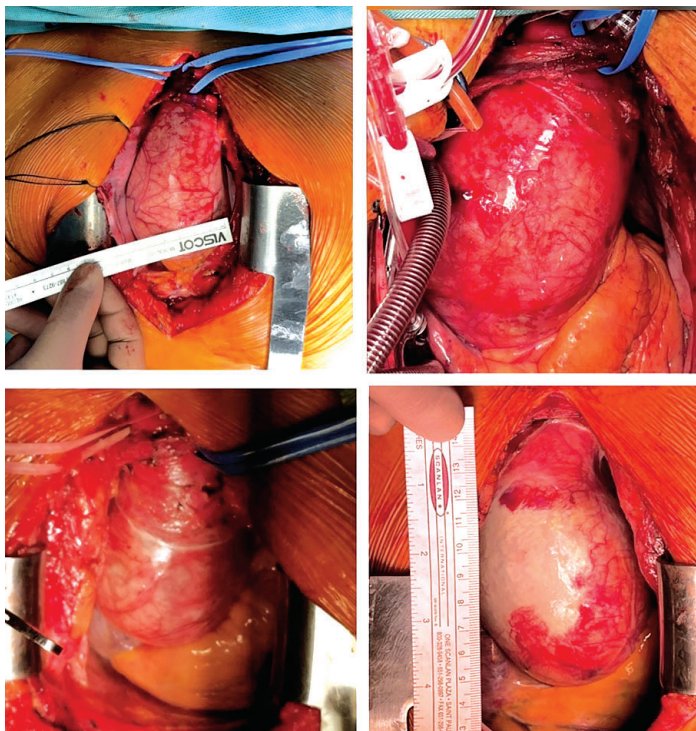


Fig. 22. A collage of large ascending aortic aneurysms

The following images are intraoperative photographs of monster aorta cases which visualize how large a diseased aorta could be, virtually occupying most of the operative field.

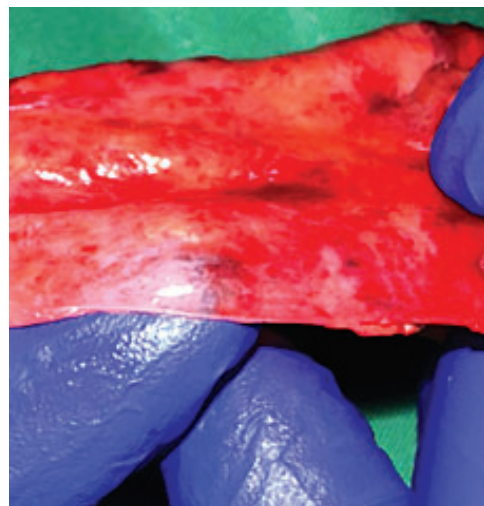


Fig. 23. The aortic wall is so thinned out as the glove could be seen through it

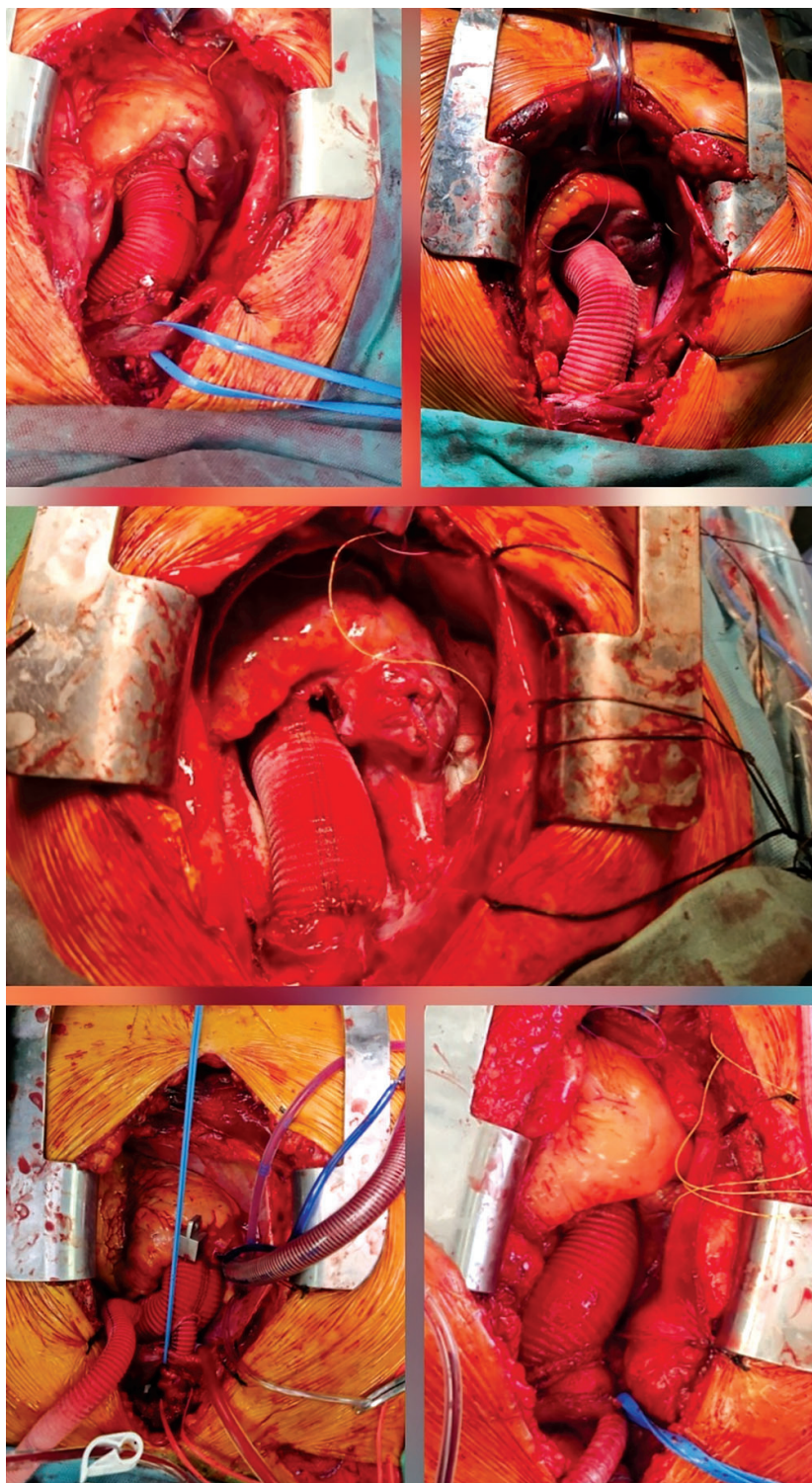


Fig. 24. A collage of photographs after surgical replacement of a monster aorta

RESULTS

All patients were discharged from the hospital. The hospital stay ranged from 7 to 25 days. ICU stay ranged from 1 to 15 days. Two patients required prolonged mechanical ventilation (> 72 hours). Two patients developed oliguric renal failure necessitating

renal replacement therapy. Two patients developed complete atrioventricular block and had a permanent pacemaker implanted. One patient needed inotropic support longer than 72 hours. No patient required mechanical circulatory support (IABP/ECMO). One patient developed neurologic symptoms in the early postoperative period (nyctagmus, clonic seizures, Babinski sign) with small ischemic areas in the cerebellum on CT. Her symptoms, however, underwent complete resolution within 4 days. No patient suffered spinal cord injury. Despite the prolonged operation no patient underwent reexploration for bleeding. There were no sternal wound complications on follow-up. No brachial plexus injury was noted in any patient with axillary cannulation.

DISCUSSION

The term “monster aorta” is a non-formal term describing extensive thoracic aortic disease often requiring advanced aortic surgery. From a morphological point of view the monster aorta encompasses one or more of the following features – significant dilatation exceeding surgical thresholds often more than 6 cm in more than one segment, chronic aortic dissection with persistently patent false lumen, extensive atherosclerotic degeneration of the aortic wall, impaired true lumen perfusion with potential end-organ ischemia, contained aortic rupture. Additional conditions that contribute to the complexity of these cases are previous cardiac or aortic surgery, aortic valve and/or root pathology. The monster aorta phenotype usually necessitates at least two-segment repair and in some cases a staged or hybrid therapeutic strategy.

The FET is indispensable in certain patient anatomy to minimize the operative risk and afford a second-stage endovascular repair.

The practical usefulness of the term “monster aorta” is that it provides a concept which implies disease severity, anatomical complexity and the consequent technical challenges as well as the increased patient risk. This underscores the importance of treatment of such disease entities in high-volume centers with expertise in open, hybrid, and endovascular aortic inter-

ventions with advanced cerebral and organ-protection strategies [9].

This article shares our experience with several monster aorta cases. Our prime purpose was to demonstrate the surgical strategies we use in these complex patients which we believe lead to optimal postoperative results. First of all, the choice of cannulation site may have a significant impact on outcome. Recent studies confirm that there is no difference between central and axillary cannulation in patient outcomes during aortic arch surgery [10], [11]. However, our preference to peripheral cannulation is based on the no-touch concept of the monster aorta since there is a high risk of embolization or rupture on when cannulating such aortas [12]. We prefer the axillary artery as it may easily be converted from systemic return to selective brain perfusion during circulatory arrest as reported by other groups [13]. As described previously it is cannulated directly via the Seldinger technique through a limited subclavicular incision. Direct cannulation of the axillary artery is described elsewhere [14]. Femoral cannulation is also used [15] when brain perfusion is not anticipated or as a complementary arterial return. However, should brain perfusion become necessary, it may be achieved by transostial cannulation of the arch vessels with balloon-tipped cannulas under direct vision which has been described by Kazui [16]. Venous drainage is peripheral via the femoral vein when CPB is to be started before sternotomy in some redo cases. Otherwise, it is often central via the right atrium. A large metaanalysis showed that peripheral cannulation in thoracic aortic surgery does not lower the risk of neurologic complications [17]. However, we assume that cannulation of the axillary artery provides a safe alternative in grossly diseased aorta and facilitates cerebral perfusion during circulatory arrest. Another practice in redo cases, especially redo aortic surgery is the usage of ultrasonic scalpel. There is evidence that it lowers the incidence of cardiac injuries, major arrhythmias, and need for transfusions [18].

Cases #1 and #2 were performed with dual arterial return. Some studies suggest that double arterial cannulation increases the risk of stroke in AAD type A [19]. However, these cases were specific in that there was a risk of brain hyperflow which is why a second inflow was included.

Circulatory arrest is established at 25° C as a rule in our practice to have a margin of safety if unpredicted events occur during arch reconstruction. There are groups who describe hemiarch and even total arch replacement under mild (28-30° C) systemic hypothermia [20]. Other groups report inferior outcomes of mild hypothermia in total arch replacement (TAR) [21]. Most probably, the level of hypothermia should be tailored to the anticipated duration

of circulatory arrest. As it was mentioned, antegrade cerebral perfusion is a must during circulatory arrest to limit the amount of brain injury [13]. There is a lot of evidence that unilateral cerebral perfusion leads to similar postoperative results as bilateral perfusion [22]. Nevertheless, our group always favors bilateral brain perfusion whenever possible during arch reconstruction. In all cases the non-perfused arch branches must be occluded by a tourniquet, a clamp, or a Fogarty catheter to avoid excessive back-bleed and steal phenomenon.

In case #2 we used the right carotid artery for arterial return. The right carotid artery is an infrequent choice for cannulation but presents certain advantages over the other sites [23]. It was chosen in this particular case because of the prior use of the right axillary artery. Another specific was the tight adherence of the aortic graft to the sternum. The video-guided transthoracic approach to free the aorta from the sternal body was successful in lessening the risk injury on subsequent sternal reentry. Thus, the cardiothoracic surgeon needs a wide and flexible surgical armamentarium to solve such elaborate cases.

Transostial cannulation of the arch vessel is an easy and effective technique to achieve cerebral perfusion during circulatory arrest. However, intimal injury and dislodgment of atheroembolic material have been described as causes of brain injury with this technique [24]. Case #4 had severe grade V atheromas in her ascending aorta and arch which precluded transostial cannulation of the innominate and carotid arteries. She had right-sided cerebral perfusion only which proved to be effective.

Cases #5 and #8 had an acute periaortic hematomas contained by adhesions of prior heart surgery. The points of importance are to be stressed. Initiation of peripheral CPB prior to sternal reentry, extreme caution during dissection of adhesions with the use of ultrasonic scalpel, and thorough understanding of the CT anatomy of the lesion.

Cases #6 and #7 demonstrate a technique which we successfully apply during redo procedures in the setting of prior CABG. The patient is transported to the cathlab where a balloon catheter is positioned into the LIMA graft. The balloon is expanded to predefined pressure to fully occlude the LIMA after the aorta is cross-clamped and cardioplegia administered. This technique obviates the need to dissect and unravel the graft which could lead to its injury. This technique has been reported by other groups [25].

Case #3 and #8 had both had an isolated aortic valve replacement of their bicuspid aortic valve several years earlier and now presented with aortic aneurysm/dissection. This underscores the importance of always considering replacement of the ascending aorta in the

setting of bicuspid aortic valve surgery especially when it reaches 45 mm in diameter along with other factors [26].

In two patients with total arch replacement the left innominate vein was transected and ligated to enhance exposure. No consequences were noted except mild and reversible edema of the left upper limb. Ligation of the left innominate vein is safe in selected patients with no long-term sequelae [27].

CONCLUSION

The monster aorta phenotype has certain high-risk features such as extreme aneurysm in several aortic segments, chronic dissection, severe atherosclerosis, which may be associated with redo surgery, proximal aortic or aortic valve disease, or emergency conditions as contained aortic rupture. The cardiothoracic surgeon needs to be highly flexible with a wide set of technical tools and skill to deal with these patients. They are best treated in a multidisciplinary environment in a high-volume center to ensure the highest chance of uneventful patient survival. Thus, the non-formal entity “monster aorta” may be useful in-patient referral and comparison between centers.

No conflict of interest was declared

References

1. Borst HG, Walterbusch G, Schaps D. Extensive aortic replacement using ‘elephant trunk’ prosthesis. *Thorac. Cardiovasc. Surg.*, 1983, 31(1):37-40.
2. Karck M, Chavan A, Hagl C, et al. The frozen elephant trunk technique: A new treatment for thoracic aortic aneurysms. *J. Thorac. Cardiovasc. Surg.*, 2003, 125(6):1550-1553.
3. Shrestha M, et al. Current status and recommendations for use of the frozen elephant trunk technique: a position paper by the Vascular Domain of EACTS. *Eur. J. Cardiothorac. Surg.*, 2015, 47(5):759-769.
4. Zaaqoq AM, et al. Risk Factors for Stroke Development After Thoracic Aortic Surgery. *J. Cardiothorac. Vasc. Anesth.*, 2023, 37(12):2524-2530.
5. Cazavet A, et al. Aortic arch aneurysm: short- and mid-term results comparing open arch surgery and the hybrid procedure. *Eur. J. Cardiothorac. Surg.*, 2016, 49(1):134-140.
6. Murana G, Campanini F, Fiaschini C, et al. Spinal cord injury after frozen elephant trunk procedures – prevention and management. *Ann. Cardiothorac. Surg.*, 2023, 12(5):500.
7. Wu WC, Mitchell CA, Linklater D. Mega aorta syndrome: A case of thoracic and abdominal aortic aneurysm. *Am. J. Emerg. Med.*, 2010, 28(6):747.e1-747.e3.
8. Velarde-Acosta K, et al. Shaggy aorta: ideal substrate for disaster. Updated review. *Arch. Peru. Cardiol. Cir. Cardiovasc.*, 2024, 5(3):143.
9. Sawang M, et al. The Relationship Between Aortic Aneurysm Surgery Volume and Peri-Operative Mortality in Australia. *Eur. J. Vasc. Endovasc. Surg.*, 2019, 57(4):510-519.
10. Tel Ustunisik C, et al. Aortic versus axillary artery cannulation for hemiarch replacement: single-centre real-world experience. *BMC Cardiovasc. Disord.*, 2024, 24(1).
11. Chung MM, et al. Central aortic versus axillary artery cannulation for aortic arch surgery. *JTCVS Open*, 2023, 14:14-25.
12. Fukuda I, Daitoku K, Minakawa M, et al. Shaggy and calcified aorta: surgical implications. *Gen. Thorac. Cardiovasc. Surg.*, 2013, 61(6):301-313.
13. Strauch JT, Böhme Y, Franke UFW, et al. Selective cerebral perfusion via right axillary artery direct cannulation for aortic arch surgery. *Thorac. Cardiovasc. Surg.*, 2005, 53(6):334-340.
14. Misfeld M, Bakhtiary F. Cannulation in aortic surgery: subclavian and axillary cannulation. *Multimed. Man. Cardiothorac. Surg.*, 2015, 2015.
15. Harrer M, et al. Aortic arch surgery using bilateral antegrade selective cerebral perfusion in combination with near-infrared spectroscopy. *Eur. J. Cardiothorac. Surg.*, 2010, 38(5).
16. Kazui T. Simple and safe cannulation technique for antegrade selective cerebral perfusion. *Ann. Thorac. Cardiovasc. Surg.*, 2001, 7(3).
17. Chalegre ST, Sá MPBO, Gonçalves De Rueda F, et al. Central versus peripheral arterial cannulation and neurological outcomes after thoracic aortic surgery: meta-analysis and meta-regression of 4459 patients. *Perfusion*, 2015, 30(5):383-388.
18. Luciani N, et al. Harmonic scalpel reduces bleeding and postoperative complications in redo cardiac surgery. *Ann. Thorac. Surg.*, 2005, 80(3):934-938.
19. Yamashita Y, et al. Double arterial vs. single axillary cannulation in acute type A aortic dissections: a meta-analysis. *Future Cardiol.*, 2024, 20(5-6):305-316.
20. Urbanski PP, Lenos A, Bougioukakis P, et al. Mild-to-moderate hypothermia in aortic arch surgery using circulatory arrest: a change of paradigm? *Eur. J. Cardiothorac. Surg.*, 2012, 41(1):185-191.
21. Dong SB, et al. Mild hypothermic circulatory arrest with selective cerebral perfusion in open arch surgery. *J. Thorac. Dis.*, 2021, 13(2):1151-1161.
22. Tasoudis PT, Varvoglis DN, Vitkos E, et al. Unilateral versus bilateral antegrade cerebral perfusion in acute type A aortic dissection repair: A systematic review and meta-analysis. *Perfusion*, 2023, 38(5):931-938.
23. Urbanski PP. Carotid artery cannulation in aortic surgery. *Multimed. Man. Cardiothorac. Surg.*, 2015, mmv026.
24. Misfeld M, Mohr FW, Eitz CD. Best strategy for cerebral protection in arch surgery – antegrade selective cerebral perfusion and adequate hypothermia. *Ann. Cardiothorac. Surg.*, 2013, 2(3):331-338.
25. Todorov IP, Todorova ZP, Nikolov DP. Angioplasty balloon occlusion of LIMA graft in reoperations of patients with prosthetic valve endocarditis and patent LIMA-LAD graft. *Kardiochir. Torakochirurgia Pol.*, 2022, 19(4):199.
26. Verma R, Cohen G, Colbert J, et al. Bicuspid aortic valve associated aortopathy: 2022 guideline update. *Curr. Opin. Cardiol.*, 2023, 38(2):61-67.
27. McPhee A, Shaikhrezai K, Berg G. Is it safe to divide and ligate the left innominate vein in complex cardiothoracic surgeries? *Interact. Cardiovasc. Thorac. Surg.*, 2013, 17(3):560-563.